UNIV. OF
TORONTO
LIBRARY

THE

# Ophthalmic Review

THE

# Ophthalmic Review

*A RECORD OF OPHTHALMIC SCIENCE.*

EDITED BY

WILLIAM GEORGE SYM, M.D.,

EDINBURGH.

WITH THE ASSISTANCE OF

A. FREELAND FERGUS, M.D., Glasgow
A. HILL GRIFFITH, M.D., Manchester
KARL GROSSMANN, M.D., Liverpool
J. B. LAWFORD, M.D., London
W. G. LAWS, M.B., Nottingham
ARTHUR W. SANDFORD, M.D., Cork
PRIESTLEY SMITH, M.B., Birmingham
J. B. STORY, M.B., Dublin
A. HUGH THOMPSON, M.D., London
CHARLES H. USHER, M.B., Aberdeen
LOUIS WERNER, M.D., Dublin
F. W. MACKENZIE, M.B., Wellington, N.Z.
F. P. MAYNARD, M.B., Major I.M.S., India
J. W. STIRLING, M.B., Montreal, Canada
EDWARD JACKSON, M.D., Denver, Colorado, U.S.

VOLUME XXIII.

1904.

422336
17. 4. 44

SHERRATT & HUGHES,
LONDON; 65, LONG ACRE, W.C.
MANCHESTER: 27, ST. ANN STREET.

RE
1
045
v.23

# INDEX.

*Capitals indicate an original article.*


Acanthosis nigricans, eye, symptoms in, 204
Accommodation, Astigmatic, 215
ACCOMMODATION, MECHANISM OF, Grossmann, 1, 347
—— MECHANISM OF, TSCHERNING, 95
—— observations on, Hess, 224
Adrenalin in glaucoma, 298
Alcohol, subconjunctival injection of, 120
Alopecia and eye-strain, 121
Alvarado, contribution to the study of nitrate of silver, 338
AMAUROSIS FOLLOWING EXTRACTION OF TOOTH, 219
Amblyopia caused by methyl alcohol, 148
—— hysterical bilateral, 42
Amenorrhœa and atrophy, 182
Anæsthesia, local, 278
—— —— for excision of lachrymal sac, 54
Anderson, pemphigus of conjunctiva, 58
Anencephaly, retina and optic nerves in, 180
Aneurism, arterio-venous, 61
—— —— of orbit, 58
—— of internal carotid, ocular symptoms of, 335
—— varicose, with neuritis, 180
Aniridia, hereditary, 118
—— traumatic, 112
Anophthalmos, unilateral, 60
Antonelli, optic neuritis in the course of acute infectious diseases, 49
Armaignac, tattooing of cornea, 55
Arterio-sclerosis, 60
—— in the retina, 30
Asthenopia, treatment of, 84
Astigmatic accommodation, 215
Atrophy, hereditary optic, 178
—— optic, after uterine hemorrage, 245
—— —— amenorrhœa, 182
—— —— from lead in a file-cutter, 244
Atropin in Glaucoma, 342

Bach, Pupillenstudium, 71
Bacteriology of the conjunctiva, 305, 381
Bacterium coli, hypopyon ulcer caused by, 175
Ball, cervical sympathetic and the eye, 237
—— modern ophthalmology, 274
Bardelli, filamentous keratitis, 173
Batteo, Buphthalmos with congenital growth, 279
—— changes at macula, 84
—— peculiar deposit on cornea, 244
Baudry, forensic questions involved in injuries to the eye, 170
Beaumont, eye symptoms in rheumatoid arthritis, 85
Bee-sting, iritis following, 215
De Berardinis, hypopyon ulcer caused by bacterium coli, 175
Bernheimer, cerebral connections of ocular movement, 211
BERRY, EFFECT OF ACCIDENTALLY REDUCED VISION UPON ITS EFFICIENCY, 251
—— manual of practical ophthalmology, 275
Bibliography, 61, 88, 122, 152, 183, 216, 248, 280, 312, 344, 382
Bickerton, changes in retina after contusion, 178
—— hereditary optic atrophy, 179
Biographic clinics, vol. ii., 208
Birch-Hirschfeld & Krafft, eye symptoms in acanthosis nigricans, 204
Birth, hæmorrhages in the eye at, 271
Blair, rupture of choroid, 180
Blinking phenomenon, 114
Boldt, trachoma, 22
Bossalino, bacteriology of the conjunctiva, 305
Brewerton, tumour of ciliary body, 244
De Britto, Bilateral meningocele of orbit, 148
Bronner, perioxide of hydrogen in gonorrhœal conjunctivitis, 116
Browne and Stevenson, squint in children, 81
Bruner, toxic amblyopia from methyl alcohol, 148
Bruns, Phlyctenular ophthalmia and tubercle bacilli, 309
Buller, Toxic Amblyopia from methyl alcohol, 148
Buphthalmos with congenital growth, 279
BYERS, TREATMENT OF CHRONIC AFFECTIONS OF THE LACHRYMAL CANAL, 33

Calderaro, hypopyon keratitis treated with sera of Tizzoni-Panichi and of Romer, 78
Calderaro and Cirincione, chloroma, 105
Cantonnet, treatment of glaucoma by osmotic substances, 269
Cataract, cryoscopy and the pathology of, 302
—— posterior polar, 113
—— views as to formation of, 209
Cautery in treatment of wounds and ulcers of cornea, 200
Cerebral connections of ocular movements, 211

Cerebral degeneration with macular changes, 115
Chaillous, Parinaud's infective conjunctivitis, 129
Chandler, modified simple extraction, 121
Chloroma, 105
Choroid, prognosis in malignant tumours of, 172
—— rupture of, 180
—— sarcoma of, 242
—— tubercle of, 177
—— tuberculosis of, 86
—— unusual degeneration of, 29
Choroiditis, anatomical changes in, 294
—— central, in a young man, 83
Ciliary body, syphiloma of, 262
—— body, tumour of, 244
—— region, inflammatory swelling in, 83
Circulation and nutrition of the eye, 188
CHRISTONE, ORIGIN OF THE VITREOUS, 336
—— and Calderaro, Chloroma, 105
Clinical notes, 54, 118, 147, 214, 278
Coats, thrombosis of cerebral vein, 279
Coburn, hæmorrhages in the eye at birth, 271
Collectio ophthalmologica verterum auctorum, 297
Collins, E. T., symmetrical circumferential opacity of cornea, 83
Coloboma of choroid, unusual form of, 152
Congenital anomalies, multiple, 152
Conjunctiva, bacteriology of, 305, 381
—— dermo-lipoma of, 241
—— epithelioma of, 111
—— lymphoma of, 81
—— pemphigus of, 58
—— septic, extraction of cataract in presence of, 55
—— tuberculosis of, 279
Conjunctivitis, gonorrhœal, peroxide of hydrogen for, 116
CONJUNCTIVITIS, PARINAUD'S, STIRLING and McCRAE, 283
Contusion, changes in retina after, 178
—— optic neuritis following, 183
Cornea, cautery in treatment of wounds and ulcers of, 209
—— family spotted degeneration of, 141
—— hereditary nodular opacities of, 59
—— hot water in affections of, 147
—— peculiar deposit on, 244
—— symmetrical circumferential opacity 83
—— traumatic affections of, and herpes, 36
—— trellised opacity of, 141
CORNEA, ULCERATION OF, CAUSED BY BACILLUS PYOCYANEUS, 65
Corneæ, ill-developed, 29
Cryoscopy and the pathology of Cataract, 302
Czermak, subconjunctival extraction, 120

Dawnay, anophthalmos, 60
Dean & Usher, course of optic nerve fibres, 195
Dermo-lipoma of conjunctiva, 241
Diabetes mellitus, eye affections in, 38
Diphtheria, permanent paralysis after, 84
Disc, blood vessels of, in lower animals, 379
—— peculiar changes of and round, 113
Diseases of the eye, textbooks, Berry, 275
—— —— Fox, 206
Diseases of Gibbons, 198
—— —— Haab (external), 198
—— —— Hansell & Sweet, 79
—— —— Juler, 238
—— —— Posey, 48
—— —— Veasey 80
—— —— Wood & Woodruff, 214
Distance and size of objects, judgement of, 32
Donovan, cautery in treatment of wounds and ulcers of cornea, 209
Doyne, Arterio-sclerosis, 60
—— —— in the retina, 30
—— effusion into retina, 60
—— ill-developed corneæ, 29
—— peculiar condition of lachrymal sac after injury, 176

Eason, albuminuric retinitis after three years, 151
—— persistent patent hyaloid artery, 150
Ectropion, operation for, 30
Electric eye-warmers, 379
ELEVATOR-FORCEPS, 223
Ellett, extraction in septic condition of conjunctiva, 55
Elschnig, light reflex on retenal vessels, 110
Embolism of retinal artery, 84
Epithelioma of conjunctiva, 111
Erythropsia and coloured after-images, 234
Ewetzky, syphiloma of ciliary body, 262
EXOPHTHALMOS, PULSATING, 315
—— pulsating, from hydrocephalus, 86
Extra pharmacopœia, 241
Extraction in septic condition of conjunctiva, 55
—— modified simple, 121
—— subconjunctival, 120
Eyelids, plastic operations on, 118
Eye-strain and apoleccia, 121
—— and headache, 301

Fehr, family spotted degeneration of the cornea, 141
FERGUS, OPTIC NEURITIS FOLLOWING SMALL POX, 187
—— STEREOSCOPIC TREATMENT OF SQUINT, 365
—— average visual acuteness, 31
—— operation for ectropion, 30
Filamentons keratitis, 173
Fisher, ophthalmological anatomy, 239
Flemming, arterial disease of retina, 61
Fox, diseases of the eye, 206
Freund, trellised opacity of the cornea, 141
Fromaget, hypodermic injections of gelatine in recurrent vitreous hæmorrhages, 24
Fuchs, anatomical changes in choroiditis, 294

GAD, ELEVATOR-FORCEPS, 223
Gelatine, hypodermic injection of, in recurrent vitreous hæmorrhages, 24
Gelpke, results of operation in myopia, 160
Gibbons, diseases and refraction of the eye, 198
Glaucoma, adrenalin in, 298
—— and detachment of retina, relation between, 20
—— atropin and eserin in, 342
—— pathology and treatment of, 73
—— treatment of, by osmotic substances, 269

Glioma in each eye, 245
— two cases in one family, 245
Gonin, ocular lesions caused by lightning, 201
Gonorrhœal conjunctivitis, peroxide of hydrogen for, 116
Gould, biographic clinics, vol. ii., 208
Gowers, Lectures on diseases of the nervous system, 377
—— medical ophthalmoscopy, 273
Grandclement, adrenalin in glaucoma, 208
Granular Ophthalmia, outbreak of, 153
Greeff, pathological anatomy of the eye, 44
—— radium rays and the eye, 168
Grilli, cryoscopy and the pathology of cataract, 302
Grimsdale, errors of refraction, 207
—— light reflex of pupil associated with movement of other eye, 150
Grossmann, mechanism of accommodation, 1, 347
Gruening, operation for ptosis, 57
Gunn, R. M., maldevelopment of suspensory ligament, 152
—— vascular changes in retina, 58
Gunshot injury, indirect, 32
Guttman, local anæsthesia, 278

Haab & de Schweinitz, atlas of external diseases, 198
Hæmorrhage uterine, atrophy after, 245
Hæmorrhages in the eye at birth, 271
Hanke, malformation of the globe, 76
Hansell & Sweet, text-book of diseases of the eye, 79
Harman, an ophthalmoscope, 378
—— blinking phenomenon, 114
—— judgement of size and distance of objects, 32
—— multiple congenital anomalies, 152
—— paresis of certain muscles with over-action of others, 176
Hartridge, posterior polar cataract, 113
Heine, congenital cystic retina, 270
—— myopia, 145
Henderson, E., anterior staphyloma, 243
—— flat sarcoma of choroid, 242
—— pseudo-glioma, 243
—— F. L., lessons on the eye, 80
—— G. E., subconjunctival dislocation of lens, 29
—— and Starling, intraocular pressure and circulation, 290
Herbert, trachomatous pannus, 181
Herpes corneæ and traumatic affections, 46
Hess, observations on accommodation, 224
Hilbert, Iritis following bee-sting, 215
Hillemanns, relation between glaucoma and detachment of retina, 26
Hirschberg, idiocy and defective vision, 122
—— prognosis in malignant tumours of choroid, 172
Holth, skiakinescopy, 293
Hosch, subconjunctival injections, 214
Hot water in corneal affections, 147
Hyaloid artery, persistent patent, 150
Hypopyon keratitis treated with serum, 78
—— ulcer and pneumococcus serum, 311
Hysteria, ocular traumatic, 339
Hysterical amblyopia, bilateral, 42

Idiocy and defective vision, 122
Imre, sublamin, 119
Infectious diseases, optic neuritis in 49
Injuries to the eye, forensic questions involved in, 170
Intraocular pressure and circulation, 290
Iritis following bee-sting, 215

James, treatment of asthenopia, 84
Jessop, epibulbar tumour, 116
—— proptosis with disease of sphenoid, 87
—— sarcoma of limbus, 30
Juler, ophthalmic science and practice, 238

Lachrymal canal, treatment of chronic affections of, 33
—— glands, changes in, after removal of the sac, 337
—— sac, local anæsthesia for excision of, 54
—— —— peculiar condition of, after injury, 176
Lachrymation, congenital absence of, 54
Lagrange, tumours of the eye and orbit, 297
De Lapersonne, operation for ptosis, 56
—— stovain, 267
Lawford, myasthenia gravis, 177
Lawson, traumatic aniridia, 112
Lead, optic atrophy from, in a file-cutter, 244
Leber, circulation and nutrition of the eye, 188
Lens, nutrition of, and formation of cataract, 209
—— subconjunctival dislocation of, 29
Lenses, congenital dislocation of, in five generations, 151
—— —— malformation of, 180
Lessons on the eye, Henderson, 80
Lightning, ocular lesions caused by, 201
Light-reflex on retinal vessels, 110
Limbus, sarcoma of, 30
Loeser, ocular symptoms of aneurism of internal carotid, 335
London, action of radium in relation to vision, 165
Lunn, compression of veins of retina by thickened arteries, 149
—— tuberculosis of choroid, 86
Lymphflow through the eyeball, 197
Lymphoma of the conjunctiva, 81

McNab, ulceration of cornea due to infection with bacillus pyocyaneus, 65
McCrae and Stirling, Parinaud's conjunctivitis, 283
Macula, changes at, following subhyaloid hæmorrhage, 84
—— colour of, 119
—— changes with cerebral degeneration, 115
—— region, changes in, 84
Maddox, electric eye warmers, 379
—— pigmy needles for suture of conjunctival flap, 379
Malformations of the globe, 76
Manolesco, hot water in corneal affections, 147
Manual of practical ophthalmology, Berry, 275
Martindale and Wescott, extra pharmacopœia, 241
Maurizi, Mirmol, 215

MAYNARD, SARCOMA OF ORBIT, KRONLEIN'S OPERATION, 156
—— and Rogers, pulsating exophthalmos from hydrocephalus, 86
Mayou, cerebral degeneration with macular changes, 115
—— differential staining for ganglion cells, 179
—— microphthalmos, 246
—— retina and optic nerves in anencephaly, 180
Medical ophthalmoscopy, Gowers, 273
Meningocele of both orbits, 148
Merck's report for 1903, 336
Metastatic ophthalmia caused by Talamon-Fraenkel diplococcus, 121
Methyl alcohol, amblyopia from, 148
Microphthalmos, 246
Mirmol, 215
Moissonnier, hereditary aniridia, 118
Movement, congenital defect of, 82
Movements of the eye, voluntary dissociation of, 75
Mowat, permanent paralysis of inferior recti after diphtheria, 84
MUCOCELE OPERATED UPON BY KRONLEIN'S METHOD, 155
Myasthenia gravis, 177, 178
Myopia, clinical and therapeutic memoranda regarding, 145
—— results of operations in, 160

Natanson, changes in lachrymal glands after extirpation of the sac, 337
Needles, pigmy, for suture of conjunctival flap, 359
Nerve fibres, course of optic, 195
Nervous system, lectures on diseases of, Gowers, 377
Nettleship, blood-vessels of disc in lower animals, 379
—— indirect gunshot injury, 32
Neuritis, optic, following contusion, 183
NEURITIS, OPTIC, FOLLOWING SMALL-POX, 187
—— —— in the course of acute infectious diseases, 49
Night-blindness and coughing, 117
—— and xerosis, 235

Ocular complications of nephritis, decapsulation of kidney, 199
—— therapeutics, Scrini, 278
Ogilvy & Stephenson, epithelioma of conjunctiva, 111
Ophthalmic science and practice, Juler, 238
Ophthalmological anatomy, Fisher
Ophthalmological Society, 29, 58, 81, 111, 149, 176, 241, 279, 378
Ophthalmology, manual of practical, Berry, 275
—— modern, Ball, 274
Ophthalmoplegia externa, 243
Ophthalmoscope, a new, 378
Oppenheimer, spectacles, in theory and practice, 277
Orbit, arterio-venous aneurism of, 58
—— SARCOMA OF, KRONLEIN'S OPERATION, 156
Orth and Greeff, text book of pathological anatomy, 44

Pannus, trachomatous, 181
Pansier, collectio ophthalmologica veterum auctorum, 297
Paralysis of inferior recti after diphtheria, 84
—— OF THIRD NERVE, RECURRENT, 125
Paresis of certain muscles with over-action of others, 176
Parinaud, operation for ptosis, 295
PARINAUD'S CONJUNCTIVITIS, STIRLING AND MCCRAE, 283
—— —— 129
Parisotti, pathological histology of eye, 265
Parsons, congenital anterior staphyloma, 116
—— pathology of the eye, 276
—— sections of tubercle of choroid, 177
Paterson, lymph flow through the eyeball, 197
Pathological anatomy of the eye, 44
—— histology of the eye, Parisotti, 265
Pathology of the eye, Parsons, 276
Paton, congenital malformation of lenses, 180
Pemphigus of conjunctiva, 58
Peroxide of hydrogen in gonorrhœal conjunctivitis 116
Peschel, subconjunctival injections of alcohol, 120
Peters, traumatic affections of the cornea and herpes, 46
Pfister, nutrition of lens and formation of cataract, 209
Phlyctenular ophthalmia and tubercle bacilli, 309
Pino, erythropsia and coloured after-images, 234
Pneumococcus serum and hypopyon ulcer, 311
Pollock, bacteriology of conjunctiva, 381
Pooley, thrombosis of retinal vein, 29
Posey, diseases of the eye, 48
Pritchard, arterio-venous aneurism, 61
Proptosis with disease of sphenoid, 87
Pseudo-glioma, 243
Ptosis, operations for, 56
—— Parinaud's operation for, 296
Pupil, light reflex of, associated with movement of other eye, 150
Pupillary membrane with anterior synechiæ, 53
Pupillenstudium, 71

Radium in relation to vision, 165, 168
Refraction and motility of the eye, Suter, 80
—— errors of, Grimsdale, 207
Retina and optic nerves in anencephaly, 180
—— arterial disease of, 61
—— arterio-sclerosis in, 30
—— changes in after contusion, 178
—— congenital cystic, 270
—— detachment of, and glaucoma, relation between, 26
—— effusion into, 60
—— vascular changes in, 58
Retinitis, albuminuric after three years, 151
Rheumatoid arthritis, eye symptoms in, 85
Ridley, aneurism of orbit, 58
Rockcliffe, optic atrophy and amenorrhœa, 182
—— optic neuritis following contusion, 183
—— outbreak of granular ophthalmia, 183

Rogers, Maynard and, pulsating exophthalmos from internal hydrocephalus, 86
Roll, changes in macular region, 84
—— choroidal degeneration, unusual, 29
—— embolism of retinal artery, 84
—— ophthalmoplegia externa, 243
Rollet, plastic operations on eyelids, 118
Romer serum in hypopyon keratitis, 78
Ruge, relations of sympathetic ophthalmia to other forms of uveitis, 226

Sarcoma, epibulbar melanotic, 242
—— of choroid, flat, 242
—— of limbus, 36
Schieck, vernal catarrh, 259
Schiele, night-blindness and xerosis, 235
Schmidt-Rimpler, colour of macular 119,
De Schweinitz, cervical sympathetic and the eye, 237
—— & Haab, atlas of external diseases, 198
Sclerosis, multiple, ocular symptoms of, 138
Serini, handbook of ocular therapeutics, 278
Searles, atropin and eserine in glaucoma, 342
Silcock, varicose aneurism with neuritis, 180
Silver, nitrate of, its effects, 338
Size and distance of objects, judgement of, 32
Skiakinescopy, 293
SMALLPOX, OPTIC NEURITIS FOLLOWING, 187
Smith, H., night-blindness and leos couching, 117
Smyth, tubercle of conjunctiva, 279
Snell, eye strain and headache, 301
—— glioma in each eye, 245
—— —— two cases in one family, 245
—— optic atrophy after uterine hæmorrhage, 245
—— —— —— from lead in a file-cutter, 244
Sommer, congenital absence of lachrymation, 54
Sourdille, operation for ptosis, 57
Spectacles, in theory and practice, 277
Sphenoid, disease of, with proptosis, 87
Spicer, hereditary nodular opacities of cornea, 59
Spring catarrh, 259
SQUINT, STEREOSCOPIC TREATMENT OF, PERGUS, 365
Staining, differential, for ganglion cells, 179
Staphyloma, anterior, 243
—— congenital anterior, 116
Starling and Henderson, intraocular pressure and circulation, 290
Stephenson and Ogilvy, epithelioma of conjunctiva, 111
Stevenson and Browne, squint in children, 81
STIRLING, AMAUROSIS FOLLOWING EXTRACTION OF A TOOTH, 219
—— AND McCRAE, PARINAUD'S CONJUNCTIVITIS, 283
Stock, local anaesthesia for excision of lachrymal sac, 54
Stockholm, report of eye clinique at, 336
Stovain, 267
Subconjunctival injections, 214
Sublamin, 119
Suker, decapsulation of kidney in nephritis with ocular complications, 199
Suspensory ligament, maldevelopment of 152
Suter, refraction and motility of the eye, 80
SWANZY, MUCOCELE OPERATED UPON BY KRÖNLEIN'S METHOD, 155
Sweet, Hansell and, diseases of the eye, 79
Sympathetic, cervical, and the eye, 237
—— ophthalmia and its relation to other forms of uveitis, 226
Syphiloma of ciliary body, 262

Talamon-Fraenkel diplococcus causing metastatic ophthalmia, 121
Tattooing of cornea, 55
Taylor, James, myasthenia gravis, 178
—— S. J., swelling in ciliary region, 83
Teillais, ocular traumatic hysteria, 330
Test types, new, 147
Therapeutics, hand-book of ocular, 278
Thompson, A. H., unusual form of coloboma of choroid, 152
—— G. W., central choroiditis in a young man, 83
—— —— congenital kerato-iritis, 113
—— —— peculiar changes round disc, 113
Thrombosis of cerebral vessels, 279
—— of retinal vein, 29
Tizzoni serum in hypopyon keratitis, 78
TOOTH, AMAUROSIS FOLLOWING EXTRACTION OF, 219
Trachoma, Boldt, 22
TSCHERNING, MECHANISM OF ACCOMMODATION, 95
Tubercle bacilli and phlyctenular ophthalmia, 309
Tuberculosis of choroid, 86
—— of conjunctiva, 279
Tumour, epibulbar, 116
Tumours of the eye and orbit, Lagrange, 297

USHER, PULSATING EXOPHTHALMOS, 315
Usher and Dean, cause of optic nerve fibres, 195
Uveitis, its relations to sympathetic ophthalmia, 226

Veasey, diseases of the eye, 80
Veins of retina, compression of, by thickened arteries, 149
Vernal catarrh, 259
Vetter, bilateral hysterical amblyopia, 42
Vision, average acuteness of, 31
—— EFFECT OF ACCIDENTAL REDUCTION OF UPON EFFICIENCY, 251
VITREOUS, ORIGIN OF THE, 330, 370
Vitreous, recurrent hæmorrhages into, gelatine in treatment of, 24

Weeks, cervical sympathetic and the eye, 237
Weinhold, voluntary dissociation of movements of the eye, 75
Werner, congenital defect of movement, 82
—— dermo-lipoma of conjunctiva, 241
Werner, epi-bulbar melanotic sarcoma, 242
—— lymphoma of the conjunctiva, 81
WERNER, RECURRENT PARALYSIS OF THIRD NERVE, 125
Wernicke, congenital word-blindness, 19
Whitfield, alopecia and eye-strain, 121

Widmark, report of eye clinique at Stockholm, 336
Wilder, cervical sympathetic and the eye, 237
Wintersteiner, pupillary membrane with anterior synechiæ, 53
Wood & Woodruff, commoner diseases of the eye, 214
Word-blindness, congenital, 19
Worth, congenital dislocation of the lenses in five generations, 151
Woodruff & Wood, commoner diseases of the eye, 214

Xerosis and night blindness, 235

Zeller, treatment of hypopyon ulcer with pneumococcus serum, 311
Zimmermann, pathology of glaucoma, 73

SHERRATT & HUGHES, Printers,
65, Long Acre, London, W.C.

# THE MECHANISM OF ACCOMMODATION IN MAN.*

Read in the Section of Ophthalmology at the Annual Meeting of the British Medical Association, Swansea, July, 1903.

By Karl Grossmann, M.D., F.R.C.S.E.,
*Ophthalmic Surgeon to the Stanley Hospital, Liverpool.*

The question as to the mechanism of accommodation received its scientific answer some fifty years ago, and in such a manner that it seemed to have been settled finally. The changes during accommodation of the size of the reflex images formed by the anterior surface of the lens were first observed in 1849 by Max Langenbeck,[1] and soon discovered again and carefully investigated in 1851 and 1852 by Cramer, and published by him in 1853.[2] In the following year, 1854, Helmholtz, who had been unacquainted with Cramer's Dutch publication, the German translation of which appeared in 1855, published the result of his researches in Graefe's *Archives of Ophthalmology*, which had just commenced its career a few months previously. According to his theory the accommodation was mainly, if not solely, due to an increase in the spherical curvature of the anterior surface of the lens. This increase was due to the relaxation of the zonula, and the latter was produced by the contraction of the ciliary muscle, or, as it was then called, "tensor choroideae."

This view was generally accepted, until in 1858 Mannhardt,[3] by a study of the comparative anatomy of the ciliary muscle, came to the conclusion that the accommodation by increased curvature of the anterior surface of the lens was produced by the traction (and contraction) of the ciliary muscle. This view was little accepted, and was seriously supported only by Schoen,[4]

* These investigations are being continued, and the results will be made known in due course.

who ever since has adhered to it. He found a very valiant supporter in Tscherning, who in the *Archives de Physiologie* of 1894 and 1895 adopted Schoen's views. Tscherning corroborated what Cramer, and—fifty years before him—Thomas Young had observed, that the anterior surface of the lens does not retain during accommodation its spherical shape, but changes into a hyperboloid, the centre becoming more curved and the periphery more flattened than before. These changes are attributed by him to the increased tension of the zonula as the result of the contraction of the ciliary muscle. With regard to the alteration of the anterior surface of the lens he says[5]: "My investigations show that the essential phenomenon in the accommodation of the eye consists in the flattening of the peripheral portion of the anterior lens surface; it is this flattening which indirectly produces the increase of curvature in the central portion, and thereby as its result the increase of refraction. This flattening thus became a phenomenon of the first importance for the study of the mechanism of the eye, it becomes desirable to study it as closely as possible, the more so as in my opinion it is the weightiest argument against the acceptance of the theory of Helmholtz."

The two theories are then briefly these:—

(*a*) The increased curvature of the lens during accommodation is produced by *relaxation* of the zonula due to contraction of the ciliary muscle.

(*b*) The increased curvature of the lens during accommodation is produced by *tension* of the zonula due to contraction of the ciliary muscle.

The former view (*a*) is called the Helmholtz theory, the latter view (*b*), though identical with Mannhardt's and Schoen's, we will call for our purposes the Tscherning theory.

A formidable attack was made in 1896 by C. Hess, who, in an able paper,[6] brought at one blow the weight of important new observations to bear against Tscherning's

view. Since then the discussions at the International Ophthalmological Congress at Utrecht, 1899, and at the International Medical Congress at Paris, 1900, have left the balance in favour of the Helmholtz view, in spite of the heated attempts of Schoen, Tscherning, and others to get the victory on their side. I had not taken a very ardent interest in the controversy when I was induced nearly a year ago to approach the subject. I can only say I have entered the discussion in a perfectly unbiassed spirit. My object has been to ascertain facts—undoubted, unassailable facts—and to bring new evidence. Having obtained this, the facts would have to be placed and interpreted, irrespective of any preconceived idea or theory. It was perfectly indifferent to me which way the result would turn. The objective facts would have to be accounted for.

In the autumn of last year a young man came to me to consult me about his eyes. Twenty-six years of age, of middle stature, well-formed, except for a scar on the right upper lip (due to an accident), healthy in appearance. A casual glance shows rather dark eyes of otherwise normal size, on closer inspection the iris cannot be seen. No photophobia, no unusual expression or behaviour in daylight. Examination in the dark-room reveals: Corneae normal in size and transparency; iris both in right and left eye completely absent. Right eye: Lens of normal transparency except for a very small anterior and still smaller posterior polar cataract. Left eye the same as right; however, both anterior and posterior cataracts are still smaller than the corresponding opacities in the right eye. These four opacities are very shallow and are situated within and in contact with the capsule. In the fundus of the right eye, near the equator, there is a slightly yellow, discoloured, longish patch noticeable in the retina, otherwise the fundus shows no abnormalities. Refraction: Hypermetropia and vertical corneal astigmatism of 2D.; V.R. $=\frac{1}{6}$ with $+6{\cdot}0\bigcirc+2{\cdot}0\phi$ V.L. $=\frac{1}{6}$ with $+7{\cdot}0\bigcirc 2{\cdot}0\phi$. For near distance he sees Jaeger 5 with difficulty; he is not a good scholar. Both the focal and the ophthalmoscopic illuminations are borne as easily and as well as daylight; no sign of photophobia. On looking into the fundus in the direction of the visual axis the lens practically fills the corneal area; when looking in an oblique direction the free margin of the lens becomes easily visible. Following it all round it is found that the equatorial

margin of the lens is quite free from contact with any portion of the ciliary body, of which, in fact, no trace can be detected.

In case the patient should not present himself for any later careful examination he was shown at the Liverpool Medical Institution on November 6th, 1902. The only point raised on that occasion was that in the few known cases of congenital aniridia glaucoma was almost always present. This was not so in this case, and I mentioned that if there should be a sufficient amount of accommodation at all—not necessarily so in congenital aniridia—an investigation of the mechanism of accommodation should be made.

And the accommodation *was* present. Here was given the most exceptional concurrence of favourable conditions:

(*a*) Normal size of cornea, lens, and eyeball.

(*b*) Transparency of cornea, aqueous, vitreous.

(*c*) Transparency of lens, except for a very fine mark—a regular "chalk mark"—of the anterior and posterior pole.

(*d*) A sufficiently good visual acuity.

(*e*) Absence of photophobia.

When asked to look at an object held within 6in. from the eye the existence of accommodation seemed to be very doubtful at first. Though the ophthalmoscope seemed to show an increase of about 1 to 2 dioptries no trace of any ciliary processes could be detected anywhere. The zonula fibres were noticeable all round although only faintly.

Eserine was then instilled, and soon the picture changed.

1. When examined with the plane mirror, the lens, hitherto quite homogeneously red, appeared divided into three concentric zones. The central part ($4\frac{1}{2}$mm. in diameter) shows, except for the point-shaped polar opacity, the clear red of the fundus. Round this an incomplete ring (2mm. broad) of a horseshoe-shaped shadow shifts round with the movements of the mirror, and can thereby be completed into a ring-shaped shadow zone. This in its turn is again surrounded by a clear zone of about 1mm., reaching to the extreme edge of the lens (Fig. 1). The

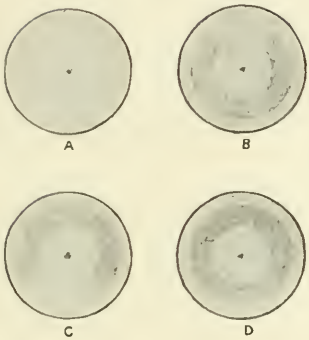


FIG. 1.—Shadow test with plane mirror; the dark spot in the centre represents the anterior polar cataract. A, without eserine; B, C, D, with eserine.

ring-shaped shadow zone is the expression of a difference of refraction that has taken place between the central and the more peripheral portion of the lens; it is the indication that the surface of the lens has changed its spherical form into that of a lenticonus (an anterior one, at any rate), such as has been observed by Cramer and proved by Tscherning.

2. The second, and perhaps most striking, feature is, however, the tremor of the lens. This does not occur at once, but only after five to ten minutes have elapsed after the first instillation of eserine. When any jerky movements of the eyes are made, vertical or lateral, the lens shows a most marked tremor of about two or even four small but distinct vibrations. This can be seen to perfection as well by reflected as by transmitted light, thanks to the polar chalk marks on the lenses. When not under the influence of eserine not a trace of this tremor can be seen,

not even during the highest exertion of voluntary accommodation.

This practically agrees with the observations made by Hess.[7]

[The tremor of the lens proves, as has been pointed out by Hess, that the pressure in front and behind the lens must be the same during the height of accommodation, otherwise tension of the zonula would take place, and the lens could not vibrate loosely in its suspension as it does. With regard to this point more accurate knowledge is required than we at present possess, and the results of the investigations in this direction will be published in due course.

In the first volume of the large handbook of Graefe-Saemisch, Merkel (*Makroscopische Anatomie des Auges*, i., p. 38), in speaking of the lens, says: "The vitreous adheres so closely to the posterior surface of the lens that in quite fresh eyes a separation is impossible there, so that it first requires maceration before lens and vitreous can be separated." Tscherning (*Compt. Rend. Cong. Intern. d'Ophtol. d'Utrecht*, Amsterdam, 1900, p. 252) says: "Mr. Hess, who supports the Helmholtz theory, supposes that the lens sinks downward in consequence of the slackening of the zonula. But not only does the Helmholtz theory seem to me to have to be given up for other reasons, but it also appears difficult to imagine that the lens could sink at all, considering the manner in which it is fixed on the vitreous, unless the anterior part of the vitreous takes part in the movement."

Now, Merkel and Tscherning must clearly be wrong. It does not appear impossible to me that the pressure of the vitreous is not borne by the zonula. What part the hyaloid plays in this respect has never been investigated, but we know that when the lens with its capsule undamaged is removed from its normal position, either luxated or extracted, the vitreous does often remain in its normal place. Only to-day have we seen Major Smith's dazzling array of some thousands of lenses in the intact capsule extracted in India, and I am sure that even if he did not say so, we should not believe that Major Smith would have extracted all these lenses within the capsule if a prolapse of vitreous had been forthcoming in many of them. Our knowledge in this direction very urgently requires improvement.]

3. The ciliary processes become visible. Not very much, but distinctly visible all round the circumference, and it is almost easier to see them under focal illumination, where they stand out from the aphakic (extralenticular) portion

of the red fundus, than with the help of the ophthalmoscope (Fig. 2). As far as can be ascertained, they have made a centripetal movement towards the visual axis, and do not appear to have moved forward towards the cornea. There remains a distinct interval between the ciliary processes and the lens everywhere.

4. The circumference of the lens at its equator remains perfectly circular but decreases considerably.

I have taken a large number of measurements of the equatorial diameter of the lenses with a little apparatus which I constructed for the purpose. A microscopically accurate measurement is impossible, but here we fortunately have to deal with such comparatively speaking large measurements that we need not mind errors of $\frac{1}{4}$ to $\frac{1}{3}$mm.

These are the average measurements equal for both eyes: The equatorial diameter without any drug, $11\frac{1}{2}$mm.; with homatropine, $12\frac{1}{4}$mm.; with eserine, $10\frac{1}{4}$mm.

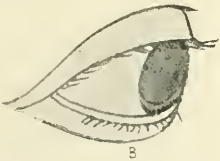


FIG. 2.—A, without eserine, no ciliary processes; B, with eserine, ciliary processes. The two black spots represent anterior and posterior polar cataract respectively.

Here, then, we have a difference, a decrease of the equatorial diameter of 2mm. between the homatropine and the eserine effects. [It must be borne in mind that we have to deal with a high degree of hypermetropia. The homatropine was a 1 per cent. solution, given only very sparingly, as the patient did not like these applications of eserine or homatropine at all. It is therefore quite possible that under the effect of a fairly strong solution of atropine a still greater difference might have been found. But as all these measurements took a great deal of time for their careful carrying out, and had to be often repeated for verification, I had to be satisfied without going to extremes, especially as all the results were unmistakably clear and unequivocal.]

[The equatorial diameter of the lens decreases during accommodation. In Fig. 8 Tscherning (*Annales de la Policlinique de Paris*, July, 1895, and also in *Optique Physiologique*, 1898, p. 164) represents the lens in rest and in accommodation. It is seen there that the equatorial diameter is larger in accommodation than in rest, as it would have to be according to his theory. We have seen that both his facts and theory are wrong. In 1867 A. Coccius published a paper in Leipzig on the mechanism of accommodation of the human eye, in which he mentions that during accommodation he observed in iridectomized eyes an apparent diminution of the diameter of the lens. Tscherning, on page 171 of his *Optique Physiologique*, remarks in reference to these observations: "Les phénomènes observés par Coccius sont probablement dus à une illusion d'optique." My own observations have vindicated the correctness of those of Coccius, and *vice versa*.]

This decrease of the equatorial diameter of the lens during accommodation, as observed and measured here for the first time, is a fundamental fact of the first importance. Quite alone, by itself, without any other corroborating facts, it suffices to demolish the theory of Mannhardt, Schoen, and Tscherning, that the ciliary muscle, by its contraction during accommodation, exerts a pulling, stretching effect on the equator of the lens (through increased tension of the zonula).

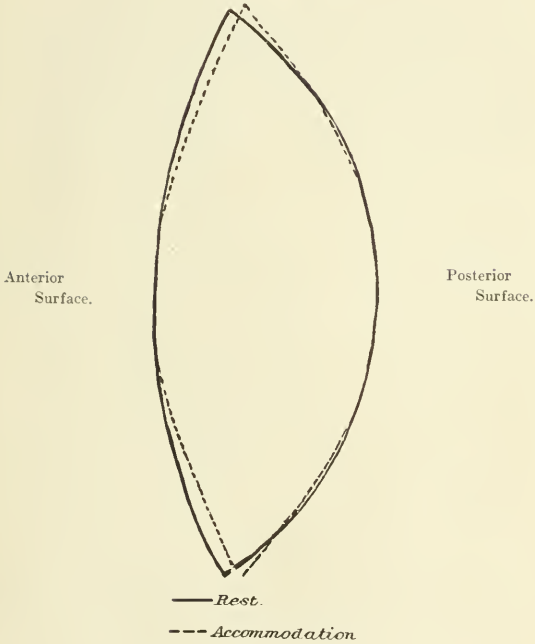


Fig. 8.

5. If the circumference of the lens at the equator decreased, it was to be presumed that its thickness—the antero-posterior diameter—should increase accordingly, the lens being composed of a practically incompressible material.

Direct measurements, hitherto impossible, were carried out in this instance. They were not easy and required a

great deal of patience and time, but they gave clear and decisive results. Fig. 3 explains the method adopted by showing a meridional section of the eye. A represents the anterior, P the posterior pole of the lens, C the apex of the cornea. It should be remembered that in A and in P were the welcome point-shaped cataract spots which could be

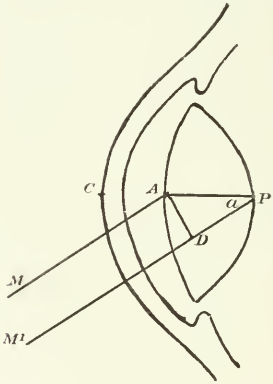


Fig. 3.

used as marks of the anterior and posterior capsule. A microscope of low power was focussed, first on to A and then to P, while the eye and the stand of the microscope were kept in the same relative position. The mark at A being larger than at P, the measurement could not be taken in the direction A P, as A would have covered P, obstructing the view of P altogether. A direction was therefore chosen, oblique enough to avoid the obstruction of P by A. The microscope M was first focussed on A in the direction of M A, and then on P in the direction of M P, which was in reality the identical direction without any lateral displacement of the microscope, A and P being in

the same field of the microscope. The difference between the two focussing distances gave D P; and this gave $A P = \frac{D P}{\cos a}$, $a$ being the angle A P D, which was measured for each experiment especially. Owing to the patient's disinclination for atropine and homatropine, the measurements were taken only for the state of the lens (*a*) without any drug, and (*b*) with eserine. The average of all these measurements, which showed only very slight differences, gave the result that the thickness of the lens, its antero-posterior diameter was for distance without any mydriatic 3·14mm., with eserine 4·44mm., showing a difference of 1·3mm. If we consider that the eye examined was highly hypermetropic and that of a youthful individual, we may safely assume that the difference would have been still greater if atropine had been employed; but even without any mydriatic we have here established for the first time, and proved irrefutably that the thickness of the lens increases during accommodation.*

[With regard to the increased thickening, Helmholtz, in the second edition of the *Physiologische Optik*, p. 134, says: "According to our observations, the anterior surface of the lens advances, while the posterior surface remains in its place; the lens must, therefore, increase in thickness during accommodation. And as it cannot alter its volume we are driven to the conclusion that the diameters of its equatorial plane decrease." This conclusion—though not *a priori* cogent—I have been able to prove to be correct.]

6. After having found that the thickness of the lens increases so considerably during accommodation, it became desirable to examine the relative position of lens and cornea in rest and in accommodation. This was done in a manner similar to the preceding measurements described under No. 5. The distance between C and A was measured by the same microscope; C was marked by small specks of

* The distances of A and P from C are taken here as they actually appear owing to refraction. In reality they are greater.

dust, and of A the first focusable plane was taken. In this instance, however, the direction C A could be adhered to, and no angular measurements were needed. It was found that the distance from the anterior surface of the cornea to the anterior pole of the lens was in rest, 3mm.; with eserine 2½mm. The distance between lens and cornea decreases, therefore, during accommodation.

In spite of this advance of the anterior surface of the lens the lens itself does not move forward. The advance of the anterior surface is 0·5mm.; the thickness increases 1·3mm.; the posterior surface therefore recedes 0·8mm., so that the lens itself remains in its position or more probably moves slightly backwards. It certainly does not move forward.

[Already in 1841 Hueck (*Die Bewegung der Krystallinse*, Leipzig) had observed that during accommodation the anterior surface of the lens advances a little.]

7. We have seen under No. 3 that under the effect of eserine the lens becomes tremulous. This striking feature was first observed and correctly interpreted by Hess[8] as the expression of the slackening of the zonula. Hess found that at the height of accommodation (in some instances without, but more generally with eserine) the lens suddenly descends a little, and when the accommodation is relaxed, it rises equally suddenly back into its original position. This movement is a downward one, due to the effect of gravity; the lens sinks by its own weight. In order to prove this, Hess put his head on the right side, when the right lens descended towards the right temple; on the left side, when the right lens descended towards the nose; forehead downwards, when the lens went towards the forehead, always moving towards the lowest point. When the face was placed horizontally either downwards or upwards the lens did not move at all. Tscherning[9] gives two very good illustrations but no explanation, and appears loth to accept the irrefutable conclusions of Hess.




FIG. 4.—A, without eserine; B, with eserine.

In view of these opinions it was particularly interesting to see how the lenses of our patient behaved. As has been already stated under No. 3, the tremor at the height of the action of eserine was very striking. But on further in-investigation something else became more striking still, and that was a displacement of the lens upwards and inwards. Whereas the ophthalmoscope before the application of eserine gave the appearance (Fig. 4*a*) (right eye), the application of eserine changed the picture to Fig. 4*b*. In the left eye an analogous symmetrical movement counteracts and exceeds the slight downward movement of the lens that takes place due to its own gravity in the erect position, where it would have to be subtracted, while it would have to be added if the head were held downwards. Remarkable as this upward and inward movement of the lens is, it is not surprising that it has never been observed before. It is the result of the asymmetry of the eye, and one of the proofs—if such were needed—that in the present instance we have to deal with a perfectly normal accommodation, where only one part of the apparatus, though not for the optical result, is missing—namely, the iris.

Since first making this observation I have examined thousands of irides, and found in the overwhelming majority of cases that the pupil during contraction moves noticeably inwards and upwards, less frequently inwards and downwards or simply inwards. This at the same time explains why Hess and his friends found, in the entoptic

examination of their individual "lens spectra," that only a downward movement of the lens took place; the pupil and the pupillary margin to which the entoptic movement was correlated had already made a movement in the same direction, and practically together with the lens itself, a movement which therefore became unrecognizable for subjective entoptic observations. From the movement of the lenses in our case we may say with absolute certainty that, had the irides been present and of normal size and function, the pupils would also have moved upwards and inwards.

This point is of such interest and involves such important questions connected with the asymmetry of the dioptric apparatus that it will be gone into more carefully in a special paper.

8. The changes of the curvature of the surfaces of the lens have been examined by means of the Sanson-Purkinje reflex images. Helmholtz and his school used two points as source of light. Tscherning, by using three points arranged in a straight line, was thereby enabled to demonstrate that in accommodation the anterior lens surface increases in curvature in the centre and decreases in curvature towards the periphery. Fig. 5 is a reproduction of Tscherning's Fig. 4 from his article on the Theory of the Optical Changes in the Eye during Accommodation, in *Archives de Physiologie*, January, 1895. The limits of examining these images were very narrow owing to the fact that with increasing accommodation the size of the pupil narrows, and the iris accordingly covers more and more the peripheral area of the lens available for the reflex images. For the same reason it has never hitherto been possible to examine the curvature of the posterior surface of the lens in the living eye, except with a more or less dilated pupil, never with a narrow pupil, and during accommodation only for small degrees of accommodation and in its central area exclusively. Examinations were

therefore instituted to investigate the behaviour of both anterior and posterior lens surface of our case under eserine. With regard to the anterior surface, it was found that images obtained were not sufficiently useful for our purpose. The cause of this led to investigations, the results of which are interesting enough to be given in a special paper.




FIG. 5.—After Tscherning. A, rest; B, C, D, increasing accommodation and concomitantly decreasing pupil.

[The anterior surface of the lens is in the majority of cases not spherical even during rest. This becomes more apparent in advancing age. Most of the lenses extracted in their capsule and shown by Major H Smith to-day have an anterior surface more hyperbolic than spherical, and the same holds good for the posterior surface.]

The posterior surface of the lens, however, gave results as clear as they were unexpected (Fig. 6). The source of light was an uncovered arc light, doubled by two prisms. So little was there any trace of photophobia that the strong light was borne without difficulty for a long series of examinations. It was found that in rest the posterior surface of the lens was practically spherical, the two images

(the smaller ones in Fig. 6*a*) being of the same size in all accessible parts of the posterior surface. Fig. 5*a* represents them formed in the centre, near the posterior pole. After eserine had been applied the images formed in the same place showed a distinct approach to each other; the distance between them had decreased (Fig. 5*b*). This gives an unmistakable proof for the increased curvature of the central portion of the posterior surface of the lens.

This increased curvature of the posterior surface of the lens had already been observed by Helmholtz, but then it appeared very small; so small, indeed, that he did not attribute very much importance to it, although he quite decidedly comments on it as early as the first edition of the *Physiologische Optik* of 1867. When, however, the images are formed from more peripheral portions of the

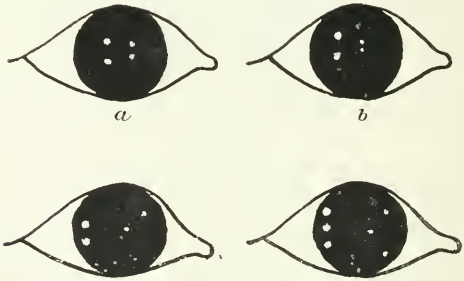


8 *Corneal images*
8 *Posterior lens images*

FIG. 6.—A, without eserine (rest, distance); B, with eserine, images near posterior pole; C, with eserine, images nearer equator; D, images nearer equator (3 images, eserine).

posterior lens surface, by suitably turning the eye, the distance between them increases considerably, to a greater

extent the more peripherally the image is formed. Nor is this all. If we arrange the lights so that they are vertical above each other, and that the reflection of the one is formed on a line that horizontally halves the lens, the other image is formed either below or above this line, and at the same time considerably displaced laterally (further from the centre, nearer to the equator of the lens).

If the eye is turned in such a manner that the one image is formed as far above as the other below the horizontal meridian of the eye, then there is no lateral displacement between the two; they are both on the same vertical line. The lateral displacement is shown for the upper half of the posterior lens surface in Fig. 6*c*. If we construe it for three images, we obtain Fig. 6*d*, similar to Fig. 5*d* of

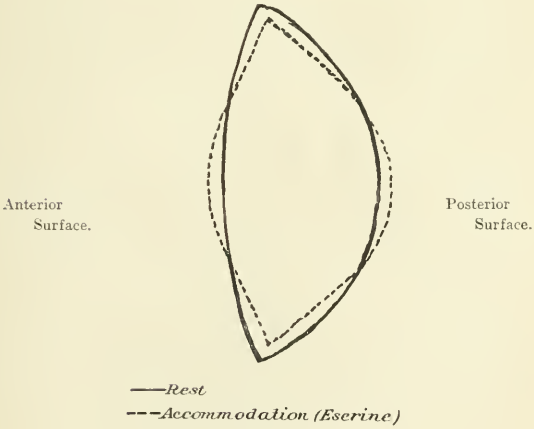


Fig. 7.

Tscherning. The conclusion derived from this observation is that the posterior surface of the lens changes during accommodation in exactly the same manner as the anterior surface, and forms a posterior lenticonus, with increased curvature of the centre and flattening of the peripheral portion.

That the central curvature is greater and more powerfully refractive than has been thought hitherto is made probable by the reduced size of the images obtained as against rest (I must here repeat that no mydriatics were used) and by the differences observed between the ordinary drugless state of a highly hypermetropic eye and after eserinization. As Professor Sherrington pointed out to me, the apparent reduction in the distance of the two images is enlarged by the increased refractive power of the accommodated lens. This enlargement is caused not only by the increased curvature of the anterior surface but also by the increased thickness of the lens. The fact is hereby established that during accommodation not only the anterior but also the posterior surfaces participate in forming a double lenticonus such as sketched in Fig. 7. I had the privilege last month of demonstrating the case at Oxford at the meeting of the Physiological Society. On that occasion Professor Gotch was good enough to offer me the loan of the Helmholtz opthalmometer belonging to Oxford. I hope at the earliest possible date to go over the above investigations again, and to be able with the help of that instrument to supplement by exact and minute quantitative measurements the observations given above. Though some of them are only qualitative owing to the absence of such an incomparable instrument of precision as the Helmholtz ophthalmometer is, they are absolutely conclusive and irrefutable. In a case like this negative results might not have had a claim to generalization. Here, however, a number of positive facts have been found, most of them in harmony with, and corroborated by, previous

observations, none, not even the most striking new ones, incompatible with them.

I take this opportunity of expressing my sincere thanks to my friend Professor Sherrington, who not only with the greatest courtesy placed the resources of the Physiological Laboratory of Liverpool at my disposal, but also assisted me indefatigably in the often very tedious process of verifying and confirming the observations and measurements made.

REFERENCES.

[1] *Klin. Beit. z. Chir. und Ophthal.*, Göttingen, 1849. [2] *Het Accommodatievermogen der Oogen*, Haarlem. [3] Bemerkungen ueber den Accommodationsmuskel und die Accommodation, *Graefe's Arch.*, iv., 1. [4] *Arch. f. Anat. und Phys.*, Physiol. Abth., 1887. [5] *Arch. de Physiol.*, January, 1895. [6] *Graefe's Arch. f. Ophth.*, xlii., 1, p. 288. [7] *Ibid.* [8] *Ibid.* [9] *Optique Physiologique*, Paris, 1898, p. 165, and *Comptes Rendus Internat. Opht. Congrès*, Utrecht, 1899, p. 252.

[For the use of the blocks for illustrations we are indebted to the courtesy of the *British Medical Journal*.]

---

## REVIEWS.

O. WERNICKE (Buenos Ayres). **Congenital Word-Blindness.** *Centralblatt für praktische Augenheilkunde*, September, 1903.

THE literature of this condition is so far very limited, and indeed according to Wernicke it is entirely confined to English. The number of cases recorded is also very few, and Wernicke is therefore doing good service when he describes two more instances with which he has met in his practice; for in regard to any disease of which we know but little it is well to compare carefully with one another such examples as do from time to time crop up.

At the outset he mentions frankly that on looking back he recollects quite clearly a patient whom he saw some five

or six years ago, in whose case he failed to diagnose congenital word-blindness, though now, in the light of his later experiences and of the writings of others, he does not entertain a doubt that this unusual fault of development must have been present. It was that of a boy, aged 10, apparently quite normal in all respects, who, according to his father's assertion, seemed quite incapable of learning to read. Wernicke found a slight degree of hypermetropia and a normal range of accommodation, and most incorrectly, as he now recognises, informed the father that the failure seemed to him to be due to a want of diligence and attention. The reviewer has the more sympathy with Wernicke's error that he can recollect in his own practice a very similar case in which some few years ago he made what he believes now to be precisely the same mistake.

Wernicke's recent cases may thus be briefly summarised. The first was a young lady, aged 19, of Danish descent, whose family physician says she was always rather hysterical; in her family there was no history of nervous or of mental disease. In spite of all her efforts she could not learn to read properly; she could only do so slowly and letter by letter, so to speak; she could not take up a book and read it for pleasure, for the labour of making out the words deprived her of the power of comprehending what was written. And yet vision was above normal standard, the fundus normal, and accommodation quite active. She had previously consulted another surgeon who had corrected her hypermetropia, ordering her $+1{\cdot}50$ D, darkened because she was so blonde; these glasses, however, she had scarcely ever worn as she had no asthenopia; he does not appear to have recognised the true state of matters. Her intelligence was very good; she read figures quite readily and quickly, and she could speak two languages correctly. Her education had been perforce conducted almost entirely through the ear. Her incapacity gave her great distress, especially as she was about to be married. Of her further history Wernicke knew nothing.

The second case was that of a boy, aged 10, whose father had been somewhat dissipated, and had died insane. Of his elder brothers, one was weakminded, while another was a wonderful chess-player—could play several games at once, play blindfold, and so on. The patient himself had had poor health always, and had in consequence been somewhat irregular in school attendance. He gave the impression, however, of a bright, healthy, intelligent boy, and was stated to have a

retentive memory, to be observant, and to have shown skill in games. In school, however, he had not shone, for on account of his failure in reading he had been kept constantly in the lowest class. Separate letters he read slowly though correctly, but connected reading was impossible to him; when dealing with long words he constantly made mistakes, especially with the termination, and the same was true, though to a less degree, even with quite short words. Reading could never be a pleasure to him, though he was anxious to learn; but at the same time he could read numbers with perfect fluency and correctness, and he did the same with geometrical figures, playing cards, chess problems, etc. Curiously enough, he seemed to read written words more readily than those printed; and if his own writing was bad, one had to bear in mind that his attendance at school had been very irregular. He could copy out from a book correctly enough, but to dictation his work was badly done; he was wont to leave out letters, syllables, and even whole words. His memory was very good, for even after a few minutes' interval he would repeat quite correctly a whole paragraph which had been read to him. Visual acuteness and the fundus were perfectly normal; he had a trifling degree of hypermetropic astigmatism.

In all the cases recorded up till now the reading of numbers and figures was much superior to the reading of words, a fact which gives one a useful means of diagnosis between this particular state of affairs and merely poor sight. Hinshelwood's dictum, however, that word-blindness must only be diagnosed in presence of full central vision, seems to Wernicke to be too stringent, for, as he rightly observes, there is no reason why a certain degree of amblyopia should not co-exist with word-blindness.

As regards the etiology of the condition there is little or nothing known. In one of the present cases the patient came of a decidedly neurotic stock, and Nettleship has observed something of the same in one of his. So far no relative of any of the patients has been discovered to have the same condition. Of the whole number of patients, namely, eleven, no fewer than nine have been boys, but probably the numbers are still too few to justify any generalisations. Any treatment must, of course, be purely educational, reading the same piece again and again so that memory may come to the help of the word-blindness, making words with loose printed letters, etc., and instruction may need to be largely or wholly

vocal. Wernicke agrees with Nettleship and Hinshelwood that perhaps the occurrence of this condition, or at least of mild degrees of it, may not be so very rare, but the cases seldom come to light.

W. G. S.

---

J. Boldt. **Trachoma.** *A. Hirschwald*, Berlin, 1903.

This book of two hundred and forty pages forms the nineteenth volume of a series of works on scientific medicine, edited by O. Scherning, and dealing more especially with the military aspect of diseases. But, although it is written by a military surgeon, abounds with statistics relative to the occurrence of trachoma in armies, and enters into minute details of the military regulations for coping with the disease, it is nevertheless an exhaustive treatise on the subject, and is based on a very complete and up-to-date survey of the literature. The list of references at the end of the book occupies no less than ten pages. Originality in a work on granular ophthalmia is hardly to be expected, the author has, however, had considerable experience, has carefully studied the opinions of others, and his deductions are sound. There is a certain amount of perhaps unavoidable repetition. The subject is divided into eight parts, viz.:—History of the Disease, Geographical Distribution, Symptoms and Course, Etiology, Diagnosis, Prognosis, Treatment, Prevention.

Figures are given showing the prevalence of trachoma at different epochs in the armies of Europe, and its universal distribution is proved by records from all parts of the world. The influence of climate, of elevation above sea level, of race, and of social and hygienic conditions is fully discussed. The author is not a great believer in the influence of race, and the so-called relative immunity of the Celt and the North American negro is disproved, in the former case by the endemic nature of the affection in Ireland, and the rarity of the disease in the latter is most probably due to the fact that he escapes contagion owing to want of intimate communication with the white population. For the South African Kaffirs, from whom he is descended, are very subject to it, as are also the negroes of South America, who belong to the same race as theNorthern. Again, the greater liability of the Jews can be explained on other grounds, as it is only the lower classes that are affected.

In Dublin we see many cases amongst foreign Jews, but they, as well as the natives, always belong to the poorer classes.

The acute variety of granular ophthalmia is rare; we cannot say that we have ever seen a case. The plain fact is that we have never been able to form a clear idea of what is meant by acute trachoma in an uncomplicated form. In 60 per cent. of the cases the lower lid is stated by Boldt to be the starting point of the disease. This is quite contrary to our experience, unless one assumes that by the time the upper lid has become involved the disease has passed away from the lower, without leaving any traces, which is manifestly absurd. It is generally believed that actual contact with the secretion, directly or indirectly, is necessary for the propagation of the disease. The degree of contagiousness is limited and conditional, and is greatly facilitated by ignorance, want of cleanliness, overcrowding, etc. The existence of an individual predisposition in some cases is probable and may be inherited. Local conditions such as chronic conjunctivitis may predispose.

A local increase or development of lymphoid tissue may result from so many different forms of conjunctival irritation, that until the real exciting cause of trachoma is known many differences of opinion must exist as to its relation to follicular ophthalmia, and as to the diagnosis of doubtful cases. The clinical signs, on which alone a diagnosis can be founded, are very badly defined in the very cases in which an accurate diagnosis is all important, namely, in the earliest stage of the disease. Chronic blennorrhœa also presents a great similarity to the papillary variety of trachoma. Spring catarrh, tuberculosis, and chronic irritation resulting from the presence of foreign bodies are liable also, but in a less degree, to be mistaken for it. Attention is not sufficiently drawn to the fact that a slight degree of follicular enlargement is frequently present in children and does not give rise to any inconvenience. Indeed we have seen indiscriminate treatment of such cases in a school produce an apparent epidemic of conjunctivitis. The author recommends that doubtful cases should be treated therapeutically as follicular and prophylactically as trachoma.

A very good résumé of the different methods of treatment is given. In the author's opinion there is no universal treatment, but each case should be dealt with on its own merits, and in order to obtain the best results much experience, careful observation, and a perfect knowledge of the technique

are necessary. He places more faith in nitrate of silver than in any of the recently introduced organic salts of silver. This quite agrees with our own experience. He speaks very favourably of "expression" and excision of the upper fornix, with or without removal of the tarsus. Expression he considers more suitable than excision for children. The objections to excision, when properly performed, are purely theoretical. In performing this operation, care should be taken that the conjunctiva can cover the whole of the upper part of the sclerotic on extreme downward movement of the eye. Excision of the tarsus alone is recommended in old cicatrised cases. The X-ray treatment is not referred to.

The final chapter discusses in great detail the means to be employed for checking the disease, including military and state regulations. All attempts in this direction must, however, be incomplete as long as the ignorance and social misery of the poor remain unrelieved.

L. W.

---

CAMILLE FROMAGET (Bordeaux). **Treatment of Recurrent Hæmorrhages of the Vitreous by Hypodermic Injections of Gelatine.** *Annales d'oculistique*, September, 1903.

AFTER referring to the work of Dastre and Floresco on the effect of gelatine on the blood, and of Paul Carnot and Lancereaux, who employed glycerine in the treatment of aneurysms of the aorta, the writer records his experience of hypodermic injections of glycerine in cases of recurrent hæmorrhages into the vitreous in adolescents. Fromaget adopted this method of treatment in four cases and in all of them obtained excellent results. He only records the notes of his first two cases, as he considers that a sufficient length of time has not yet elapsed since the injections were made in the other cases.

CAS 1. *Recurrent hæmorrhages into the vitreous. Three recurrent hæmorrhages in the left eye: blindness. Single hæmorrhage in the right eye. Hypodermic injections of gelatine.* The patient was twenty-four years of age. There was nothing to record as regards the family or personal history. He suddenly lost the sight of his left eye when working at a forge. The hæmorrhage was spontaneous. The

sight gradually returned, but at the end of six months a second hæmorrhage occurred; this also became absorbed. A number of months later, at the end of 1896, a third hæmorrhage took place. In February, 1897, when Fromaget saw him for the first time, he had been unable for four months to see with the left eye. He had been previously treated by injections of pilocarpine. The eye was absolutely non-illuminable and the pupil reflex was feeble. The vision of the right eye was normal, but there were numerous flame-shaped hæmorrhages at the ora serrata. The cause of the hæmorrhages was not known. The patient, however, was anæmic, the result of having lived abroad in a trying climate, and of slight dysentery. Leeches were applied to the temple and iodide and quinine given internally. He returned in the following August alarmed because the right eye, which he had believed to be healthy, had now become affected. The left eye was still in the same condition. Two Heurteloup leeches were applied to each temple and next morning fifty cubic centimetres of two per cent. gelatine were injected under the skin of the abdomen. The injection, a little painful although made very slowly, gave a slight local and general reaction, but was rapidly absorbed. Three days later another injection of fifty cubic centimetres was made. In February, 1898, the vision of the right eye was good; in the retina were the remains of old hæmorrhages. The left eye was blind and had a retinal detachment. Two hypodermic injections of 100 cubic centimetres of two per cent. gelatine were made in the abdomen at an interval of two days; these were well borne. He left the clinic at the end of a week. In April, 1899, the right eye was satisfactory; there had been no more hæmorrhages. In December, 1901, the vision of the right eye was still quite satisfactory.

Case 2. *Hæmorrhages into vitreous. Three recurrent hæmorrhages in the right eye. Single hæmorrhage in left. Six injections of gelatine after failure of numerous medicines.* The patient had been totally blind for several months when he consulted Fromaget in November, 1899. He was twenty-three years of age and had always had good health until April, 1897, when he developed chronic pleuro-bronchitis. In November, 1897, there was hæmorrhage in the right eye. A blister was applied to the temple, and atropine and iodide of potassium were prescribed, but without improvement after six weeks' treatment. He then took perchloride of iron and lay

on his back for four months, from January to May, 1898. Deriving no benefit the patient discontinued the treatment. June, 1898: The right eye cleared up. Hæmorrhage occurred in the left. August, 1898: Fresh hæmorrhage in the right: total blindness. The right eye for a second time improved. April, 1899: A third hæmorrhage occurred, so that he again became blind. He was treated with perchloride of iron and given milk diet. Many other drugs were also tried. In November, 1899, when Fromaget saw him, he was blind, but the pupillary reflexes were excellent. Six injections of 150 cubic centimetres of two per cent. gelatine were made under the skin of the abdomen at intervals of three or four days. A month and a half afterwards the right eye had cleared up and two weeks later the left eye had recovered its vision. Subsequently to aid the resorption of the hæmorrhages the constant current was used for ten days. On the 15th of December, 1901, vision was "excellent" in both eyes.

C. H. U.

---

HILLEMANNS (Duisburg). **The Relations between Glaucoma and Detachment of the Retina.** *Klinische Monatsblätter für Augenheilkunde*, October, 1903.

WHEN we consider the fact that though glaucoma and detachment of the retina are both so frequent in their occurrence they very rarely are met with in the same eye at one time, it can hardly fail to be suggested to us that the two conditions are actually inimical to one another. Apart from sarcoma, the tension is extremely rarely raised in detachment of the retina, indeed, raised tension would rather have the effect of keeping the retina *in situ*, one might suppose, and when detachment does occur in glaucoma, that might almost be said to be only in the late stages when the tension has begun to go down again, or when hæmorrhage has occurred. One has only to think of the kind of patient affected and the mode of progress to see clearly how little the two diseases have in common. Investigations on the subject present this difficulty at the very outset, that we are ignorant of the actual cause of either disease. One can hardly say more regarding the occurrence of detachment than that the condition *sine quâ non* is an increased fluidity of the vitreous humour. In a case, then, of primary glaucoma with secondary detachment, one is left to suppose that the original lesion of nutrition has now attacked the vitreous; then if we adopt the theory of Leber

and Nordenson, we may say that the bands in the vitreous humour, which by contracting cause separation of the retina, have begun to form; or if we, on the other hand, accept Raehlmann's doctrine, we may predicate the existence of albuminous exudation behind the retina, which by attractive osmosis causes more and more advancing separation. But looking at the matter in another way, we may ask, "Then why is glaucoma so very rare in primary detachment?" The only ready answer is that the conditions essential to the development of detachment very rarely interfere with the excretion channels of the eye, but should this occur, as in point of fact it does occur in certain cases of irido-cyclitis, then the way is prepared at once for the occurrence of glaucoma with subsequent separation of the retina. Whether the two diseases can, apart from tumour and hæmorrhagic extravasation, be set up by the same anatomical changes in the uveal tract, is a matter which must remain for the meantime in abeyance. Glaucoma takes its origin primarily in the anterior half of the eye, and detachment primarily in the posterior.

Without pretending to finality or exhaustiveness, Hillemanns divides the cases into four primary groups, with sub-classes, of which he gives illustrative cases:

1. In the first group there is a common original cause of both the glaucoma and the detachment. In the vast majority of cases this is a new growth. In every case one must be most suspicious of a tumour, but for all that a certain number of eyes have been enucleated under these circumstances in which the expected tumour was not to be found on section of the globe subsequently. Hillemanns mentions particularly two cases, one by Fuchs and the other by Dransart, in which detachment *plus* glaucoma appeared to necessitate enucleation, but no tumour whatever was present. Most of the cases in which a tumour is not present are examples of detachment with hæmorrhagic processes going on in the retina.

2. In a second group the glaucoma is the initial lesion, and (*a*) the detachment occurs during the stage of degeneration consequent on the glaucoma, which may take the form either of phthisis bulbi or of staphyloma (or ectasia), and in either of these detachment may be present. But (*b*) even in the earlier stages of glaucoma, though much more rarely, detachment may develop, either (1) when the glaucoma is already absolute, or (2) even when the eye still retains some degree of vision. Raehlmann, among others, has recorded two well-

marked instances, in both of which the affection was unilateral. But there is yet another set of conditions, namely (*c*), detachment occurring subsequent to iridectomy performed for glaucoma. Thus this was known to occur in the case of a boy aged 13, the subject of myopia (4D.) and chronic glaucoma, in whom detachment came on three weeks after iridectomy (Somya).

3. Detachment may, on the other hand, be the initial lesion. In the majority of such cases the connecting link is an outburst of irido-cyclitis or the formation of synechiæ. In a number of these patients there are apt to be transitory iritic attacks, and at the same time a rise of tension. In such cases Hillemanns considers the best treatment to consist in instillation of atropin, and salicin internally. Some few posterior synechiæ are fairly frequently to be observed in long-standing cases of detachment.

Even in traumatic detachment, however, glaucomatous increase of tension may sometimes be observed. Leber, for example, described a case in which a long-standing, and most probably traumatic, detachment became complicated with glaucoma simplex and cupping. Hoor also described a marked case of the same condition, presenting some rather unusual features. It was that of a man, aged 45, who was injured by a blow from a flying piece of metal. He came under observation a month later, having opacities in the vitreous and a flat detachment of the retina outwards. Tension was + 1, but the field for white was not restricted. Eserine was regularly instilled for a month, but at the end of that time the eye was harder, the cornea steamy, the episcleral vessels injected, and spontaneous pulsation was visible in the arteries, but the detachment was entirely gone, though there were distinct colour changes over the area at which it had formerly existed. Six months later, when vision had very greatly degenerated, no sign of detachment could be found. The case shows well the antagonism between the two conditions.

4. In a fourth group fall to be placed those cases in which there is no definite evidence which of the diseases existing alongside of one another was the first to appear, an interesting example of which Hillemanns describes at some length.

W. G. S.

---

## OPHTHALMOLOGICAL SOCIETY OF THE UNITED KINGDOM.

*November 19th, 1903.*

The President, Mr. JOHN TWEEDY, in the Chair.

CARD SPECIMENS.

*Choroidal Degeneration of unusual character.*—Mr. G. W. Roll.

In the right eye of this patient, a large atrophic area was seen lying downward and outward from the disc, its outer boundary suggesting a shallow detachment of the retina with small rounded elevations on it, many fine tortuous branches of the retinal vessels seen upon it, and much scattered black pigment. There was also a central lens-opacity, and a good deal of fine vitreous haze. No tubercular history obtainable, nor any evidence of specific disease. Vision R. less than $^{6}/_{60}$; L.V. $^{6}/_{6}$.

*Ill-developed Cornea.*—Mr. R. W. Doyne.

The patient, a boy four years of age, showed remarkably flat corneae with a faint greyish arcus above and below of some 2mm. in breadth. Each cornea measured 10mm. in the transverse diameter; in the right eye there was 7D. of hypermetropia and in the left 9D. A slight variable convergence of the left eye was noticeable.

*Thrombosis of a Retinal Vein.*—Mr. G. H. Pooley.

This case presented a blind branch of the inferior temporal vein at some little distance from the disc.

*Sections from two cases of Subconjunctival Dislocation of Lens.*—Mr. G. E. Henderson.

CASE. 1.—This eye had been damaged by a blow from a stick, which dislocated the lens subconjunctivally upwards; acute inflammation ensuing, the eye was enucleated. On sagittal section of the globe through the dislocated lens, a tear in the sclerotic immediately above the limbus was found leading into a space under the conjunctiva which contained the lens; a large blood clot was present in the vitreous on the side opposite to the rupture, and extensive detachment of the choroid.

CASE 2. The eye had been ruptured by the patient striking against a door. The lens was dislocated subconjunctivally upwards. The wound through the sclerotic was immediately in front of the ciliary processes, and the edges of the wound were separated by partially organised blood clot. The iris in the region of the rupture was completely detached and was lying in the connective tissue between the sclerotic and lens capsule. Evidence of old choroido-retinitis was present in this eye, particularly in the region near where the rupture took place. In the first case the lens was entirely devoid of capsule. In the second case the eye had been presumably weakened by old inflammatory trouble.

*Sarcoma at the Limbus.*—Mr. W. H. Jessop.

The patient, a woman aged 36, gave a history of having had a swelling, raised and painless, on the temporal side of the right cornea for about one year. Some fifteen years previously she had received a severe blow on the eye, after which the eye remained bloodshot on the temporal side for several years. She showed no signs of disease in any other part, and no glandular enlargements. At the temporal side of the limbus of the right cornea, was a vascular, slightly black-pigmented, swelling, which just overlapped the cornea, the latter, however, not being infiltrated or changed in any way in the neighbourhood. Two or three enlarged conjunctival vessels reached the swelling from the lower and outer part and spread in numerous branches over it. The rest of the eyeball appeared healthy, and the vision was $^{6}/_{18}$. The swelling had been removed by means of a Beer's knife, but since the base looked healthy it was not cauterized. The growth was adherent to the sclerotic, conjunctiva, and cornea, and was composed of large oval and somewhat spindle-shaped cells having large nuclei; the cells in places showed a slightly alveolar arrangement, and there was some extracellular pigment. The growth was unquestionably sarcomatous; since its removal there has been distinct signs of recurrence. Mr. Jessop felt inclined to cauterize the recurrence; Mr. Devereux Marshall advised sacrificing the eye. The President stated that, from his experience the sooner enucleation was performed the better. Mr. Parsons thought the growth probably started from a mole, and that those growths starting from moles were not always so malignant as the typical melanotic growth which started in pigmented cells from the subepithelial tissue.

*Retinal Arterio-sclerosis: Is the disappearance of the vein where crossed by the artery due to constriction or to obscuration by the artery?*—Mr. R. W. Doyne.

In this eye, at one spot where an artery crossed one of the veins there was definite obscuration of the outline of the vein making it appear as if pressed flat by the artery. Mr. Doyne was inclined to the view that the vein was simply obscured, since he was unable to make out any distal heaping up of blood as one would expect were there any actual obstruction. Mr. Adams Frost agreed with this view of the cause, thinking the apparent gap in the vein to be due to the vessel being hidden by thickening of the coat of the artery by some highly refracting substance.

## Papers.

*Operation for Ectropion.*—Dr. Freeland Fergus.

This operation was suggested for the relief of ectropion caused by hypertrophy of the tissues near the free margin of the lid, brought

about by old-standing blepharitis marginalis, in which the lid margin had become thickened and rounded, the lachrymal punctum more or less obliterated, and the cilia absent. On carefully examining such an eyelid, it will be seen that it is the outer third that is affected, that is, the conjunctival surface from the free margin of the lid for a third of the distance towards the retro-tarsal fold. An incision parallel with the free margin of the lid is made in its whole length, separating the healthy conjunctiva from the diseased portion. The conjunctiva, from this incision to the retro-tarsal fold, is separated from its underlying connections, the hypertrophied conjunctiva is then excised from the incision to the free margin of the lid, restoring the free edge of the lid to its original thickness, and finally the healthy conjunctiva stretching from the incision to the retro-tarsal fold is drawn up to the edge of the lid and secured to it by a few points of suture. The success of the operation entirely depended upon the thorough excision of the hypertrophied tissue.

*Average Visual Acuteness.*—Dr. Freeland Fergus.

The statement that when a person placed at six inches from Snellen's test-types is able to read the smallest type, he is said to be possessed of normal visual acuteness, is the key-note of this paper, in which that statement is called in question, since it cannot be maintained that visual acuteness of $^6/_6$ is the average of mankind. The writer pointed out that there was a large class of patients having healthy eyes, which, however, might either be myopic, hypermetropic, or astigmatic, but having less than $^6/_6$ vision, and also that even with healthy emmetropic eyes the visual acuteness diminishes with years. Therefore, although it is true that there are a few eyes with better vision than $^6/_6$, it is undoubtedly the case that the average of healthy eyes is considerably below it. For these reasons the term "normal visual acuteness" should not, in the writer's opinion, be applied to the starting point of Snellen's scale. This fact was particularly brought into notice in dealings under the Workmen's Compensation Act, as for example in the case of a man who has entirely lost one eye but the other eye has escaped and is not in any danger of sympathetic ophthalmitis or irritation. On both sides it is perhaps admitted that the vision of the remaining eye is say $^1/_4$ of the so-called normal. The judge in such a case may argue that, since the man has lost one eye, and since the vision in the other is undoubtedly so much below what he from the phrase "normal vision" believes to be the average, the man is no longer fitted for his work, not realizing that the same man when endowed with both eyes in all probability did not possess a higher acuteness of vision than he now possesses with only one. Referring to colour defects, the writer considered that defective

light sense was more dangerous than defective colour sense. He considered that a committee on the relations of ophthalmology to the various trades and occupations of men might, from the standpoints of the political economist and of the statistician, be of great use to the community, and suggested that such a committee could be formed from the members of the Society.

*The judgement of the size and distance of objects.*—Mr. N. B. Harman.

The writer referred to a note in the *British Medical Journal*, 1903, 632, in which attention was drawn to an experiment in which, by an illusion, the experimenter was led to believe that objects seen were smaller and more distant than they were known to be; this had been attributed to the influence of the accommodation. Mr. Harman showed how the illusion might also depend on the state of the balance of the extra-ocular muscles, and that unconscious cerebration leads one to suppose that objects of a given size appeared when seen under conditions of unnatural convergence smaller and more distant, but when seen with unnatural divergence they seemed larger and nearer than they actually were. The writer then showed how, in the progression of the vertebrates, increase of visual acuteness was coincident with the moving forward of the eyes from a primitive lateral position in the head to a forward position in which the visual axes could approximate to a normal parallelism; this change was complete in man, and with him the judgement of position and distance was probably most perfect. In fish of the plaice tribe, which appeared to depend above all others on the acuteness of their vision, both eyes had assumed a position where the greatest degree of parallelism was obtainable, and in these fish the same special features of the superior oblique muscles were present which characterized the higher vertebrates and were not found in any other fish.

*Indirect Gunshot Injury of Eye: microscopical examination.*—Mr. E. Nettleship.

The important point resulting from the microscopical examination was the apparent migration of the grains of carbon of the powder from the sclerotic coat towards the interior of the eyeball.

REGINALD E. BICKERTON.

---

*With the February number will be begun the issue of a* CLASSIFIED BIBLIOGRAPHY *of publications dealing with Ophthalmology, which have been published in the preceding month. This the Editors will endeavour to make as complete as possible, and to keep as closely up to date of issue as possible. It is believed that such a Bibliography will prove of much value to readers of the* OPHTHALMIC REVIEW.

# NOTES ON THE CURE OF CHRONIC CATARRHAL INFLAMMATIONS OF THE LACHRYMAL CANAL WITH PRESERVATION OF THE NORMAL ANATOMICAL RELATIONS.

By W. Gordon M. Byers, *Assistant-Surgeon, Eye and Ear Clinic, Royal Victoria Hospital, Montreal.*

The initial changes in chronic catarrh of the lachrymal duct occur, as a rule, about the inferior meatus, just as in chronic inflammation of the middle ear the trouble most often begins at the mouth of the Eustachian tube.

Patients almost invariably complain at the commencement of their trouble that the epiphora is only present on going out into the cold or wind, or during or after a coryza; in other words, that the trouble only exists when the mucous membrane of the nose is unduly swollen. Later on they state that the watering of the eyes is aggravated by these conditions. The extent to which the mucous membrane about the nasal aperture of the duct is responsible for the epiphora can be demonstrated by placing a pledget of cotton wool soaked in adrenalin against the inferior turbinated bone and painting the mucous membrane beneath and to the outer side of this structure with the same substance in a manner presently to be described. In a number of instances eyes which have been obviously watery will after such applications become quite dry in the presence of the operator.

In a certain few cases where the eyes are rendered absolutely dry by the adrenalin, local treatment alone directed towards the reduction of the hypertrophied mucous membrane will prove entirely efficacious in stopping the epiphora. The parts about the anterior end of the inferior turbinated bone are lightly anæsthetised,

and a probe, bent at the required distance from its termination almost to a right angle and carrying on its end a small pledget saturated with the necessary astringent, is passed beneath the inferior turbinated bone, and left there for a short time well in contact with the mucous membrane about the opening of the duct. A little practice gives one facility in performing this slight operation, first suggested to me by Dr. Birkett, and as it almost always gives some relief in properly selected cases it should be used in conjunction with the treatment presently to be described if either alone fails to produce complete cessation of the epiphora. Nitrate of silver 2 or 4 per cent. every third or fourth day and argyrol 10 to 20 per cent. every second day are the best remedies for this purpose. In rare instances it may be necessary to employ chromic acid, the cautery, or even stronger measures to reduce the redundant mucous membrane.

Case 1. Four years ago there came under my notice a young girl who had been unsuccessfully treated for many months for an unusual form of superficial keratitis. The eyes were obviously watery, and on examining the nose the inferior meati were found entirely occluded by great vascular swelling of the inferior turbinates which disappeared very largely on applying cocaine. Removal of portions of the hypertrophied mucous membrane by snaring produced a most satisfactory result.

In the majority of cases local treatment of this kind will fail to give entire relief. Even though adrenalin produces temporary drying of the eyes the swelling is situated too high up to be successfully reached by the topical applications. We must rely here on solutions passed through the upper part of the canal.

To avoid some of the existing difficulties I have lately

adopted the following plan of syringing fluid through the lachrymal passages. Having slightly anæsthetised the eye, I place a small clamp over the upper canaliculus* in such a way as firmly but gently to prevent any fluid from regurgitating at this point. Then with a dilator the lower punctum is enlarged sufficiently for the insertion of a syringe-nozzle made in a special way.† The tip has the same calibre as that of Mr. Lang's for about 5mm., but at the end of this distance swells suddenly, so that, by rendering the lower lid tense with the one hand, and pressing the syringe firmly home with the other, regurgitation from the lower punctum is also rendered impossible. The advantages of this plan are that none of the fluid employed enters the conjunctival sac and that one can obtain in this way a force much greater than is otherwise possible.

The next step is to test the patency of the canal. For this purpose a solution of adrenalin 1—2000 is used. If the fluid passes readily through it will be found, after removing the clamp, that the eye has become quite dry. It might be well always where possible to try the effect of the adrenalin alone, for it is now pretty generally known that here at any rate the suprarenal derivatives occasionally produce not only a temporary contraction of the vessels, but lend them a better tone for a considerable length of time. I have two cases at least in which the epiphora has been entirely stopped for now over a year by the use of adrenalin alone. Adrenalin failing, the new silver substitutes—protargol, argyrol, and nargol—on account of their power to penetrate to the submucous

* One can as well clamp the lower canaliculus if so desired.

† Messrs. Weiss and Son, Oxford Street, London, have made for me a special clamp and nozzle-tip to meet the requirements.

tissues will be found of great service. Argyrol in solutions of 5, 10 or even 20 per cent. has yielded very satisfactory results in our work in Montreal.

If obstruction in any degree is found in the lachrymal canal one proceeds in a slightly different manner. Injections of adrenalin are made at short intervals without removing the syringe so that the mucous membrane, being contracted little by little from above downwards, the fluid can eventually be forced through in this manner. One cannot by any means overcome every case by this plan (certainly not in my experience where dilatation of the sac in any degree exists), but as a result of the extra power acquired from the clamp and the snub-nosed nozzle it is possible with adrenalin to re-establish patency in numerous cases which would otherwise be amenable only to probes—always painful, and commonly unsatisfactory in their results. Accidents after syringing the lachrymal duct have occurred only in cases where previous slitting of the canaliculus had been performed. It is scarce possible to believe that with perfect continuity of the parts any ill result could follow the application of this method, even though considerable force were used. Any possibility of mischance, however, can be entirely excluded by confining the procedure to those cases without dilatation of the sac and by judiciously regulating the amount of force employed. Once an obstruction has been overcome in this way patency remains or can be more readily produced on a second occasion. Let me quote one case in illustration:—

Case II. Two months ago a woman came to me with epiphora which had been troublesome for a year or more. She had delayed consultation because she feared she would be greatly pained. A very considerable degree of obstruction was overcome by gentle but firm injections of adrenalin in the way

described. Two days later argyrol passed readily through the duct without the previous use of adrenalin. The same treatment employed on three subsequent occasions gave the woman absolute relief from her trouble, and this without pain or disturbance of the normal anatomical relations.

Apart from states of simple hypertrophy, routine examination of the nose will now and again reveal conditions which are the direct cause of a blockage of the lachrymal duct. Especially should this be thought of where the epiphora is unilateral.

Case III. In 1898 a woman came to Dr. Buller's Clinic complaining of troublesome watering of the left eye. Examination of the nose showed disease of the upper air passages, and as a very unusual thing a large mucous polyp blocking the inferior meatus of the affected side. Removal of the growth by Dr. Birkett gave immediate and permanent relief.

Case IV. In January, 1903, a young man consulted me at the Victoria Hospital also for epiphora of the left eye. In the nose the inferior turbinate bone of the same side was found to project almost horizontally outwards. From its free border the mucous membrane dropped as a hypertrophied curtain and was pressed towards the inferior orifice of the duct by a small septal spur likewise covered with hypertrophied mucous membrane. I snared the mucous membrane from the septal projection, thinking later to deal with the other parts. The preliminary operation sufficed, however, to entirely relieve the patient of his symptoms.

Case V. In the month of October, 1903, a boy, aged 9, was sent to the hospital from one of the charitable institutions of the city with a large mucocele on the right side. From the septum of the nose on the same side a long thin cartilaginous spur extended directly outwards and pressed so firmly against the surface of the inferior turbinate bone that only with difficulty could a small probe be passed between the opposing

structures. Dr. Buller kindly handed the case over to me, and I removed the spur and probed the duct without slitting the canaliculus. The result, of course, cannot be stated at this time, but under any circumstances there can be little doubt that the dacryo-cystitis was secondary to the pressure of the spur.

Since 1898 we have treated about 60 cases of chronic catarrh of the lachrymal canal at the Royal Victoria Hospital, and in all of these a routine examination of the nose has been made. In about 5 per cent. of the cases therefore obvious nasal conditions such as I have enumerated have been the direct cause of the trouble. This is probably a fair estimate, but even for a smaller percentage of cures one ought to be willing to make a hasty examination of the nose in every case of lachrymal obstruction.

---

## REVIEWS.

Momoji Kako (Japan). **Eye Affections in Diabetes Mellitus.** *Klinische Monatsblätter für Augenheilkunde*, March and April, 1903.

We have to thank Professor Uhthoff for placing at our service the notes of his large experience of eye disease in diabetics, including both his hospital and private patients, and Dr. Momoji Kako for rendering them available to us by sifting, classifying, and commenting on them.

Out of a total of over 36,000 eye patients 280 were found to have sugar in the urine, and in 192 of these the eye affection was considered to be directly dependent on the diabetes. Of these 192, 84 were cases of cataract, 57 of retinitis, 16 of central scotoma, 16 of muscular troubles, while in smaller proportion were found refractive changes, thrombosis of retinal veins, opacity of vitreous, iritis, hæmorrhagic glaucoma and optic nerve atropy. It is to be observed, however, on reading the cases, that a stricter criterion as to what was or was not due to diabetes might have been applied, with the result of still further reducing these numbers.

For example, in only 30 of the 84 cases of *cataract* did the relative youth of the patient, the aspect and course of the cataract, separate it certainly from ordinary senile cataract; and it will, we think, best serve our purpose if we here confine ourselves to giving a brief account of one of the cases, which was undoubtedly diabetic cataract, and in which a microscopic examination of the eye-balls was obtained.

The patient was a pit-lad, 15 years of age, whose previous history and that of his parents presented nothing noteworthy. He had had symptoms of diabetes for six months, of failing vision for ten weeks. Vision was reduced to counting figures at one or two feet, the anterior chambers were shallow, the markedly swollen lenses presented a mother-of-pearl-like opacity of the whole cortex. The patient was pale and thin, with a dry, harsh skin; the urine had a sp. gr. of 1040, contained 7 per cent. of sugar, and a trace of albumen. Three weeks after admission he died in diabetic coma.

No lesion was found at the autopsy except in the eyes; in them the changes consisted in swelling and degeneration of the lens, and swelling and degeneration of the cells of the pigment layer of the iris. The most striking feature of a section of the lens was a homogeneous layer, just within the capsule, of coagulated albuminous material. It was thickest at the front of the lens, where the breadth of the layer was 8mm., thinning off to 2mm. at the posterior pole. It separated the cortex into a thin layer in contact with the capsule and a thicker one attached to the nucleus; both layers showed the lens fibres within, separated and breaking down into cavities containing debris. The capsule and the nucleus showed no changes.

Turning to the iris, its posterior layer was seen to be greatly thickened, with exaggeration of its normal folds, the thickening being due to the great enlargement of the pigment cells, and particularly of that layer of them which was in immediate relation with the aqueous. The swollen cells showed marked diminution of their pigment, and what remained of it was driven to the base and sides of the cell. These changes did not extend as far as the pupillary edge of the iris, but were continued a short distance on the anterior aspect of the ciliary bodies, where they rather abruptly ceased. All other parts of the eye were normal in appearance. Of 27 previously published sections of diabetic eyes this swelling of the pigment cells has been found in 25.

Of the 87 cases of *retinitis*, albumen was present in the urine in 21: in five of these the retinitis, either from its initial aspect or its further course was described as albuminuric; in seven others it was classified as mixed albuminuric and diabetic: while in 45 cases (in nine of which there was albumen as well as sugar in the urine) the name "diabetic retinitis" was given to the condition. The lesions in these latter cases were of two kinds: (1) plaques, (2) hæmorrhages.

Nine cases showed plaques only. These were sharply defined, glancing, white or yellowish-white spots, confined to the region of the posterior pole of the eye and for the most part irregularly scattered there, though in two cases there was a tendency to arrangement in a ring form. Their numbers varied from two to nine in each eye. The disc was quite normal, the retina showed no trace of swelling, and vision was comparatively little affected. Fourteen cases showed hæmorrhages only. These were small and scattered, with nothing characteristic about them.

It is notable that in seven out of the nine cases of plaques, and in 12 out of the 15 cases of hæmorrhages, the condition was present in one eye only. Plaques and hæmorrhages together were found in 21 cases, and in all but two cases they were present in both eyes.

Among the 16 cases placed under the heading of "*optic neuritis with central scotoma*," in only two, "according to the statement of the patient, the abuse of tobacco and alcohol could be excluded." The author admits that, as far as symptoms go, no absolute dividing line can be drawn between those which he classifies as diabetic amblyopia and the ordinary toxic type, but he considers that an unusually large proportion of the cases he regards as purely diabetic showed a scotoma for blue (sometimes with an absolute central defect); that the diabetic cases were as a rule of more advanced age; and that the pallor of the disc was of relatively late appearance in them. It must be admitted that the distinctions are slender.

There were 11 cases of *paralysis of ocular muscles* among the diabetic eye patients. Here again the question of the exact relationship between the diabetes and the eye affection was frequently a difficult one. Most of the cases occurred in the subjects of cerebral lesions, where there was the possibility that the diabetes itself as well as the paralysis was the result of the lesion. In five cases, however, owing to the absence of

other exciting cause, Kako thinks he is justified in regarding diabetes as the cause of the paralysis, viz., one case of complete external ophthalmoplegia, one of facial paralysis, one of ptosis, and two of sixth nerve paralysis.

A case of paralysis of the conjugate movement of the eyes upward and downward is interesting. It occurred suddenly in a man of 38, whose urine contained sugar, but who was otherwise well. The lateral movements of the eyes were good, but there was at the beginning a tendency when walking to run into objects on the left. The paralysis disappeared in about nine months. A hæmorrhage in the region of the corpora quadrigemina appeared to be the most probable explanation.

In five cases there was a history of temporary *failure of accommodation*, lasting from a few days to some months; it usually disappeared rapidly when general treatment was begun and it was doubtful whether it was to be regarded as an actual paresis of the accommodation, or merely as a part of the general loss of muscular tone.

Of a *change in the refraction* of the eye (in the direction of myopia) there were 10 cases, but five of these may be dismissed as being simply the initial stage of the development of cataract; in the remaining five no capacity of the lens was present. In two the change was of short duration only, in three it appeared to be permanent. In one case a lenticular astigmatism of 1·5 D. against the rule developed in one eye, the others remaining emmetropic. The patient was a medical man, and there seems no doubt of the correctness of his observation. He had been diabetic for many years.

A curious example of changes in refraction in connection with glycosuria is described by Alexander (Nürnberg) in the August number of the same Journal. A man of 57 stated that for a fortnight his distant vision had been bad, and that his reading glasses (+1·75 D.) were now too strong, as he was able to read with his former +0·75 D. He had had thirst and polyuria for two or three weeks; the urine contained 5·7 per cent. of sugar. The fundi were normal, the lenses quite clear, with −1 D. he read $^{6}/_{6}$. Directions for diet were given, and a −1 D. for distant vision. Five days later he rejected this glass, finding that he could again see as far as ever he could in his life. When tested at the end of the week he was found to be emmetropic; his general symptoms had also disappeared and there was no sugar in the urine. Five days after this he returned, much disturbed about his vision. The ophthalmo-

scope now indicated 1 to 2 D. of *hypermetropia*, his vision was $^{6}/_{60}$, improved to $^{6}/_{6}$ by +1·75 D. The urine was still free from sugar. His eyes very soon returned to their normal condition and did not again alter, nor was there any return of the glycosuria. He died, however, a year later, of progressive paralysis.

The occasional development of myopia in diabetes is well known, and is fairly explicable on the supposition of an increase in the density of the lens, or an increase in its curvature from swelling of the cortex. Hypermetropia, though not unknown, is more difficult of explanation, and Alexander seems reluctant to attribute it to changes in the lens or vitreous but prefers to credit his 57-year-old patient with a *latent* hypermetropia of 1·75 D., which became manifest owing to a temporary failure of accommodation.

W. G. L.

---

VETTER (Leipzig). **Bilateral Hysterical Amblyopia.** *Klinische Monatsblätter für Augenheilkunde, Beilageheft*, 1903.

A CASE presenting some very unusual features is recorded by Vetter, of which the following brief notes may prove interesting. It was that of a tailor, aged 35 at the time of the first entry in 1894, who came complaining of a dimness of vision of the left eye of two days' duration; he asserted that he saw coloured rings round a flame. Vision, on correction of his myopic astigmatism, was $^{6}/_{12}$ in each eye. He had a little catarrh of the conjunctiva on the left side, and a chronic cystitis as well. The cornea was clear, but its sensitiveness was a little below normal standard. The left pupil, too, was larger than the right, but it reacted to light; the tension was the same in the two eyes and the ophthalmoscope showed nothing amiss. The field of vision was full, but the accommodation seemed a little less ample in the left eye. On the strength of his subjective symptoms he was ordered to use pilocarpin; but he came back before long with the same symptoms, as well as some more general complaints; pain between the shoulders and in the abdomen, and a history of a fainting fit, though the physicians could find no definite lesion to account for such an occurrence. He could no longer read small type. Though the objective signs of glaucoma, save a slight enlargement of the pupil, were *nil*, in view of the urgency of those

which were subjective it was thought best to perform iridectomy. For a year or more he remained in the same state, with slight variations from time to time. Four years later he was back in hospital with fainting fits, and was found to be in a highly neurotic state, with persistent occipital headache, increased knee-jerks, sleeping badly, and irritable. His case was then definitely diagnosed as one of hysteria. Two years later he had a severe attack in which, after excessively painful spasms at the back of the head, he suddenly lost vision —he felt as though the room was filled with smoke. In this state he was brought three days later to the eye clinique. He was in a wretched condition, weeping, especially when left alone, complaining of agonising pain in the head, and of want of sleep. Vision was reduced to light-perception in each eye. The pupils were of medium size and reacted well to light, and the fundus was perfectly normal.

Treatment proving of no avail, he was allowed to go home, and his friends then placed him in an institution for epileptics, he having had some seizures which were diagnosed as of that nature. There he improved for a time, but after a violent attack (probably a hysterical fit) in September, 1902, he complained that sight was entirely gone. Four days after this he was unable to guide himself in broad daylight and could recognise no object. Examination fatigued him very greatly; he had violent pains in the head, and threw himself about in bed, crying out. He was given antipyrin, with an emphatic assurance that he would go to sleep immediately, and promptly fell asleep. On awakening he said he felt better, and recognised the hand at 1 meter distance. Re-examination with the greatest care confirmed the diagnosis made five years before, that there was no physical foundation for the symptoms, that the sole condition present was functional, hysterical. Under "suggestion" treatment his vision rose day by day until it reached $^{6}/_{9}$, when he was dismissed.

Such cases are but rare, for even when failure of vision of both eyes is complained of it is very unusual for a person to complain of so complete a loss. It is probable that from the beginning he never had any glaucoma, and that what good the treatment, including the operation, may have done was all by suggestion.

W. G. S.

ORTH. **Text-Book of Pathological Anatomy.** (*Lehrbuch der speciellen pathologischen Anatomie.*)

GREEFF. *Section of Above Dealing with the Eye.* Vol. i., 1902; Vol. ii., part 1, 1903. Berlin, Hirschwald.

THE publication of Dr. Greeff's second volume concludes the greater part of a carefully written text-book on the subject. It forms a special part of the *Text-Book of Pathological Anatomy*, by Prof. Orth. The already large and constantly increasing mass of literature dealing with the pathology of the eye has for a considerable period urgently required collecting, editing and expurgating. Since the work of Wedl and Bock no systematic effort has been made to meet this need. The original work of the present author in this field is a sufficient guarantee of the general high standard of the book. The illustrations, and these must form a most important part of any work on this subject, are on the whole excellent. They are also fairly numerous, though more might with advantage have been added. We must confess to a predilection in favour of illustration wherever possible by microphotography, notably in the case of bacteria; excellent as the drawings undoubtedly are, they fail fully to convey to the student what he may expect to see with the microscope. The first volume consists of five chapters devoted respectively to the conjunctiva, the cornea, the sclera, the iris and the ciliary body. Each chapter begins with the normal histology of the part concerned and its physiological variations. The first chapter is very carefully written, and deals with the whole pathology of the conjunctiva in an exhaustive and accurate manner. The bacteriological descriptions are excellent and up to date. The article on trachoma alone occupies 45 pages, and may be singled out for special praise, though the author's deductions on this much disputed subject will not meet with universal approval, and though the coloured plate which accompanies this article leaves much to be desired. The article on General Inflammation of the Cornea is supplied by Dr. Orth, and gives a masterly account of this battlefield of General Pathology. The bibliography attached to it is noteworthy for its completeness. The important subject of Corneal Ulceration is inadequately dealt with. No mention is made of Mooren's ulcer, an affection by no means so uncommon as is frequently supposed, and the pathology of which is still obscure. In an otherwise good account of Ulcus Serpens no mention is made of the lacrymal sac as a common source of infection. A

further description of the rarer forms of Interstitial Keratitis would have been of value. The various forms of Iritis are collected together as acute and chronic. The description of the former is very brief, and the ætiology is not discussed; syphilitic iritis is included among the chronic forms. A description of Tubercular Iritis is then interposed. A further description of Gummata of the Iris follows, in which it is explained that though these do occur they are comparatively rare and the swellings commonly found in syphilitic iritis belong to the secondary period and are really condylomata. It is customary in both French and German text-books to make this differentiation, but the separation of the two conditions rests on no definite pathological basis. From the standpoint of pathological anatomy it would have been preferable to have described syphilitic iritis as one connected whole.

The second volume consists of six chapters, which deal respectively with the Choroid, Sympathetic Ophthalmia, Myopia, Glaucoma, the Retina, and the Optic Nerve with the central vessel system. In the preface to this volume the author states that he has already exceeded the space allotted to him. He endeavours to disarm criticism by pointing out that he is only able to deal at length with the points at which he has himself worked. We must admit that when judged by the standard of the previous volume the second is a little disappointing. The important subject of Sarcoma of the Choroid only occupies twelve pages, and of these three are taken up by a clinical description which in so condensed an account might perhaps have been omitted altogether. The various degenerative changes are not described. In the account of alveolar sarcoma no mention is made of endothelium. It is true that in the description of intra-dural tumours of the optic nerve it is mentioned that tumours of this nature are termed endotheliomata, and that they may arise from the endothelium of the blood of lymph vessels. Even there, however, no account is given of the evidence on which this statement rests. A separate paragraph is devoted to Coloboma of the Macula Lutea, but includes no discussion of the various theories that have been advanced to explain the ætiology of the condition commonly known by that name. The chapter on Glaucoma is far too short, and the pathological changes that occur in glaucomatous eyes are barely touched on; no mention even is made of hæmorrhages in the retina. No allusion is made to the possible connection between glaucoma and altered secretion due to

vascular changes. The various theories that have been advanced to account for detachment of the retina are clearly stated and criticised, but no account is given of the observations of Nüel and Goldzieher on the part that may be played by the retinal vessels.

The article on Glioma naturally gives prominence to the author's own researches with the Golgi method. These results have been partially confirmed by Hertel, but deductions drawn from the application of this method to pathological material should be accepted with extreme caution, and it is interesting to note that Scaffidi has been unable to confirm the results, either by the Golgi method or by any of the numerous other methods of staining neuroglia (Bevan Lewis, Weigert, Mallory, Robertson, Yamagwa, Benda).

The concluding chapter gives an excellent account of our knowledge of the Pathology of the Optic Nerve. Two of the illustrations (figs. 135 and 137), reproduced from micro-photographs, are very inferior. The article dealing with the central vessel system is very complete.

The last volume is promised early this year, and the value of the work will be much increased by the index, which it may be anticipated will accompany it.

E. Erskine Henderson.

---

A. Peters (Rostock). **Traumatic Affections of the Cornea and their Relations to Herpes.** *v. Graefe's Archiv für Ophthalmologie*, 57, 1.

The traumatic affections in question are erosions, keratitis disciformis, and ulcus serpens. It may seem as if in the latter affection the whole causation was nowadays fully understood, but Peters argues that the action of the tissues implicated is not sufficiently regarded in the current views, and that a neurotic element is present without which the lesions would not occur in the manner in which we observe them. He starts from the consideration of corneal erosions, and enumerates the points which these cases possess in common with keratitis disciformis and ulcus serpens. Erosion of the cornea, described by Hansen in 1872 as intermittent keratitis neuralgica vesiculosa, by Grandclément as kératalgie traumatique, and ascribed by Hulke to injury of the nerve terminations, is generally admitted to exhibit a neuralgic character. Szili, however, who has

particularly paid attention to the loosened attachment of the epithelium in this affection, denies its neuralgic nature. This defective attachment of the epithelium has been observed by Peters in other corneal affections, and he regards it as the sign of a nervous affection. It occurs in keratitis dendritica and in herpes, and must be regarded as a blister-like elevation of the epithelium. It is seen also in keratitis disciformis, and in ulcus serpens. Other points in common exist in these various affections. The deep-seated grey streaks in the cornea which are probably the products of an œdema in stage of retrogression, are present in all these cases, so that we may regard a corneal œdema as the starting point in all of them. This œdema is an effect of nervous action, mostly produced by bruising, tearing, and twisting of the nerve endings, though, of course, in herpes the original lesion is probably neither peripheral nor traumatic. In nerve injuries generally œdema is a frequent occurrence. Cases of corneal erosion often present all the characters of purely herpetic keratitis. The neuropathic nature of all these lesions is also shown by the presence of anæsthesia or rarely of hyperæsthesia. Peters believes that the deep fluorescine staining of the cornea indicates a lesion of the endothelium, but that this lesion is not primary; it is rather a result of the preceding œdema, which is due to nervous action.

Peters attributes the acknowledged good effects of Saemisch's incision in hypopyon to the diminution of the corneal œdema, and regards the relative immunity of children to serious wound infection of the cornea as due to their corneæ being less disposed to œdema from nerve injury than the corneæ of adults. In animals, too, ulcus serpens is rare, and Peters has found experimentally that œdema does not follow corneal injuries in rabbits and guinea-pigs as it does in the human eye.

Peters' conclusions are:—(1) Defects of sensibility are the rule in erosions of the cornea, both after the original injury and during relapses, but above all after healing of a relapse. (2) The imperfect attachment of the epithelium to its base is nothing but the first stage of blistering, and is the result of an œdema, which also affects the deeper layers in the form of streaks of the posterior surface. (3) This œdema is shown to have a neurotic origin, judging by the analogy of herpetic lesions and by the observations of neurologists generally. (4) Keratitis disciformis differs only in degree from corneal erosions, inasmuch as the œdema injures the endothelium and

the aqueous consequently intensifies the opacity. The opaque disc is only exceptionally the result of an infection. (5) Many things point to the existence of similar tissue changes in ulcus serpens, which exert important influence upon the spread of the infection. (6) There is no essential difference between the herpetic diseases on the one hand and erosions, keratitis disciformis and ulcus serpens on the other hand.

J. B. S.

---

Posey (Philadelphia) and Others. **Diseases of the Eye.** *Lea Bros. and Co.*, Philadelphia and New York.

Under the able editorship of Posey this volume has been issued by Messrs. Lea, along with a companion volume upon Diseases of the Ear, etc., edited by Wright, these two varieties of specialism being frequently united in one person in the United States, as, indeed, is the case in some parts of our own islands. We confine our remarks here to the former portion of the work.

Like so many recent contributions to literature, it is a composite work; fifteen authors are responsible for various sections. Theoretically, of course, this excess of specialism is defended on the supposition that a book on Diseases of the Eye written by the "best man" on the muscles, the "best man" on the conjunctiva, etc., must make a complete whole better than any one writer could produce; but for our part we doubt this conclusion. It is quite easy to understand that a practitioner of long experience in clinical matters might wish to have the assistance of a bacteriologist in the preparation of a text-book, and perhaps of a colleague more deeply versed in mathematics than himself, but we fear the tendency to sub-classification is being somewhat overdone nowadays. One can the more freely make these general criticisms in this case, because for this individual book one has little but good to say. One particularly good feature of certain of the articles is the clear, intelligent arrangement of their parts. Duane's paper of about 70 pages on Refractive Errors in General is a shining example in this respect. With some of his teaching one may not agree, but he gives an excellent account of a systematic clinical method of dealing with cases, including in his article many minor, but important enough, details which are apt to be omitted from the writings of others as unworthy of notice. Würdemann's paper on Embryology and Diseases of the Uveal

Tract has similar good features, but these are somewhat marred by carelessness in composition; a number of names, too, are misspelt, and where he airs his Latin, as he seems rather fond of doing, he is apt to show a little tendency to forget his declensions. A similar carelessness about names is betrayed by Clark in a rather bald account of the Eye in Relation to General Diseases. There are three British contributors—Spicer on the Retina and Optic Nerve, Collins on Glaucoma, and Reeve (Montreal) on the Orbit, Lachrymal Apparatus and Lids. The two former have done their work very well; we cannot speak quite so highly of the last-named of these contributions; it is good, but not so good.

Posey's own article on the Examination of the Eye is brief and quite good; but the best paper, on the whole, we should consider to be that of Gifford on Sympathetic Ophthalmia. It is really an excellent account of the disease and the means of avoiding and of treating it. We notice that he favours evisceration as being the best preventive operation—an opinion in which he has more criticism than support, we should imagine, among his colleagues. He places great reliance upon a method of treatment in which also he has comparatively few adherents, viz., enormous doses of salicylate of soda. A very useful chapter closes the book dealing briefly with pathological and bacteriological work in connection with the eye. It is written by Shumway. Another good paper among those not hitherto remarked upon is that by Weeks on the Conjunctiva.

There are numerous and valuable illustrations, even if the best of these are borrowed from other works; and the letterpress is excellent. From a careful study of the book, however, we are disposed to agree with some recent writers that it is a mistake to employ paper so highly glazed for the printing of books; it is very apt to produce asthenopia!

---

ANTONELLI. **Optic Neuritis in the Course of Acute Infectious Diseases.** *Archives d'Ophtalmologie*, July to Oct., 1903.

IN this series of papers the view is upheld that all, or nearly all, infectious diseases are capable of provoking an optic neuritis, not only by the intervention of intra-cranial disease or local disease about the orbit, but by direct action of the toxin on the nerve. The subject is first approached from the point of

view of general pathology, and the importance of primary parenchymatous neuritis is dwelt on. Experimentally, by the injection of various toxic or irritating substances in the neighbourhood of the sciatic nerve in the guinea-pig, the local action of these substances on nerve tissue has been proved, a fact from which it is inferred that peripheral neuritis is caused, not by the direct action of microbes, but by that of toxic substances produced at the focus of disease and freely circulating in the lymph stream. In the case of optic neuritis, its frequency in connection with orbital cellulitis or sinusitis shows that it is at least as open to the local influence of toxic substances as other nerves, and the fact that it is surrounded by a lymph sheath obviously lays it open to the attacks of toxins in the general circulation. Further, the annular constrictions which exist in the bony canal and at the termination of the nerve makes the optic nerve peculiarly vulnerable. Having stated the *a priori* arguments in favour of his view, the author makes some general remarks on the diagnosis of these cases.

The neuritis which occurs may be either a papillitis or a retro-bulbar neuritis, and in the latter case, as is well known, the ophthalmoscopic signs may be very slight. In addition to the neuritis there may be present a subacute peripapillary chorio-retinitis, and in these cases some corresponding patch or ring of atrophy, or it may be merely an irregular distribution of pigment, may be left behind. In cases of doubtful diagnosis an unequal papillary reaction may be a useful sign, and the testing of the light sense should not be omitted. Thus, in one case when the neuritis had so far cleared up that the visual acuteness and field were normal, yet the proof of a defective light sense was elicited by the grey type. The affection is usually bilateral, but commences on one side generally five or six days before the other. The prognosis is usually good, but when a high degree of amblyopia lasts more than two or three weeks complete cure is improbable, and for a patient rendered nearly blind for as much as a month the prognosis is bad.

After the general considerations the author passes on to a summary of the recorded cases in several particular diseases. *Influenza* affords the commonest cases, of which about 60 have been already published. Some are papillary, some retro-ocular, almost all bilateral. The papillary form comes on early—perhaps the third or fourth day—and leads to rapid temporary loss of vision; the retro-bulbar form is less acute, though more so than ordinary toxic amblyopia with which it is

liable to be confounded. In both forms the prognosis is good and none except general treatment is indicated.

In *typhoid fever*, peripheral neuritis of one or more cranial nerves is a recognised though rare complication occurring late in the disease. About 20 cases of optic neuritis in this connection have been published. In a few cases it has been an early symptom, but far more commonly a late one, almost always affecting both eyes and taking the form of a subacute papillitis, leaving some degree of atrophy behind so that complete cure is rare. Of course the presence of meningitis must be excluded before reckoning a case as directly due to typhoid. In one case in which optic neuritis occurred along with a muco-purulent discharge from the ears, meningitis, although diagnosed during life, was at the *autopsy* proved to be absent, while typical typhoid lesions of the intestine were present (Braine-Hartnell, *British Medical Journal*, May 29, 1897). In another case there were signs of congenital optic neuritis and chorio-retinitis in a boy whose mother had typhoid from the 4th to 6th month of the pregnancy resulting in his birth. In another case a man of 38 with post-neuritic atrophy dated the onset of his blindness from an attack of typhoid at the age of 14.

Taking next the acute exanthemata, *measles* affords about 20 cases, but they are none of them free from the objection that they may have been secondary to otitis media or meningitis. In *scarlatina* many cases may be due to albuminuria, cerebral disease, or orbital cellulitis; from only two published cases can these be excluded. In *variola* the same holds good, the number of undoubted cases being only about four. A case of acute retro-bulbar neuritis in *varicella* was published by J. Hutchinson, jun., in the *Ophthalmic Review* for September, 1886.

In *malarial disease* optic or retro-bulbar neuritis is more common, some 20 cases having been published. Atrophy is a not infrequent result, but in the cases of congestion and œdema of the papilla occurring during the access of fever, the prognosis is good, even though temporary blindness may be present. In chronic cases with exacerbations of this sort a brown discolouration of the disc may be left behind. This is due to the deposit of pigment granules from the lymphocytes carried by the dilated capillaries.

*Syphilis* is one of the most common causes of optic neuritis.

Omitting all cases due to intra-cranial gumma and periostitis, three types may be distinguished:—

1. The pronounced papillitis which sometimes accompanies senile or malignant syphilis; a late secondary symptom.

2. Subacute cases with functional disturbance, but slight ophthalmoscopic signs, occurring in the tertiary stage of cases insufficiently treated. These cases were termed by Leber (1868) "chronic retro-bulbar neuritis with partial atrophy of the nerve." By intensive specific treatment it is claimed that the duration of these cases may be reduced to four or five weeks and the occurrence of atrophy altogether avoided.

3. Cases of congenital syphilis where optic neuritis occurs in infancy, leaving traces which persist.

*Diphtheria.* Some 10 cases have been published of undoubted post-diphtheritic optic neuritis. The course and prognosis is very similar to that of post-diphtheritic paralysis of other cranial nerves. When the serum treatment has been efficiently employed cases have not occurred, but, on the other hand, it seems to have no curative effect on cases already developed.

*Erysipelas.* Apart from the cases where the optic nerve is attacked by the direct extension of the disease, a few cases of double optic atrophy have been noted after an attack of erysipelas confined to one side of the face.

*Mumps.* Some 18 cases have been reported, mainly by army surgeons. It is a late complication, and the prognosis is as a rule good.

Among the other diseases in which isolated cases of optic neuritis have been noted are acute myelitis, whooping cough, acute rheumatism, purpura, typhus and gonorrhœa.

It might be supposed *a priori* that optic neuritis would be a frequent accompaniment of peripheral neuritis of other nerves, but as a matter of fact this is not common. A connection between herpes zoster ophthalmicus and optic neuritis was pointed out by J. Hutchinson and again by Jessop in 1886. Probably the herpes and the optic neuritis are both due to the same toxic cause. According to de Wecker the association exists in 7 per cent. cases of herpes zoster ophthalmicus.

Summing up the evidence, the author considers himself justified in maintaining that all acute general infections are capable of giving rise to optic neuritis, either retro-bulbar or papillary, some more commonly, others less so, and some quite exceptionally. These cases are much less frequently secondary

to meningitis or renal disease than has been supposed; they constitute an instance of true peripheral neuritis analogous to that known to occur in other nerves. Their pathology—caused by toxins, not by microbes—brings them into relation with cases of toxic amblyopia, ordinarily so called. Treatment must be directed to the disease of which the optic neuritis is a complication.

A. Hugh Thompson.

---

Wintersteiner (Vienna). **Pupillary Membrane with Anterior Synechia.** *v. Graefe's Archiv für Ophthalmologie*, lvii., 1.

The condition of persistent pupillary membrane with anterior synechia is one in explanation of which several theories have been brought forward. Some considered it due to a disturbance in the full development of the layer of mesoblast that grows in to form the substantia propria of the cornea and pupillary membrane and between them the anterior chamber; but Wintersteiner and others have held that it is the result of the perforation of a corneal ulcer after ophthalmia neonatorum and the consequent prolapse of this persistent membrane. A third view is that it depends on keratitis, with or without perforation, which if not the result of ophthalmia neonatorum is due to some intra-uterine inflammation.

Such speculations were all based on purely clinical observations of cases that were seen months or years after birth when the eyes were quiet; but here Wintersteiner seeks to bring additional proof of his theory by an account of the microscopical examination of an eye from a child six weeks old. In this case there was a history of ophthalmia neonatorum, and a large opacity of the cornea was present with a genuine adherent pupillary membrane; but the chief peculiarity was the adhesion of the lens to the back of the corneal cicatrix by means of very fine tissue. This condition he does not think can be used as an objection to his explanation when discussing the origin of the adhesion of the pupillary membrane in this case; he states his belief that this persistent fragment of tissue would, if left longer, have most likely retracted from the lens, leaving a simple anterior polar cataract, a condition noted in previous cases. Nor does he think that the fact that there was here an extensive leucoma is a valid objection simply because in similar cases only very small opacities situated in the deepest layers of

the cornea at the point of adhesion were recorded. He contends that, to judge from the microscopical appearances of the cornea, it would have most probably cleared up in so young a patient, and left only a faint opacity on the posterior surface. He does not assert that his view is suited to all cases of this condition.

THOS. SNOWBALL.

---

## CLINICAL NOTES.

LOCAL ANÆSTHESIA FOR EXCISION OF THE LACHRYMAL SAC.—Stock (Freiburg) is accustomed to perform excision of the sac, an operation to which in some cities somewhat free resort is made, under the anæsthesia produced by local injection of cocaine; but he finds that whereas when cocaine is used alone the duration of anæsthesia is very brief, if to the solution (1 per cent.) three drops of a (1—1,000) solution of adrenalin per cubic cm. are added, the effect of the anæsthetic is rendered much more energetic and more lasting. A few drops of this solution injected about the area are quite sufficient for the purpose. One should wait after the injection for a brief period, when the whole area will acquire a waxy, bloodless aspect. Naturally also, the hæmorrhage, sometimes very troublesome, is reduced to a minimum by means of this solution, and although symptoms have been carefully looked for there have been no indications of any injurious effects produced by the drug. Obviously the solution might prove very valuable also in various other operations on the lids, etc.—*Klinische Monatsblätter für Augenheilkunde*, May-June, 1903.

CONGENITAL ABSENCE OF PSYCHICAL AND REFLEX LACHRYMATION.—A boy, aged two and a half years, was brought to Sommer-Niedermendig by his mother with the story that he had up to that date never secreted any tears. It seemed that a circumstance had occurred proving clearly their entire absence, for the little fellow had received a burn sufficiently bad to leave a definite scar, yet neither at the time, nor during the frequent subsequent dressing, had the boy shed any tears, though "crying" lustily. He was a healthy, well-developed child, with salivary and other glands secreting freely; the tear passages seemed to be quite normal, but no form of stimulation

seemed capable of causing a flow of tears. Evidently from the history pain was not, and external stimuli were tried in vain, *e.g.*, the juice of an onion, touching the cornea and conjunctiva, tickling the nasal mucous membrane with a small brush. The eyes were sufficiently moist, but no irritation produced any flow of tears. Pilocarpin and iodide of potassium were tried internally, but with the same negative results. About six months after the examination the child died of diphtheria; the mother stated that for the last month or two the secretion of tears seemed to be rather more copious. No *post-mortem* examination could be obtained. It should be remembered that for some time after birth psychical lachrymation does not take place, though reflex secretion of tears is not altogether absent. Apparently such cases as this, where both varieties of lachrymation were practically entirely absent, even up to two and a half years, are almost unknown.—*Klinische Monatsblätter für Augenheilkunde*, May-June, 1903.

Extraction of Cataract in Presence of a Septic Condition of the Conjunctiva.—Ellett (Memphis, Tennessee) has modified a procedure recommended for certain cases of wound of the cornea to combat the dangers of extraction when the conjunctival sac remains persistently in a septic condition. He had to do with an elderly man with bilateral cataract whose conjunctival sacs were, and in spite of much and varied treatment remained, in a strongly septic state, pouring out quantities of purulent discharge. The plan adopted was first to incise the conjunctiva all round the cornea as though enucleation were to be performed; the conjunctiva was then freed well back from the upper and lower margins with a probe, the lens extracted quickly, with iridectomy and with a minimum expenditure of time and handling, and the upper and lower edges of conjunctiva sutured together over the cornea. When the wound was entirely healed these were set free. There was some little reaction at first, but the patient secured vision of $^{20}/_{30}$.—*Ophthalmic Record*, April, 1903.

Tattooing of the Cornea.—In the process of tattooing it is somewhat difficult to ensure that the "pupil" shall be circular and precisely in the proper position, and naturally the more exact it is in these particulars the more life-like is the result. To facilitate precision in the procedure Armaignac (Bordeaux) suggests a method which he describes as being of "child-like

simplicity," and which may readily commend itself. The instrument employed might be described as resembling a miniature saucer, very steep-sided and without a base, or as a hollow cone cut across; this has attached to it a handle, and where the cone is cut across are three or more minute teeth projecting inwards and downwards. The speculum being inserted, this is laid precisely over the "pupil" which is to be, the handle is held in the left hand, and the teeth grip the cornea and hold the instrument firmly in position. The little vessel, whose floor is thus completed by the cornea, is then filled with Indian ink, and through it the tattooing needle is employed. The sides of the "saucer" prevent the needle from straying to other parts of the cornea than that which the instrument encloses, and the ink inevitably is thoroughly introduced at each prick of the needle. Should the first tattooing be insufficient the instrument can easily be re-applied and the procedure repeated any number of times, but the precision attained by its means is such that any such necessity is not likely to arise; Armaignac names it "guide aiguille à tatouer," a phrase for which it would be difficult to invent a brief English equivalent. The instrument, even when made of silver, is of very small cost indeed.—*Recueil d'Ophtalmologie*, August, 1903.

Operations for Ptosis.—De Lapersonne has suggested the following method of attacking cases of ptosis, his procedure being a modification of that of Eversbusch, and directed towards accomplishing an actual advancement of the elevator muscle. The globe being protected from any possible injury by a shield in the upper *cul de sac*, he makes a long incision parallel with the lid margin and about 4 to 5 mm. above it. This is carried down to the tarsus, which along with its tendon is thus laid bare and thoroughly cleared both upwards and downwards; this process is much simplified if two small vertical incisions are also made. A needle is passed through the tendon from without inwards, and a second needle on the same thread is passed in a similar fashion through the lower portion of the muscular attachment. A second stitch is dealt with exactly in the same way, but lying to the outer side of the other; both portions of this second stitch are passed from within outwards. The tendon is now divided, or a portion is removed, according to circumstances, and the threads tightly knotted. In this manner Eversbusch's operation is modified, and is

brought into line with the other advancement operations. In the event of any redundancy of skin it is easy to remove a small portion before sewing together the superficial wound.

Gruening (New York) has been pleased with the success attending the employment of a method which he devised for himself but which he subsequently found had been advocated a number of years ago by Gillet de Grandmont. His method consists simply in the removal of a fusiform strip of the tarsal cartilage from end to end, of sufficient width to free the pupil from obscuration by the upper lid. As a matter of fact it is of little moment whether or no one sutures the cartilage. He has generally done so.

The method of Sourdille is very similar to that of Angelucci, as he himself points out, the main idea underlying both being to unite the levator and the frontal. He makes a curved incision 2½ cm. in length, whose summit is at the upper edge of the (shaved) eyebrow, and whose extremities are about 1 to 2 mm. below its lower edge. This is carried down till the "large ligament of the eyelids, or septum orbitale" is laid bare and button-holed. At once when this is done a morsel of fat will present, but this is replaced, and with a strabismus hook the tendon of the levator is picked up; it is easily recognised, for it is the first structure which presents itself. By means of two double-needled threads an X-shaped grip is obtained of the tendon, the threads being passed from before backwards, and the tendon is cut across at the level of the hook. The tissues are next tunnelled into between frontalis and periosteum, and into the tunnel and then through the skin 3 or 4 mm. above the original incision the stitches are passed, and when tied over a roll of gauze should at the time leave the pupil uncovered if sufficient effect is to be obtained permanently. He finds it best to tie a knot which can be made tighter subsequently or relaxed according to circumstances. This method has further the cosmetic advantage of leaving intact or of producing the normal furrow under the eyebrow, so apt to be done away with in ptosis itself and in the operation for its relief.—*Archives d'Ophtalmologie*, August, 1903; *Transactions of American Ophthalmological Society*, ix. iii., and *La Clinique Ophtalmologique*, March 10, 1903.

---

## OPHTHALMOGICAL SOCIETY OF THE UNITED KINGDOM.

*December 10th, 1903.*

The President, Mr. John Tweedy, in the Chair.

### CLINICAL EVENING.

Cases and Card Specimens.

*Arterio-Venous Aneurism of Orbit, recurring six months after Ligature of the Common Carotid.*—Mr. N. C. Ridley.

This patient, a woman aged 58, when first seen in 1901 had paralysis of the left sixth nerve, following a fall on the head. She was said to have had a stroke in the early part of the next year, after which the left eyeball began to protrude. Later on in the year the proptosis had much increased, with considerable œdema of the conjunctiva. No growth could be felt, nor was there any pulsation at this time in the swelling behind the globe, the pupil of that eye was dilated, and the vision poor. Fomentations and the internal administration of iodide of potassium caused much improvement, the proptosis disappeared greatly, and the vision became much better. An exploratory puncture gave no definite result. At the end of the year the proptosis began to increase and the eye again became red. In March (1903) pulsation and a thrill were first felt at the upper and inner part of the orbit. In April ligature of the common carotid artery above the omo-hyoid was performed. After the operation the proptosis decreased and the eye appeared to be normal again, though the vision remained $^{6}/_{36}$. In July, pulsation and the thrill again became apparent, and both have remained much as they then were up till the present time. The history seemed to point to fracture of the base of the skull injuring the sixth nerve, and wounding the carotid artery, causing a communication between it and the cavernous sinus.

*Retinal Vascular Changes.*—Mr. R. Marcus Gunn.

The patients showed obscuration of the retinal veins in one or two cases where the veins were crossed by arteries. The arteries in all the cases showed considerable thickening and evidence of disease. In one place the artery appeared as a white line, no trace of a blood current being apparent.

*A case of Pemphigus of the Conjunctiva of both Eyes.*—Mr. W. Anderson.

The patient, a woman aged 29, suffered from shrinking of the conjunctiva of both eyes. The right eye showed thickening of the lids with congestion of the veins in the upper lid. The conjunctiva of the

lower lid was much shortened, with obliteration of the lower cul-de-sac, and the lower lid was closely adherent to the globe. The upper cul-de-sac was not so much shallowed as the lower, but the conjunctiva was much congested, and adhesions existed, passing to the globe from the inner and outer canthi. There was some muco-purulent discharge, and above the R outer canthus could be seen a large moveable swelling, elastic in consistency, and gradually increasing in size, which most probably was a cystic swelling due to retention of the tears. Both puncta were patent, and the cornea was clear. In the left eye much the same condition existed, but in the lower cul-de-sac a row of deeply-seated, bluish vesicles was present, and there was no swelling in the region of the lachrymal gland. The movements of both eyes were limited, especially the upward movement. The skin over the whole body was covered with patches of dark-brown pigmentation, but no urticaria or infiltration of the skin, and no deep-seated epidermic cysts or enlargement of the glands. The vision in the right eye was $^{6}/_{18}$ and in the left $^{6}/_{24}$. The conjunctival lesion was concomitant with the skin lesion, which latter appeared to be an unusual case of pemphigus foliaceus. Some records of cases were given, but in very few of the cases so recorded had any mention been made of retention cysts as in the present case. In Vol. xiii. of the Society's *Transactions*, page 32, Mr. Adam Frost mentions a case with retention cyst, however.

*Hereditary Nodular Opacities of the Cornea.*—Mr. W. T. Holmes Spicer.

This condition was present in two patients shown, a father and daughter, and there was a history of a similar condition in a brother and a sister of the father. The patient was only conscious of being short-sighted, and that was to a very slight degree. On examining the cornea of the girl a number of grey spots were seen occupying the centre of each, leaving a clear area at the periphery as broad as the dilated iris, the epithelium of the cornea being only slightly raised over the larger nodules, although the area within which the nodules were lying, appeared with the corneal microscope to be quite in the anterior part of the cornea. Near the centre of the cornea two greenish spots were visible, placed deeper in the substance of the cornea than the grey ones. Near the centre of the cornea the opacities were closer together, forming irregular granular-looking opaque areas. In the father's eyes much the same condition was present, but the nodules appeared to be arranged in the form of short lines which crossed each other, forming a kind of network, and the surface epithelium was distinctly raised above each patch of deposit. The condition was not considered to be an inflammatory one but most probably a slowly progressive degeneration, due to the deposit of pathological material in the anterior part of the

cornea. Few cases have been pathologically examined, but in those which have, Chevallereau found crystals of urate of soda in one case; Groeunow found hyaline deposits; Fuchs, who had removed a piece of cornea by trephine, found changes in the lamellæ in the anterior part of the substantia propria of the cornea of an œdematous nature, with absence of Bowman's membrane. The nodules caused elevation of the epithelium, partly counteracted by reduction in the number of layers, and the nodules contained broken-up lamellæ and distorted nuclei with much granular material. Fuchs had also seen preparations of the cornea of a dog fed on thyroidin, which had shown a somewhat similar condition.

*Unilateral Anophthalmos.*—Mr. A. H. P. Dawnay.

The patient, a female infant aged 3 months, had been born at full time without much difficulty. The right side was anophthalmic. The lids were formed and edged with lashes. The palpebral aperture measured $\frac{3}{8}$th of an inch, with a small conjunctival sac in which nothing even of a rudimentary character could be found. At birth there was no conjunctivitis, and the left eye was quite normal, with a palpebral aperture measuring $\frac{3}{4}$th of an inch.

*Retinal Effusion.*—Mr. R. W. Doyne.

The patient, a labourer aged 65, complained of gradual failure of vision in his right eye during the last three days. There was no history of syphilis. Both pupils were active and equal, R.V. with sph. $7 = {}^{6}/_{60}$. L.V. with sph. $7 = {}^{6}/_{12}$. On examination of the right fundus a number of more or less discrete fluffy patches of whitish effusion were seen chiefly in the neighbourhood of the optic disc. In places, the patches almost concealed the retinal vessels, though the vessels themselves showed no obvious signs of disease; the disc itself was clear and well defined. A small loose tag hung from the upper and inner part of the iris, and a collection of extremely small pigment spots was seen upon the anterior capsule of the lens. Tension was normal. The urine was normal. Later the edges of the disc became blurred on its upper and inner sides, and some of the distal fleecy clouds of effusion became less marked.

*Arterio-Sclerosis.*—Mr. R. W. Doyne.

The patient, a woman aged 54, complained of loss of sight in the left eye. On examining the fundus, many of the vessels (arteries) appeared very bright, and at places where they happened to cross the veins the latter were obscured for a short distance on each side of the artery. Attention was drawn to the fact that the veins on the distal side of the

artery were not distended as they assuredly would have been if the artery had actually compressed the vein, destroying or flattening its lumen. Thickened radial arteries and high tension pulse gave evidence of arterial disease.

*Drawing of Fundus, showing marked Arterial Disease, with a Section of the Retina from the same case.*—Mr. Percy Flemming.

During life the arteries had a typical "silver-wire" appearance and caused venous obstruction at the points of crossing. There had also been several large hæmorrhages in the neighbourhood of the obstructed veins. The patient, aged 48, suffered from granular kidney, and died from apoplexy a few weeks after the drawing had been made. In the section, the retinal arteries were much thickened, the thickening being of a hyaline nature.

*Arterio-venous Aneurism.*—Mr. Eric L. Pritchard.

The patient, a woman aged 58, after having partaken of half a pint of whisky, had fallen down a flight of stairs on her occiput, after which she had been unconscious and semicomatose. A month after the accident complete paralysis of the right external rectus had been noticed and a blister ordered, as a result of which the conjunctiva and sclerotic became much congested and œdematous, but at the same time the paralysis began to improve. Just six weeks after the accident a small pulsating tumour appeared below and to the inner side of the right eye, which increased greatly, causing proptosis of the eye, with a clearly audible bruit over the eye. The retinal veins in the right eye were markedly engorged, and pulsated. The common carotid was tied, with the result that the pulsation and bruit disappeared. The day after the operation, however, the pulsation and bruit returned, but later became again less marked. At the present time the bruit can still be heard, and pulsation felt; the swelling below the right eye is sausage-shaped and lies parallel with the lower lid. The eye remained of normal tension, but with engorged retinal veins and arteries, and a semi-dilated pupil not reacting either to light or to accommodation. There was no proptosis.

REGINALD E. BICKERTON.

---

# Bibliography.

## Anatomy and Physiology.

Altobelli. "Relation between vision and illumination." *Archives Italiennes de Biologie*, xl., 1.

Bernard. "Studies in the retina, part vi., continuity of nerves through the retina." *Quarterly Journal of Microscopic Science*, xlvii., 3.

Schwarz. "Observations on mechanical stimulation of the retina." *Zeitschrift fur Allgemeine Physiologie*, iii., 2.

Thomas. "Anatomical basis of the Argyll-Robertson pupil." *American Journal of the Medical Sciences*, Dec., 1903.

## Congenital Abnormalities.

### Hygiene.

Cohn. "Importance of having oculists appointed to schools." *Wochenschrift fur Therapie und Hygiene des Auges*, vii., 17.

### Pathology and Bacteriology.

Bach. "The importance of bacteriological examination in operative work." *Zeitschrift fur Augenheilkunde*, January, 1904.

Giarrè and Picchi. "The bacteriology of the catarrhal conjunctivitis of measles and influenza." *Lo Sperimentale*, lvii., 5.

McNab. "Diplobacillus liquefaciens (Petit) and the diplobacillus of Morax and Axenfeld." *Klinische Monatsblätter fur Augenheilkunde*, January, 1904.

McNab. "Infection of cornea with bacillus pyocyaneus." *Klinische Monatsblatter fur Augenheilkunde*, January, 1904.

Zur Nedden. "Muller's trachomabacillus and the influenza bacillus conjunctivitis." *Klinische Monatsblatter für Augenheilkunde*, January, 1904.

Zobel. "A case of bilateral metastatic ophthalmia due to the pneumococcus." *Zeitschrift für Augenheilkunde*, January, 1904.

### Instruments and Apparatus.

Frost. "Ophthalmoscope for demonstrating the fundus." *Ophthalmoscope*, January, 1904.

Streit. "Javal-Schiötz's Ophthalmometer with figures in complementary colours." *Archiv für Augenheilkunde*, January, 1904.

### Therapeutics.

Bloch. "Dionine." *Wochenschrift für Therapie und Hygiene des Auges*, January, 1904 (from *Heilkunde*, vi., 11).

Krückmann. "Cataphoresis in the treatment of syphilitic diseases of the eye." *Zeitschrift fur Augenheilkunde*, January, 1904.

### Operations.

Haass. "Discission of juvenile cataracts." *Wochenschrift für Therapie und Hygiene des Auges*, vii., 17.

Schmidt-Rimpler. "Krönlein's Operation in a case of Tumour of Optic Nerve." *Die Ophthalmologische Klinik*, January 5th, 1902.

## Traumatisms.

Bár. "Percussion cap injuries." *Archiv für Augenheilkunde*, January, 1904.

## Tumours.

Benson and Symes. "Tumour of Orbit." *Dublin Journal of Medical Science*, January, 1904.

## Sympathetic Ophthalmia.

## Glaucoma.

Dunn. "Glaucoma caused by an overripe cataractous lens." *West London Medical Journal*, January, 1904.

## Amblyopia and Visual Defects.

Euslin. "Left homonymous hemianopsia from carbonic oxide poisoning." *Klinische Monatsblätter fur Augenheilkunde*, January, 1904.

## Refraction and Optical Questions.

Elschnig. "Refraction in new-born children." *Zeitschrift für Augenheilkunde*, January, 1904.

Heine. "The myopia question from the clinical and the theoretical point of view." *Archiv fur Augenheilkunde*, January, 1904.

Senn. "Corneal astigmatism and central choroiditis in myopes." *Die Ophthalmologische Klinik*, January 5th, 1904.

Stephenson. "Permanent paralysis of accommodation following typhoid fever." *Ophthalmoscope*, January, 1904.

## Regional Affections.

### Eyelids.

### Lachrymal Apparatus.

Ahlström. "Dacryops." *Klinische Monatsblötter für Augenheilkunde*, January, 1904.

Monesi. "The Lachrymal passages in the Fœtus." *Klinische Monatsblatter für Augenheilkunde*, January, 1904.

### Conjunctiva.

### Cornea and Sclerotic.

Carwardine. "Interstitial keratitis in acquired syphilis." *Ophthalmoscope*, January, 1904.

Hahlstrom. "Shaving off opacities of the cornea." *Klinische Monatsblatter für Augenheilkunde*, January, 1904.

Herbert. "Superficial punctate keratitis in Bombay." *Ophthalmoscope*, January, 1904.

Schalscha. "Injury to the cornea from nitrate of silver solution." *Wochenschrift für Therapie und Hygiene des Auges*, vii., 16.

Schulte. "Operative treatment of ulcus serpens." *Die Ophthalmologische Klinik*, January 5th, 1904.

### Iris and Ciliary Body.

Anderson. "Paradoxical pupil dilatation and other ocular phenomena caused by lesions of the cervical sympathetic tract." *Journal of Physiology*, xxx., 3 and 4.

### Lens.

### Choroid and Vitreous.

### Retina.

Elschnig. "The light streak on the retinal arteries." *Klinische Monatsblatter fur Augenheilkunde*, January, 1904.

Fränkel. "The non-involvement of part of the retina near the disc in sudden obstruction of the central artery." *Archiv für Augenheilkunde*, January, 1904.

Johansson and Petrèn. "Untersuchunger über das Weber'sche Gesetz beim Lichtsinne des Netzhautcentrums." *Skandinavisches Archiv fur Physiologie*, xv., 1 and 2.

### Optic Nerve.

### Muscles (and Strabismus).

### Orbit.

v. Ammon. "Periostitis and Osteomyelitis of the roof of the orbit." *Archiv für Augenheilkunde*, January, 1904.

Benson and Symes. "Tumour of orbit." *Dublin Journal of Medical Science*, January, 1904.

### Relations with Medicine.

Berger and Loewy. "Contracture of levator palpebræ in facial paralysis." *Revue neurologique*, xi., 23.

Carwardine. "Interstitial keratitis in acquired syphilis." *Ophthalmoscope*, January, 1904.

Darier. "New dental signs of hereditary syphilis." *Ophthalmoscope*, January, 1904.

Hinshelwood. "Ocular and other forms of chronic headache." *Glasgow Medical and Surgical Journal*, January, 1904.

Kampherstein. "The eye symptoms in multiple sclerosis." *Archiv für Augenheilkunde*, January, 1904.

Krüger. "The eye symptoms in diseases of the temporal and frontal convolutions." *Zeitschrift für Augenheilkunde*, January, 1904.

Opin and Rochon-Duvigneaud. "The Retinal and other affections of albuminuria." *Journal de Physiologie et de Pathologie générole*, v., 6.

Stephenson. "Permanent paralysis of accommodation following typhoid fever." *Ophthalmoscope*, January, 1904.

### Miscellaneous.

# ULCERATION OF THE CORNEA DUE TO INFECTION WITH BACILLUS PYOCYANEUS.

By Angus McNab, B.A., B.Sc., M.B., Ch.B.

The case which I now describe is from the Universitäts-Augenklink in Freiburg, of which Prof. T. Axenfeld is director. I add a summary of three other cases:—

Pauline K., æt. 40. Admitted August 8th, 1903.

*History.*

Sight was good until six days ago, when she noticed slight difficulty in seeing with the left eye; she had some giddiness and vomiting next day. There was no history of injury.

*Present Condition.*

Vision: R.E. = $^{6}/_{6}$ emmetropic.
L.E. = Hand movements.

Right Eye: No changes, superficial or deep, to be observed.

Left Eye: Some œdema of lids with slight ptosis; conjunctiva intensely œdematous and injected, especially the bulbar portion; circumcorneal injection of deeper vessels. The conjunctiva is covered with a greenish purulent secretion.

Cornea: Almost the whole of the cornea is occupied by a round ulcer with deeply *infiltrated* margins. The floor is necrotic and covered with *débris* of corneal lamellæ, which are separating off from the deeper part of the cornea. There is a crescentic margin of cornea 1·5 to 2mm. wide above and to the inner side, which is slightly opaque but not necrotic. Anterior chamber nearly full of pus. Pupil contracted. Ophthalmoscopic examination impossible.

*Progress.*

Pupil dilated with atropine. A film showed that pus from the ulcer contained the xerosis bacillus and a short fine bacillus, which was Gram-negative, and resembled B. pyocyaneus when grown on agar.

Aug. 9. Sæmisch section; very thick hypopyon evacuated. Cultures made from the hypopyon, with all possible care to avoid contamination with the ulcer itself, gave very vigorous growth of B. pyocyaneus.

*Treatment.*

Lot. hydrarg. oxycyanidi, $^{1}/_{3000}$; moist applications constant; scopolamine pushed.

Aug. 12. Ulceration arrested. A narrow band of clear cornea remains up and inwards; down and out the ulcer reaches the corneal margin. Vessels are commencing to invade the cornea.

Aug. 14. The corneal lamellæ are separating off from the floor of the ulcer, so that the centre is getting thinner and transparent. Cornea quite anæsthetic; no local pain, but general discomfort and loss of appetite. Temperature normal. The wound in the cornea gave way, and the aqueous escaped when the dressing was removed.

Aug. 17. The injection of the conjunctiva is much reduced. The corneal lamellæ have peeled off, so that the ulcer is very sharply defined, but there is no ectasia.

On Aug. 18th cultures were again made from discharge. They showed pyocyaneus, which, however, did not grow so rapidly as before.

Again on the 27th there were still some pyocyaneus bacilli, but the growth was much slower, and on September 4th this organism was not found, cultures only showing feeble colonies of xerosis bacilli.

From Aug. 30th the ulcer rapidly cleaned, and a band of vessels appeared in the line of section. These came from the iris lying behind and not from the corneal margin. The iris was firmly attached to the cornea, so that it was not surprising to find rise of tension, accompanied by headaches. Eserine was exhibited, but on September 5th a hæmorrhage occurred into the wound. The tension rose still higher, and an iridectomy was performed, there being then no pyocyaneus to be found in the ulcer or conjunctival sac. The result was good; the tension fell and remained down, with no subjective symptoms. The periphery of the cornea became fairly clear for about 1—2mm. The tension varied from normal to slightly sub-normal, and on September 30th the patient was discharged. The cornea was then covered with epithelium, a clear portion above and inwards overlying the iridectomy, the rest being densely opaque, but with no indication of further deeper changes. Vision = hand movements.

*Bacteriological Examination.*

The cultures were made on Agar and Löffler's serum; and bouillon was inoculated from the Agar growth.

Agar: Rapid growth of round colonies, running together and forming a thick shiny growth, greenish-blue fluorescent discolouration of the medium rapidly appearing. Pieces of the

medium treated with hydrochloric acid became reddish-brown, and with ammonia green with slight blue tint; extracted with chloroform there was a sky-blue colour without fluorescence. A culture about 14 days old gave a very marked smell resembling dried bones.

*Blood Serum.* Very rapid liquefaction of the whole medium.

*Bouillon.* Rapid clouding; green discoloration in 24 hours. Preparations of hanging drops showed rapidly moving bacilli.

From the above data the bacillus was diagnosed as B. pyocyaneus (Ernst, Ferari and Corsini).

*Tests of Virulency.*

On August 16th 1cc. of 24 hours old bouillon culture was injected subcutaneously into the abdomen of a guinea-pig of 405 grammes weight. The next day the animal was very sick, pulse rapid, refused food and remained quiet. The weight fell rapidly:—

| | Weight. | | | Weight. |
|---|---|---|---|---|
| 17th | 398 grms. | ... | 20th | 338 grms. |
| 18th | 372 „ | ... | 21st | 342 „ |
| 19th | 358 „ | ... | 22nd | 351 „ |

On August 20th the animal began to recover somewhat. A large subcutaneous abscess had formed, with sloughing of the skin over it.

On August 23rd the animal was killed, and the *post-mortem* examination showed abscesses in the spleen giving pure cultures of pyocyaneus. From the local abscess the same organism was isolated.

On August 16th a small quantity of an Agar culture was introduced into a pocket in the cornea of a rabbit, and in another case into the anterior chamber. In both a severe panophthalmitis followed with rupture of the bulb in 48 hours in the latter, and in the former sloughing of cornea in the same time.

Controls of all inoculations were made with a stock laboratory culture of pyocyaneus B., the results being similar, but showing a much lower degree of virulence than the cultures from the corneal ulcer.

*Remarks.* Infection of the eye with B. pyocyaneus is very rare, but the severity of the results when it takes place with a virulent organism is so great as to justify an attempt to draw a clinical picture, and to give grounds of

diagnosis, especially as treatment must be very prompt if any good result is to be obtained.

The literature of the subject supplies three[3] cases in which the bacteriology was thoroughly worked out; and a résumé of these shows certain features in common.

Case I. Prof. Sattler.[4] Patient, æt. 40, charcoal-burner. Injury with a piece of stone; two days later severe pain in the eye and side of the head; sleeplessness. Examined eight days after injury. Vision—hand movements at ½ metre. Lids swollen; chemosis and purulent secretion. Cornea: Purulent degeneration of the superficial lamellæ almost all over. It is thinned and covered by necrotic masses in process of being cast off. Fairly large hypopyon. Inflammatory condition continued for the next few days, and 14 days after injury protrusion of the bulb occurred, and exenteratio bulbi was performed. A localised abscess was found in the anterior part of the vitreous.

Case II. Prof. Sattler.[4] Patient, æt. 61, woman. Injury with piece of wood, but no wound seen by the practitioner who examined her. Admitted to hospital three days later, when on examination vision was found to be merely imperception of light of candle at 3½ metres; swelling of lids and chemosis were present. In the lower half of the cornea and reaching almost to its lower margin was a large loss of substance; the base of the ulcer was covered by necrotic shreds of tissue, the upper margin being somewhat elevated, infiltrated and yellowish-white. The rest of the cornea was dull and cloudy. Hypopyon occupied about half the anterior chamber. The ulceration spread, and next day the whole cornea was affected, the superficial lamellæ, however, alone being involved. Some protrusion of the bulb. Exenteratio bulbi was performed. A circumscribed abscess was found in the anterior part of the vitreous.

Professor Sattler's comment:—In both cases after injury a necrosis of the superficial layers spready rapidly over the cornea. There were further marked symptoms of panophthalmitis. In each case there was an abscess in the vitreous, from which very virulent toxins spread, causing œdema of Tenon's capsule and protrusion of the bulb.

Case III. Dr. Bietti (Pavia).[5] Patient, 52 years, labourer. Blow on the eye from a fist, but no actual wound. On

examination patient had an ulcer 3mm. in diameter in the middle of the cornea, with slight hypopyon. Sublimate was injected sub-conjunctivally, but the ulcer spread downwards, and the hypopyon increased till the anterior chamber was full of pus. Sæmisch section was performed on the fifth day; the hypopyon was fibrinous and could not be removed even with forceps. Panophthalmitis followed, and the eye was lost.

In these cases the bacteriological examination showed pyocyaneus $\alpha$ in the cases of Sattler, and pyocyaneus $\beta$ in the cases of Bietti and the author, all four having a high degree of virulence, and being pathogenic for laboratory animals.

The bacillus pyocyaneus appears capable, without any perforating wound or even any definite injury, of causing a very severe corneal lesion, taking the form of a keratitis with hypopyon, and passing on to necrosis and sloughing of the superficial lamellæ of the cornea. It thus gives the clinical picture of a very rapidly spreading shallow purulent corneal ulcer, with regular infiltrated margins, and base covered by necrotic *débris* of corneal tissue. The discharge is a greenish yellow pus in which large numbers of very virulent bacilli are to be found. The hypopyon is thick and fibrinous. The process is rapid, leading to abscesses of the vitreous and general symptoms of panophthalmitis.

*Treatment.* Early and free opening of the anterior chamber by means of a Sæmisch section seems to offer some hope of warding off panophthalmitis.

Other infections of the eye with pyocyaneus are the following:—Haab,[3] panophthalmitis following perforating wound; Terson, in a case of dacryocystitis; Herbert,[6] in cases of keratitis in Bombay. In these last the organism was observed in mild keratitis, and was inoculated into the human conjunctiva; small abscesses in the lids and a slight superficial keratitis followed; no virulency tests were made.

LITERATURE.

[1] ERNST. *Zeitschrift für Hygiene und Infectionskrankheiten*, 1887.

[2] FERARI and CORSINI. "Sul bacillo piocianico." *Ateneo medico Parmense*, Anno 3° Fasc. 2°, 1889.

[3] HAAB. *v. Graefe's Archives f. Ophth.*, 1897. Bd. xliv., 1, p. 201.

[4] SATTLER. "Ueber Bacillen Panophthalmitis." *Bericht über d.*, xxi., *Versamm. d. Ophth. Gesell. Heidl.*, 1891, p. 201, und 1892, p. 156.

[5] BIETTI. "Il Bacillo piocianico nel Cheratoipopio." *Annali di Ottalmologia*, 1899, Vol. xxviii.

[6] HERBERT. *Ophthalmic Review*, 1901, p. 339.

---

## TENTH INTERNATIONAL CONGRESS OF OPHTHALMOLOGY.

LUCERNE, SEPTEMBER 18TH, 1904.

### EXHIBITION.

The Committee of the Tenth International Congress of Ophthalmology has charged me with the preparations for the appropriate exhibition of all scientific apparatus, instruments, and the various appliances for instruction, which may be sent to the Congress.

I therefore request all colleagues, as well as all scientific, optical, and mechanical firms, who wish to exhibit any objects at the International Ophthalmological Congress in Lucerne, to apply to me before July 1st, 1904, giving an exact statement of the object to be exhibited, of the space demanded, and of the kind and strength of electric force which may be required.

Objects which are announced later can only be accepted as far as the space still available will allow.

Professor Dr. A. SIEGRIST, Bern.
Director of the Ophthalmic Clinic
of the University, Bern.

## REVIEWS.

L. Bach (Würzburg). **Pupillenstudium.** *Archiv für Ophthalmologie*, 1903, Band lvii., 2.

The author, who is well known for his work in this connection, gives here a short account of his clinical observations on the physiological and pathological conditions of the pupil, together with some notes on the theories that have been put forward to account for the various changes which have been observed. He begins by pointing out that in spite of its importance the examination of the pupil is apt to be somewhat neglected. This he is inclined to attribute to the lack of an exact system, and proceeds to give in full detail the methods which he himself employs. The importance of always working under similar conditions as to light is insisted upon, and the various conditions that may cause inequality of the pupils are next enumerated and discussed. Amongst these are specially noted the comparative frequency of congenital differences and the great variety to be observed in the lid closing phenomenon. The author points out that a previous inequality of the pupil due to an error of refraction may subsequently be neutralised by some lesion in the centripetal tract. He next discusses the light reflex, and while offering no opinion on the seat of the origin, insists on the probability of the existence of separate fibres for the light sense and for the pupil reflex which run together to the neighbourhood of the external corpus geniculatum, and there separate.

The author then discusses the cortical reflex described by Haab. He gives details of an improved method of eliciting it, but admits that he is at present unable to attach any practical or diagnostic value thereto. No account is given of the physiology of its production or localisation.*

Contrary to the generally received opinion, it is stated that the contraction of the pupil on closing the lid may frequently be observed in normal eyes, and may be more conspicuous on one side than the other. Two theories are advanced to explain the phenomenon. When an impulse to close the lid is started, a cortical impulse to the pupil innervation may also be sent out, or else a reflex stimulation through the trigeminus may reach the medulla, and pass by way of the posterior longitudinal bundle to the oculo-motor nerve. Four causes for

* A good account of this reflex will be found in an article by Parsons in *Journ. of Physiol.*, XXVI. 5.

the loss of the light reflex are given. The first two are the recognised affections of either the centripetal or centrifugal tracts. The third is referred to an affection of the reflex inhibitory centre and tract which the author assumes to exist as a result of his experimental work with H. Meyer. He locates this centre at the spinal end of the medulla oblongata, and suggests that the tracts may run in the lemniscus and posterior longitudinal bundle. Reference should be made to the paper in which these authors describe the results of their experimental work. A good diagram accompanies it. (*Arch. f. Ophth.*, Bd. lv., 3.) The fourth cause is stated to be an irritative affection of the sympathetic. The lesions that may cause hemianopic pupil reaction are clearly stated. The author has not been fortunate enough to meet with an uncomplicated case, but has been successful in a case of detached retina in determining the parts that were still active by means of their reaction to light. He expresses a wish for some simple contrivance for determining this reaction. A lamp for this purpose has been devised by Sir Victor Horsley. By means of this a small parallel beam of light can be thrown on any part of the retina.

In discussing the reflexly immobile pupil (Argyll-Robertson) the author insists on a more accurate definition than that usually given in the text-books. The definition he proposes is as follows:—A pupil is reflexly immobile when it does not react either directly or indirectly to light, but promptly reacts to convergence. A note is made of the frequency of the lid closing phenomenon in these cases.

Under the heading of paradoxical pupil an illustrative case is recorded, in which the symptoms of sympathetic affection were well marked. The theory advanced, that paradoxic reaction may have some connection with the lid closing phenomenon is difficult to follow, and, in view of the recent work of Langley and Anderson, quite unnecessary. (See *Jour. of Physiol.*, Vol. xxx., 1.)

In discussing the etiology of the reflexly immobile pupil, two cases are mentioned, in each of which the only lesion to account for its presence was an inflammatory affection in the occipital region. The various theories as to the seat of the lesion are enumerated. The author himself places it at the spinal end of the sinus rhomboidalis. In explaining the myosis that is generally present he rejects the theory that would attribute this to a sympathetic affection, or to any tonic contraction of

the sphincter, and falls back on an irritation of his previously mentioned reflex inhibitory centre. The result of this is to check the reflex inhibition both for constriction and dilatation, but as the contraction tone is the more powerful, myosis and not semi-dilatation is the result. The author admits that this explanation is not altogether satisfactory as it is difficult to see how a pathological stimulus should fail to lead in the end to destruction of the centre. The explanation is offered that the lesion may be a destructive one situated in the tracts that lead from the centre.

An illustrative case of the so-called sluggish pupil in an apparently normal person is briefly discussed.

The rest of the article is devoted to a brief collection of the more important clinical variation of the pupil to be expected in various pathological states. This is preceded by some examples of the method of recording cases used by the author. Under the heading of paralysis of the sphincter two cases are given in which this was present owing to an affection involving the superior orbital fissure. Cocaine and atropine both caused dilatation of the pupil, while eserine caused contraction, thus showing that in spite of the lack of central innervation there was still present considerable tone in the sphincter. In a case of detached retina, although vision was reduced to light perception, the pupil still reacted promptly, affording evidence that the pupil reflex fibres retain their irritability longer than the sight fibres, or else that a smaller number of these first are sufficient to produce a reflex. Under the heading of the pupil in glaucoma we miss any mention of the oval pupil so frequently present in chronic cases.

E. E. Henderson.

---

W. Zimmermann. **Contribution to the Pathology and Treatment of Glaucoma.** *Beiträge zur Augenheilkunde*, 1903, Heft 58.

In this long paper the author brings together many facts concerning the causations of the symptoms which are grouped in the clinical picture termed glaucoma. He devotes the first portion of the article to a review and criticism of the various theories upon the origin of the affection, the second to a résumé of the facts of pathologico-anatomical interest, and then goes on to develop his own views upon the causes of

increase of intra-ocular tension. He considers that none of the theories hitherto advanced satisfactorily explain the origin of the different varieties of primary and secondary glaucoma, and has elaborated a somewhat complex mechanism, the fulfilment of the various conditions of which, he considers, affords a reasonable elucidation of the difficult subject.

According to Zimmermann's view, then, the primary cause of glaucoma is a difference between the general blood tension and that of the eye. This difference, he points out, is in many cases due to lowering of the blood-pressure in consequence of some general disease which affects the heart's action. The fact that the tension in the systemic arteries is lowered does not imply that the intra-ocular tension must fall also, for the statement is made (page 14) that "the state of the general blood-pressure exercises no influence upon the intra-ocular tension, etc." The influence of the decreased force of the cardiac action is manifested in the occurrence of arterial pulsation of the central retinal vessel, which, in the presence of other factors, leads to venous stasis in the retina and ultimately to transudation from this structure into the vitreous body. The result is that the vitreous body becomes engorged and presses the lens forwards upon the iris. The iris is further pressed upon, at a subsequent period presumably, by the ciliary processes, which also become engorged, and ultimately the root of the iris is applied to the posterior surface of the cornea and blocks the filtration spaces. At this stage *true increase* of intra-ocular tension is first manifested as distinct from the previous *relative increase* over that of the general circulation. From this point retrogression may take place by increase of the heart's action and rise of blood-pressure, as then venous stasis ceases to exist and absorption of the fluid transuded takes place. The lens falls back into its normal position, and the iris, in virtue of its own elasticity, is withdrawn from the posterior surface of the cornea.

It will be seen that *glaucoma simplex chronium sine tensione* is adequately explained by taking this view of the subject, as no absolute increase of tension is necessary to produce cupping of the optic disc. Thus expressed, the theory appears to be simple enough; but there are many difficulties in the way of its general acceptance, and to the removal of these Zimmermann devotes much time and space.

The frequency with which attacks of acute glaucoma occur after debilitating diseases is pointed out. The occurrence of

glaucoma after disturbances of the circulation in the eye, such as occur in optic neuritis, embolism, thrombosis, etc., is alluded to. The existence of arterio-sclerosis in many cases of glaucoma is mentioned, and its significance pointed out.

As regards therapy, the author considers that, as the disease is not purely local, the treatment must be, in part at all events, directed at the general defect, and recommends the use of a powerful cardiac tonic, such as strophanthus (with or without adonis vernalis). He cites the clinical record of several cases in which this line of treatment has been followed by a favourable issue. Several points of a controversial nature are raised in this paper, and it is regrettable that some of the most important are left undecided, mainly owing to lack of satisfactory evidence. For instance, no conclusion is come to regarding the question as to whether or not the tension in the anterior and posterior chambers must be equal, at any given moment, in the healthy human eye. The question is of great importance as regards this particular theory of glaucoma, and the author discusses it at some length, taking up the various views regarding physiological closure of the pupil and the flow of aqueous fluid into the anterior chamber; but it must be evident to the reader that no satisfactory conclusion is drawn from the arguments brought forward in the paper. Again, the precise mechanism by which the iris is brought into contact with the posterior surface of the cornea is not at all clear, especially as the explanations given are by no means conclusive. These and one or two similar defects distinctly mar the utility of what is otherwise a very interesting paper; in spite of this, however, Zimmermann's theory possesses certain attractions, and his paper is worthy of careful perusal.

LESLIE BUCHANAN.

---

WEINHOLD (Plauen). **Voluntary Dissociation of the Movements of the Eyes.** *Klinische Monatsblätter für Augenheilkunde*, August, 1903.

DR. Weinhold records a case which has come under his observation of a man, aged 23, who has possessed from childhood the unusual accomplishment of squinting upwards. Under ordinary circumstances the eyes are normal, move normally together, and have binocular vision. But he can voluntarily, in any position of the eyes, dissociate their movements, so that the left eye looks upwards relatively to the

position of the right. The dissociation occurs more readily and rapidly when the direction of the gaze is towards the right, requiring some seconds for its accomplishment when he is looking to the left; the extent of the upward movement is also greater in the former case than in the latter, being almost nil when looking fully to the left or up and to the left.

The author gives charts of the position of the false image in various directions of movement of the eyes, and from a comparison of these he arrives at the conclusion that the deviation of the left eye may be produced by an association of the centre for the left internal rectus with the neighbouring centres for the superior rectus and inferior oblique. Thus, when the left internal rectus is fully innervated, as in looking to the right, the associated movement is easily produced; when, on the contrary, the internal rectus acts only as an antagonist, as in looking to the left, the associated muscles are also less fully brought into play.

We are inclined to think that the author strains after an illusory exactitude when he adds the complication of "a relative reining-in of the left superior oblique" to account for a slightly increased elevation of the left eye in the down and out position; for, making some allowance for the fact that the ocular muscles do not always adhere strictly to their text-book action, the simpler theory seems to fit the main features of the case.

W. G. L.

---

V. Hanke (Vienna). **Two Cases of Rare Malformation of the Globe.** *v. Graefe's Archiv für Ophthalmologie*, lvii., 1.

Hanke gives here an interesting account of two rare malformations of the eye. The first of these is a case of bilateral congenital anophthalmos in an infant. The globe itself was represented by a tiny fibrous capsule, which enclosed some loose connective tissue together with a network of capillary vessels and a mass of pigmented cells. The subsidiary parts of the eye, such as the extrinsic muscles with their nerves, lacrymal gland, conjunctiva and lids were all present, but no trace of an optic nerve could be found. From an analysis of the shape of these pigment cells and the character of the pigment granules in and around them, Hanke believes they form with the capillaries the rudiment of the choroid and all signs of retina or any other derivative of the epiblast are entirely absent.

In discussing the cases of a similar nature found in the literature of the subject and their origin, Hanke dismisses those in which no microscopical examination was made as well as those in which there *is* evidence of an optic vesicle, however much its development may have been arrested, *i.e.*, cases of extreme microphthalmos; and he confines himself to those in which only tissues of mesoblastic origin are described or in which even these parts are absent.

While admitting the possibility that phthisis bulbi may occur in utero through inflammation in certain cases, he is inclined to find some other cause for those in which only mesoblastic tissues are present because there are absolutely no signs of a past inflammation and yet the epiblastic elements in the eye and only these are absent; he considers it impossible that such an inflammation could have completely destroyed the optic vesicle without leaving some trace behind and without in some measure affecting the development of the mesoblastic elements. He argues that the mesoblast may develop into its proper form without the presence of the optic vesicle, and comes to the fair conclusion that in cases like his own the elements of the neural epiblast, instead of being destroyed by inflammation, were really never present in the orbit, a hypothesis which is supported by the fact that here not only is all trace of retina and optic nerve absent, but the optic chiasma and tracts are entirely wanting.

Hanke notes that there were signs of catarrhal conjunctivitis in the eye, but apparently attaches no importance to this as possible evidence of some intra-uterine inflammation.

We may finally add that Hanke's views are supported by Collins and Parsons in a recent paper on the same subject. They, too, hold that "anophthalmos" is to be restricted to those cases where there is complete absence of any nervous or percipient mechanism, and as there was no evidence of inflammation in their case (a chick in which the rudimentary eye presented features similar to those of Hanke's) they consider that this condition is not the result of intra-uterine inflammation.

The second case is one of microphthalmos with a dermoid of the cornea, intra-ocular lipoma, and congenital aphakia. For a description of the microscopical details the reader must refer to the original article. The author believes that this complete absence of the lens and these new growths have all a common origin, and explains them in this way:—The

primary optic vesicle is formed quite normally, but between it and the external epiblast an unusually large process of mesoblast grows in, which prevents the invagination of the epiblast to form the rudimentary lens, and takes its place in causing the depression in the primary vesicle and the subsequent development of the optic cup; part of this mesoblast penetrates down into the latter and develops ultimately into the fatty tumour. He also attributes the origin of the dermoid, which is of exceptionally large size, in this case to the overgrowth of this mass of mesoblast together with the proliferation of the overlying epiblast. At the same time he does not mean to put forward this explanation as covering all such cases without exception.

THOS. SNOWBALL.

---

CALDERARO (Sienna). **The Treatment of Hypopyon Keratitis with the Sera of Tizzoni-Panichi and of Romer.** *Wochenschrift für Therapie and Hygiene des Auges*, vii., 2.

THE treatment of hypopyon keratitis is still unsatisfactory. Since the Fraenkel diplococcus is always present [? Ed.] in almost pure culture the use of anti-pneumococcic serum has naturally suggested itself to a number of observers, including Calderaro. He added some to the ordinary sub-conjunctival injections which he is in the custom of employing, and tried its use in 35 cases in which the specific coccus was present. The conjunctival sac was always washed out with 1 in 1000 solution of sublimate of mercury to prevent infection with pyogenic organisms. One-half of a hypodermic syringe-full was thus injected every two days, and the good effect was most evident provided only pneumococcic infection was present; the success was much less when staphylococci and streptococci were present in addition. In severe cases 5—10cc. were injected sub-cutaneously into the thigh in addition to local treatment. In eight cases the disease was only from three to six days old, that is, since the original trauma only that time had elapsed. In 27 cases the ulcer had lasted for eight to twelve days, the ulcer 4—6mm. in diameter, hypopyon about one-third and vision not more than perception of light. In these cases cauterisation, paracentesis, and sub-conjunctival injection resulted in a rapid recovery by the fifteenth day on the average.

In the cases of mixed infection instillation of a 5 per cent.

solution of collargol was employed. With this remedy, used every two hours, and a 20 per cent. ointment rubbed into the arms and temple for half an hour, five cases were treated; the hypopyon remained stationary for three to four days and then began to extend, and necessitated the galvano-cautery. Calderaro sums up this preliminary communication with these conclusions:—

1. The use of the serum is indicated, and is very effective, when the case is seen at an early stage; it should then be used twice as a sub-conjunctival injection, and instilled into the conjunctival sac every two hours.

2. In cases of advanced disease where cauterisation and paracentesis cannot be avoided, sub-conjunctival injections every other day should be given, along with two-hourly instillations.

3. If the ulcer inclines to spread owing to the presence of other organisms, instillations of 5 per cent. solution of collargol should be made either alone or combined with 1 in 100 methylene-blue.

4. The serum of Tizzoni is to be preferred to that of Pane and Römer not only on account of its greater effectiveness, but also because of the ease of keeping it; it is in the form of a dry powder, easily soluble in water, which does not lose its power; it is not expensive.

J. Gray Clegg.

---

Hansell (H. F.) and Sweet (W. M.). **Text-Book of Diseases of the Eye.** Philadelphia: P. Blakiston's Son and Co., 1903.

This book of 548 8vo pages, with 256 illustrations, is eminently practical in character. Disease is approached from the clinical side. Muscular and refractive anomalies are considered from the standpoint of the practitioner, rather than from that of the physiologist. To anatomy and pathology considerable attention is given, but always for their direct bearing on some point of diagnosis or treatment. Perhaps the most striking feature of the work is the abundance of half-tone reproductions of photographs and sketches illustrating various manipulations and operations. Almost without exception these pictures do illustrate in an admirable manner important matters that could not be so well portrayed by any verbal description. Perhaps the largest proportion of original matter will be found in three chapters prepared for the work by other well-known American writers on "Diseases of the Lacrimal Apparatus,

Orbit, and Cavities Accessory to the Orbit," by C. R. Holmes; "Ocular Symptoms in General Disease," by C. A. Wood; and "The Pupil in Health and Disease," by Wendell Reber.

---

HENDERSON (F. L.). **Lessons on the Eye.** Third edition. Philadelphia: P. Blakiston's Son and Co., 1903.

THIS book is intended for the use of the undergraduate student preparing for general practice. Its claim of originality lies in its omissions. The author believes that the student should have a book containing nothing except what he can fairly be expected to learn. Minute anatomy, the fitting of glasses, skiascopy and kindred subjects have been omitted; and those conditions which can be recognised only with the ophthalmoscope are slighted. That the book has quickly reached its third edition seems to indicate the popularity of its author's views.

---

W. N. SUTER. **Refraction and Motility of the Eye.** Philadelphia: Lea Brothers and Company, 1903.

ONE need not be very old in the profession to remember the time when Donders' classical work, with one or two short monographs on squint, constituted the special literature regarding errors of refraction and disorders of the eye movements. Now we have a score or more of monographs and hand-books. Suter's work discusses both subjects, giving a very clear, though condensed, outline of the theory of refraction and ocular movements. Such a general and theoretical view will need to be supplemented by clinical teaching and experience. But it is a view without which no one can become thoroughly skilful in dealing with the more difficult cases of refractive anomalies and disorders of ocular movement. The lack of such a grasp of the subject as an intelligent study of this work will give, seriously handicaps many an ophthalmic surgeon of excellent general attainments and of large experience.

---

C. A. VEASEY. **A Manual of Diseases of the Eye.** Philadelphia: Lea Brothers and Company, 1903.

THIS book is designed to meet the needs of students and general practitioners. In scope and method of handling its subject it resembles the well-known work of Nettleship. It contains several coloured plates showing fundus lesions, which are much better reproductions of the ophthalmic appearances than have

heretofore been given in works of this class. Probably coloured plates of this kind may be of far more value to the student and general practitioner than to the ophthalmoscopist of larger experience. The placing of such illustrations where they will be most useful is certainly to be commended.

---

BROWNE and STEVENSON (Liverpool). **Squint Occurring in Children.** London: Ballière, Tindall and Cox, 1904.

THIS is described by the author as an essay—and quite correctly. It is hardly a treatise, it does not give information sufficient for a beginner, but it is a pleasant, interesting and even at times an amusing discussion of the facts relating to squint in children. It is really the embodiment in print of the very sensible lines on which Mr. Edgar Browne proceeds in the treatment of his cases of convergent strabismus, the results of his extensive experience of this all too frequent malady.

---

## OPHTHALMOLOGICAL SOCIETY OF THE UNITED KINGDOM.

*January 28th, 1904.*

Mr. HIGGINS in the Chair.

CASES AND CARD SPECIMENS.

*Lymphoma of the Conjunctiva.*—Mr. L. Werner.

The patient, a woman aged 25, had noticed "fleshy lumps in the corner of the right eye which projected down from above" some twelve months before her admission to a hospital for treatment. She had never had either photophobia or any discharge, and comparatively little pain. On examination of the eye the upper lid was seen to droop very slightly and to be thickened near the edge, the skin, however, was normal in colour. A smooth, rounded fold of enormously thickened conjunctiva was seen to project from beneath the upper lid and to cover a portion of the corneal margin; it was of a pale, greyish-pink colour, with a semi-gelatinous look, and with a few small vessels on its surface. On everting the lower lid a similar but much smaller swollen fold appeared springing from the fornix, and on separating the lids the cornea appeared to be completely surrounded by a gelatinous cushion continuous on the outer side but not so on the inner. This cushion could be raised off the normal bulbar conjunctiva, which proved that it represented the much swollen retro-tarsal folds. The conjunctiva of the upper lid was also in a gelatinous condition and much thickened, with a smooth, though in places uneven, surface. The cornea, iris, and fundus appeared normal. No trace of the disease was present in the left eye. On examining pieces

of the excised tissue no trace of amyloid degeneration could be made out by the iodine and methyl-violet tests. Microscopical examination showed first a layer of thickened epithelium; second a layer of thickened sub-epithelial conjunctival tissue composed mostly of parallel fibres with increased cellular elements; third a deep layer of closely packed lymphoidal cells with relatively large nuclei and little or no visible protoplasm, this layer was almost non-vascular. The writer considered that the absence of vascularity, the presence of the reticulum, and the clinical symptoms all pointed to a non-inflammatory origin, and that the microscopical examination completely proved it to be a pure lymphoma. An examination of the literature of the subject showed that several varieties of the disease have been included in the term lymphoma, for instance:—1. Secondary involvement of the conjunctiva in cases of leukæmia or pseudo-leukæmia associated with tumours of the orbit and lids. 2. Pseudo-granular, or cases in which enormous follicles developed in the retro-tarsal folds and palpebral conjunctiva, accompanied by inflammatory symptoms. 3. Tumours, lymphomatous in character or lympho-sarcoma, and in one case a pterygium with lymphoid structure. 4. Diffuse lymphoid infiltrations of the conjunctiva. 5. Amyloid degeneration of the conjunctiva stated to be always preceded by proliferation of the adenoid tissue. Some 14 references were also given and the record of the case was accompanied by drawings and microphotograph.

*Congenital defect of Ocular Movements combined with peculiar Associated Movements of the Eyes.*—Dr. L. Werner.

The patient, a girl aged 12 years, had never been able to open her eyes. There were no eye troubles in any other members of her family. There was marked ptosis of both upper lids, the right hanging lower than the left; the levators appeared to have completely lost their power. Rotatory nystagmus existed in both eyes. The patient always fixed with the left eye, the right meanwhile slightly diverging and taking up a lower position. On looking down the left eye moved down well, but the right moved horizontally outwards, reaching eventually the outer canthus. On looking up the left eye returned to its primary central position but could be raised, the right moving in until it reached almost to the central position, but it also could be raised. On looking to the right the left eye rotated fairly well in, and the right fairly well out, but not to such a degree as the left. On looking to the left, the left moved almost to the outer canthus, but the right did not move beyond the middle line. From these facts it was inferred that the inferior obliques were inactive, since in addition to the lack of movement no torsional effect was visible; in the right, complete loss of power of the external muscles supplied by the third nerve, in the left partial loss of power,

and in addition some loss of power in the external recti. Also vertical movement of the left associated with a lateral movement in the right. Pointing out that an attempt at downward movement in the right eye, when the inferior rectus is paralysed, would bring the superior oblique into action alone, and thus account to some extent for the downward and outward displacement, the writer considered, however, that this paralysis was present, but that it was also associated with the action of the external rectus, since only the external rectus could cause such a lateral movement of the eyeball; he considered the lesion giving rise to this could not be a muscular one.

*A Swelling of unusual size, probably Inflammatory, in the Ciliary region.*—Mr. S. Johnson Taylor.

The patient, a man aged 26, presented some ptosis of the left upper lid, and in the upper and outer part of the left ciliary region a broad swelling, firm in consistence, adherent to the globe, pink, and bounded by a fairly sharp ridge. The left fundus showed the retinal veins slightly distended, and a quadrilateral gauzy layer covering the lower part of the disc and its vessels; V. = $^5/_6$ partly; fine opacities in the anterior part of the vitreous. A slight trace of episcleritis had been present on the outer side of the right eye. Treatment with potassium iodide internally, combined with massage over the swelling, seemed to have had a good effect in reducing the size, but it became more painful, particularly at night, and more especially during damp weather.

*An unusual Superficial Circumferential Opacity of the Cornea, symmetrical in the two eyes.*—Mr. E. Teacher Collins.

The patient, a healthy looking man aged 21 years, showed in each eye a superficial, greyish, mottled opacity of the cornea, which involved its whole circumference and extended from the extreme periphery, leaving an oval area a little below the centre of the cornea clear, and of normal transparency. This ring of opacity in each eye was broadest above and bounded the central clear zone by a sharp margin. No blood vessels were to be seen in the opaque part of the cornea, nor in fact anywhere in the cornea. The iris appeared normal in each eye, the media other than the cornea were clear and the fundus was normal. Vision in each = some letters of $^6/_6$.

*An unusual form of Central Choroiditis in a young man.*—Mr. George W. Thompson.

This was apparently partly due to recent hæmorrhage and partly the result of old hæmorrhage.

*Usual change in the Macular Region.*—Mr. G. W. Roll.

In the left fundus, quite close to the macula, was a large pigmented patch, crossed by a few small vessels, and with several hæmorrhages in its neighbourhood; the optic disc was normal. The right fundus was normal. Sudden failure of vision had taken place in March of last year, though previously it had been quite good. Now it was reduced to finger-counting at 3 feet.

*Embolism of Retinal artery.*—Mr. G. W. Roll.

The right fundus of this patient presented a very misty papilla with a milky white retina and a dark-red spot at the macula. The retinal arteries showed absence of blood column and had a silvery-white look, the veins were small in calibre, but contained some blood. A month before his first attendance at the Royal Westminster Ophthalmic Hospital he had become temporarily blind in this eye for a period of ten minutes; this attack, however, had passed off entirely. Two days before he came to the hospital sudden and complete blindness had occurred in this eye.

*Permanent Paralysis of Inferior Recti Muscles following Diphtheria some years previously.*—Dr. D. Mowat.

The patient, a young man, had had diphtheria in 1896, shortly after which he suffered from ophthalmoplegia externa, with some general paralysis. In December, 1898, when examined the vision was R. :$^{6}/_{9}$, L. :$^{6}/_{18}$. Hypermetropia of 1D. There was also paralysis of the left internal rectus and of the left inferior rectus, together with some paresis of the left superior rectus and paralysis of the right inferior rectus. Now the condition was paralysis of both inferior recti muscles, and the vision R. :$^{6}/_{6}$, L. :$^{6}/_{6}$, three letters. Some facial paralysis was present and divergence of the left eye.

*Peculiar Symmetrical Swellings in the Macular Region, apparently due to Sub-retinal Hæmorrhage.*—Mr. Rayner Batten.

This patient, aged 58, showed in the right macular region a triangular swelling with rounded margins, resembling a sub-hyaloid hæmorrhage in colour, but with retinal hæmorrhages, small in size, lying on it. In the left macular region there was a similar swelling rather larger but much paler in colour. There was also extensive thinning of the choroid in both eyes with other choroidal changes. No trace of albumen or sugar was to be made out in the urine. In the right eye vision had failed nine weeks ago, in the left one and a half years ago.

*A Plan of Treatment in some Cases of Asthenopia.*—Mr. G. Brooksbank James.

*A Note upon the Eye Symptoms of Rheumatoid Arthritis, with a Special Reference to the Field of Vision.*—Mr. W. M. Beaumont.

These investigations were carried out mainly in the Royal Mineral Water Hospital at Bath, that so-called "living museum of rheumatoid arthritis." Speaking generally, the eye symptoms in rheumatoid arthritis appear to be suggestive of some disorder of the nervous system. Ephemeral palsies of the external ocular muscles are not uncommon, slight ptosis occurring and disappearing from one eye to recur in the other eyelid. The question naturally occurred to the writer whether to look upon these fleeting palsies as pointing to a nuclear lesion or to some effect of neurasthenia. In many cases, without there being decided hippus, there was frequently greater instability of the iris than is usual in healthy people. The reflexes to light, to accommodation, and to irritation varied in their activity, while the conjunctiva was at times insensitive to the touch of the finger, the cornea also, and to as marked a degree as after the instillation of cocaine in a healthy normal eye. The symptom most usually present was concentric contraction of the field of vision. This contraction of the field of vision in cases of rheumatoid arthritis was illustrated by the writer at a Branch meeting of the British Medical Association in 1902, and at this meeting the objection was raised that the symptom might probably be due to hysteria since it most frequently occurred in female patients. Pointing out that variations from the normal field of vision usually occur in the direction of contraction, and rarely if ever in the direction of enlargement, and that the fields of vision in rheumatoid arthritis resemble those in hysteria, the author suggested that it might be more than a mere coincidence and be even an explanation, since hysteria itself is said by some writers to be a vaso-motor disease, and rheumatoid arthritis is also a disease characterized by vaso-motor phenomena. The charts taken from male patients corresponded very closely with those from females. No central scotomata are found as a general rule in rheumatoid arthritis patients, but the fields conform to the general type of hysteria, neurasthenia, exophthalmic goitre, etc. Colour vision was found to be good, but the colour fields were contracted proportionally to the white. The writer had never seen the blue field inordinately contracted as is said sometimes to be the case in hysteria, but he had seen the red field diminished out of proportion to the green. He did not consider the contraction of the field of vision to be due to atrophy of the optic nerve, for usually no visible pallor of the papilla could be determined and the lamina cribrosa was not unduly visible, the colour sense was unimpaired and blindness did not ensue. Raynaud's phenomenon has been shown to be a common accompaniment of rheumatoid arthritis in which local syncope alternated with local asphyxia, both

evidence of failure at the periphery, hence some failure of the periphery of the retina might be expected, and this actually does happen, as was pointed out by Dr. Samuel Lodge, who drew attention to the fact that in Raynaud's disease contraction of the field of vision actually did take place. Nitrite of amyl had been tried in cases of rheumatoid arthritis, and its administration had been almost invariably followed by an increase of the contracted field of vision.

*Notes of a case of Tuberculosis of the Choroid.*—Mr. J. R. Lunn.

The patient, a girl aged 6, had been admitted to hospital complaining of severe headache and vomiting, with a sore throat and some abdominal distension with pain, but no diarrhœa. Her father had died of phthisis but no history of syphilis could be obtained. The patient was very ill on admission, with a temperature of 101° and a pulse of 112; no squint; no otorrhœa. The pupils were equal, dilated, and acted to light and accommodation. Later she became semi-comatose, then delirious, the temperature varying between 101° and 105°; difficulty in swallowing. Râles were heard over the right lung. Later a sudden offensive bloody discharge came from the left ear. On examining the eyes under atropine double optic neuritis was found to be present, also in the left eye on the temporal side of the disc a large oval whitish area about one-third the size of the disc, over which the retinal vessels passed, and which seemed to be raised and free from pigment except at its lower nasal border, two other patches smaller than the above, situated below and to its outer side were present, all quite unpigmented. These patches were considered to be tubercle of the choroid. Later the child's health improved, the optic neuritis disappeared, one patch cleared up, but the larger oval area remained. In a few weeks she was able to leave the hospital.

*Pulsating Exophthalmos due to Dilatation and Dropsy of the Optic Nerve accompanying internal Hydrocephalus.*—Major Maynard and Dr. Leonard Rogers.

The patient, a Bengali girl aged 15 years, suffered from complete blindness with proptosis of the right eye. The head was large and rounded but not hydrocephalic in appearance; she had had occasional fits, the proptosis dated back some six months and affected the right eye only. There was complete ophthalmoplegia externa and interna; a star-shaped opacity in lens; T. + 1; no fundus reflex obtainable. An ill-defined weak pulsation could be felt deep in the orbit confined to a mass behind the eye. Later, great pain coming on and the cornea sloughing, the eye was enucleated, when it was found that the optic nerve passed into the pulsating mass, its sheath being dilated. Much sero-sanguineous discharge came from the socket, which on being examined was found to

contain sugar but no albumen; its specific gravity was 1003. Death ensued on the fourteenth day after the operation. At the *autopsy*, internal hydrocephalus was found, and the right optic nerve was found to be dilated to 1 inch in its transverse diameter, and half an inch in its vertical; the optic foramen was also much enlarged as well as the optic nerve.

*Two cases of Proptosis associated with extra-orbital Disease of the Sphenoid.*—Mr. W. H. Jessop.

Case I. The patient, a man aged 37, had suffered some 12 months ago from severe headache, which had persisted without any definite localization; 10 months ago, however, the left eye became proptosed, and a swelling became apparent in the left temporal region, with gradual loss of vision. There was a history of syphilis, so the patient had been treated for some 9 weeks with mercury and iodide of potassium, with no beneficial result. His gait became ataxic, a purulent offensive discharge came from both nostrils. With the left eye he was able to count fingers at 12 inches distance; there was no diplopia. The eyeball became very much proptosed, and the lower lid showed marked ectropion. The palpebral conjunctiva was much congested but the cornea remained normal. The tension was also normal. The pupil did not react and was about 4m.m. in diameter. An examination of the fundus showed the optic disc to be pale but without any marked signs of atrophy or of a previous papillitis. Under chloroform a large sequestrum of bone, 2 inches by 1 inch, was removed from the great wing of the sphenoid near the base of the pterygoid process. The result of the operation has been that the patient has completely lost his headache, and the proptosis has very nearly disappeared.

Case II. The patient, a woman, had first complained of very severe neuralgia over the left brow, with gradual loss of vision in the left eye, and signs of retro-bulbar neuritis, followed later by proptosis and swelling in the left temporal fossa. Tumour of the optic nerve had been diagnosed, and it was also thought to be malignant. An extensive operation had been performed, the outer wall of the orbit having been turned back and a vascular tumour found near the base of the pterygoid process and the outer wall of the orbit, involving the bone; this was removed and proved to be an endothelioma. After the operation the patient made a good recovery, the proptosis disappeared, and the neuralgia quite disappeared.

In both these cases the great wing of the sphenoid had been involved outside the orbit. The symptoms in each case were similar, headache, neuralgia, proptosis, absence of diplopia, retro-bulbar neuritis, and the presence of a swelling in the temporal region.

Reginald E. Bickerton

# Bibliography.

## Anatomy and Physiology.

Borschke. "Reduction of visual acuteness by overstimulation." *Zeitschrift für Psychologie*, xxxiv., 1.

Broca and Sulzer. "La sensation lumineuse en fonction du temps pour les lumières colorées." *Journal de Physiologie et de Pathologie Générale*, January, 1904.

Gérard. "Extra-cerebral visual paths." *Journal de l'Anatomie et de la Physiologie*, Jan.–Feb., 1904.

Koch. "The epithelium of the third eyelid in certain mammals." *Archiv für Mikroskopische Anatomie*, lxiii., 2.

Opin. "Marchi's method applied to the optic nerve." *Archives d'Ophtalmologie*, January, 1904.

Ricchi. "Anatomical changes following the introduction of iodoform into the anterior chamber." *Archives d'Ophtalmologie*, Jan., 1904.

de Schweinitz. "Physiology of Sympathetic in relation to the eye." *Journal of American Medical Association*, January 30th, 1904.

Streiff. "The origin of the 'Optikusdrusen.'" *Klin. Monatsbl. für Augenheilk.*, February 1904.

## Congenital Abnormalities.

Hadano. "Congenital Anomaly of the external canthus." *Die Ophthal. Klinik.*, viii., 3.

Motolese. "Congenital ophthalmolegia exterior." *Annali di Ottalmologia*, 1904, 1.

Rogman. "Cyst of orbit and microphthalmos." *Annales d'Oculistique*, January, 1904.

de Schweinitz. "Coloboma of the iris upwards and outwards." *Ophthalmic Record*, January, 1904.

Stanculeanu and Costin. "Coloboma of the lids." *Annales d'Oculistique*, January, 1904.

Zentmayer. "Microphthalmus with orbital cysts." *Annals of Ophthol.*, January, 1904.

## Hygiene.

Dauber. "Prophylaxis of ophthalmia neonatorum." *Münchener Med. Wochenschrift*, February 16th, 1904.

Seggel and Eversbusch. "Illumination in Schools." *Wochenschrift für Theropie und Hygiene des Auges*, vii., 20.

Young. "Visual requirements of enginemen." *Annals of Ophtholmology*, January, 1904.

## Pathology and Bacteriology.

Axenfeld. "Ophthalmia neonatorum and the gonococcus." *Deutsche Medizinische Wochenschrift*, 1904, iv.

de Bernardinis. "Hypopyon ulcer caused by bacterium coli." *Annali di Ottalmologia*, 1904, 1.

Courmont and Nicholas. "Virulence of the aqueous humour in rabbits killed by hydrophobia." *Journal de Physiologie et de Pathologie Générale*, January, 1904.

Marx. "Pathological changes in keratitis from burning." *Virchow's Archiv für Pathologische Anatomie and Physiologie*, xvii., v., 1.

Wood. "Blastomycosis of ocular structures." *Annals of Ophthalmology*, January, 1904.

## Instruments and Apparatus.

Arlt. "A new lamp." *Wochenschrift für Therapie and Hygiene des Auges*, vii., 20.

Doyne. "A device to assist persons who are almost blind." *Ophthalmoscope*, February, 1904.

Fortunati. "Acetylene lamp for ophthalmic work." *Annali di Ottalmologia*, 1904, 1.

Lohnstein. "Apparatus for determination of refraction." *Wochenschrift für Therapie und Hygiene des Auges*, vii., 20.

Remy. "Diploscope." *Recueil d'Ophtalmologie*, December, 1903.

Stretton. "Entropium forceps." *Lancet*, January 30th, 1904.

Vagliasindi del Castello. "The catoptric camera of Flees." *Bollettino del l'Ospedale Oftalmico di Roma*, January, 1904.

## Therapeutics.

Darier. "Dionine." *La Clinique Ophtalmologique*, 1904, ii.

Oliveres. "Benzoate of lithia in treatment of opacities of the cornea." *La Clinique Ophtalmologique*, x., 3.

Ricchi. "Anatomical changes following the introduction of iodoform into the anterior chamber." *Archives d'Ophtalmologie*, January, 1904.

Vacher. "Mercurial Ointment in place of subconjunctival injections." *La Clinique Ophtalmologique*, x., 3.

Zanibruc. "Dionine." *Wochenschrift für Therapie und Hygiene des Auges*, vii., 20.

## Operations.

Basso. "Depression of cataract." *La Clinica Oculistica*, January, 1904.

Calderaro. "Operation for entropion." *La Clinica Oculistico*, January, 1904.

Chandler. "Extraction with button-hole in iris." *Archives of Ophthalmology*, January, 1904.

Deutschmann. "Operative treatment of detachment of retina." *Beitrage zur Augenheilkunde*, 1904, lix.

Rollet. "Blepharoplasty by means of two pedunclated flaps." *Ophthalmoscope*, February, 1904.

## Traumatisms.

Haberkamp. "Blindness of both eyes, caused by a rifle shot." *Archives of Ophthalmology*, January, 1904.

Warschawski. "Injuries of the lens with copper." *Die Ophthalmologische Klinik*, 1904, ii.

## Tumours.

Frank. "Congenital endothelial sarcoma of orbit." *New York Medical Record*, January 9th, 1904.

Frugiuele. "Plexiform neuro-fibroma of orbit." *Annali di Ottalmologia*, 1904, l.

Hirschberg. "Prognosis of malignant tumours of choroid." *Berliner Klinische Wochenschrift*, 1904, iv., v.

Marchetti. "False neuroma of the infraorbital nerve." *Annali di Ottalmologia*, 1904, l.

## Sympathetic Ophthalmia.

Ramsay. "Sympathetic ophthalmia." *Annals of Ophthalmology*, January, 1904.

## Glaucoma.

Cantonnet. "Treatment of glaucoma with osmotic substances." *Archives d'Ophtalmologie*, January, 1904.

Paterson. "Glaucoma and the glaucoma theories." *Medical Press and Circular*, February 17th, 1904.

Stevenson. "Congenital glaucoma." *Liverpool Medico-Chirurgical Journal*, January, 1904.

Stoewer. "Glaucoma with complete atrophy of the iris." *Klin. Monatsh. für Augenheilkunde*, February, 1904.

Truc. "Infantile glaucoma." *Revue generale d'Ophtalmologie*, 1904, l.

Veasey and Shumway. "Simple glaucoma in the Young." *Ophthalmic Record*, January, 1904.

Wilder. "Resection of sympathetic ganglia in glaucoma." *Annals of Ophthalmology*, January, 1904.

## Amblyopia and Visual Defects.

Young. "Visual requirements of enginemen." *Annals of Ophthalmology*, January, 1904.

## Refraction and Optical Questions.

Spengler. "Can corneal astigmatism be inherited?" *Klin. Monatsb. für Augenheilk.*, February, 1904.

## Regional Affections.

### Eyelids.

Calderaro. "Entropion from scleroderma." *La Clinica Oculistica*, January, 1904.

Hadano. "Congenital anomaly of the outer cantbus." *Die Ophthalmologische Klinik*, viii., 3.

Rosenstein. "A mycelium-caused ulcer of the eyelid." *Centralblatt für Augenheilkunde*, January, 1904.

Stanculeanu and Costin. "Coloboma of the lids." *Annales d'Oculistique*, January, 1904.

Werncke. "Pterygium on the upper lid." *Klin. Monatsb. für Augenheilk.*, February, 1904.

Wood. "Blastomycosis of the eyelids." *Annals of Ophthalmology*, January, 1904.

McGillivray. "Congenital lachrymal fistula." *Ophthalmoscope*, Feb., 1904.

### Lachrymal Apparatus.

Roy. "Spontaneous prolapse of both lacrymal glands." *American Journal of the Medical Sciences*, January.

Schulte. "Simple substitute for extirpation of the sac." *Die Ophtholmologische Klinik*, viii., 3.

### Conjunctiva.

Axenfeld. "Ophthalmia neonatorum and the gonococcus." *Deutsche Medizinische Wochenschrift*, 1904, iv.

Burnett. "Circumcorneal hypertrophy (vernal conjunctivitis) in the negro." *American Journal of the Medical Sciences*, February, 1904.

Chaillous. "The infectious conjunctivitis of Parinaud." *Annales d'Oculistique*, January, 1904.

Dauber. "Prophylaxis of blennorrhœa monatorum." *Münchener Medizinische Wochenschrift*, February 16th, 1904.

Ischreyt. "Cyst of Conjunctiva." *Klin. Monatsb. für Augenheilkunde*, February, 1904.

Mori. "Xerosis conjunctivæ and keratomalacia in infants." *Jahrbuch für Kinderheilkunde*, 1904, ix., 2.

Pèchin. "Ophthalmia neonatorum." *Revue d'Hygiène et de Médecine Infantiles*, ii., 5.

Vossins. "Purulent conjunctivitis after diarrhœa." *Die Ophthal. Klinik.*, 1904, ii.

Werncke. "Pterygium on the upper lid." *Klin. Monats. für Augenheilkunde*, February, 1904.

### Cornea and Sclerotic.

Bardelli. "Filamentous keratitis." *Annali di Ottalmologia*, 1904, i., 2.

de Bernardinis. "Hypopyon ulcer caused by bacterium coli." *Annali di Ottolmologia*, 1904, i.

Fehr. "Peculiar degeneration of the cornea." *Centralblatt für Augenheilkunde*, January, 1904.

Fox. "Conical cornea." *Ophthalmic Record*, January, 1904.

Oliveres. "Benzoate of lithia in treatment of opacities of the cornea." *La Clinique Ophtalmologique*, x., 3.

Rollet. "Keratitis due to hereditary syphilis." *Revue Générale d'Ophtalmologie*, 1904, i.

Scalinci. "Keratoconus treated by the cautery." *Annali di Ottalmologia*, 1904, i.

Schulte. "Serpiginous ulcer of cornea." *La Clinique Ophtalmologique*, 1904, ii.

Yamaguchi. "Melanosis corneæ." *Klin. Manats. für Augenheilk.*, February, 1904.

### Iris and Ciliary Body.

Francois-Franck. "Influence of the ciliary nerves on the iris." *La Clinique Ophtalmologique*, 1904, ii.

Koster. "Filtration through iris, etc." *Archives of Ophthalmology*, January, 1904.

Laquer. "Pupillary movements." *Archives of Ophthalmology*, January, 1904.

Pollock. "Tubercular iritis." *Glasgow Medical Journal*, February, 1904.

de Schweinitz. "Coloboma of the iris upwards and outwards." *Ophthalmic Record*, January, 1904.

Stoewer. "Atrophy of the iris in glaucoma." *Klin. Monatsb. für Augenheilkunde*, February, 1904.

Weiss and Klingelhoffer. "Ruptures of the iris." *Archives of Ophthalmology*, January, 1904.

### Lens.

de Schweinitz. "Dislocation of lenses through the pupil." *Ophthalmic Record*, January, 1904.

de Schweinitz. "Lenticonus posterior." *Ophthalmic Record*, January, 1904.

Warschawski. "Injuries of the lens with copper." *Die Ophthalmologische Klinik*, 1904, 2.

### Choroid and Vitreous.

Hirschberg. "Prognosis in malignant tumours of the choroid." *Berliner Klinische Wochenschrift*, 1904, iv., v.

### Retina.

Bull. "Arteriosclerosis and lesions of the retina and nerve." *Annals of Ophthalmology*, January, 1904.

Deutschmann. "Operative treatment of detachment of retina." *Beiträge für Augenheilkunde*, 1904, lix.

Opin and Rochou-Duvigneaud. "Pathology of albuminuric retinitis." *Journal de Physiologie et de Pathologie Générale*, January, 1904.

Nicati. "Restoration of a detached retina and spontaneous absorption of cataract." *La Clinique Ophtalmologique*, x., 3.

Pergens. "Retina and disc (historical sketch)." *Klin. Monatsb. für Augenheilkunde*, February, 1904.

### Optic Nerve.

Carpenter. "Optic neuritis in enteric fever." *Ophthalmoscope*, February, 1904.

### Muscles (and Strabismus).

Boureau. "Trephining over the visual centre for ophthalmoplegia." *La Clinique Ophtalmologique*, 1904, ii.

Grossmann. "Paralysis of both third nerves." *Liverpool Medico-Chirurgical Journal*, January, 1904.

Motolese. "Congenital ophthalmoplegia exterior." *Annali di Ottalmologia*, 1904, i.

### Orbit.

Collins. "Injuries and diseases of the orbit." *Clinical Journal*, Feb. 3, 1904.

Colucci. "Echinococcus cyst of orbit." *Annali di Ottalmologia*, 1904, i.

Fox. "Sarcoma of orbit cured by X-rays." *Archives of Ophthalmology*, 1904.

Frank. "Congenital endothelial sarcoma of orbit." *New York Medical Record*, January 9th, 1904.

Frugiuele. "Plexiform neuro-fibroma of orbit." *Annali di Ottalmologia*, 1904, i.

Grnening. "Orbital cellulitis." *New York Medical Record*, February 6, 1904.

Peschel. "Retraction of the eye." *Centralblatt für Augenheilkunde*, January, 1904.

Rogman. "Cyst of orbit and microphthalmos." *Annales d'Oculistique*, January, 1904.

Stadfelt. "Cephalocele of the orbit." *Nordisches Medizinisches Archiv*, 1903. iii., 11.

## Relations with Medicine.

Bull. "Arteriosclerosis and lesions of the retina and nerve." *Annals of Ophthalmology*, January, 1904.

Carpenter. "Optic neuritis in enteric fever." *Ophthalmoscope*, February, 1904.

Finlay. "Delirium after eye operations." *Archives of Ophthalmology*, January, 1904.

Galezowski. "Ocular syphilis." *Le Progrès Médical*, January 30th, 1904.

Gamble. "Visual disturbances in brain injuries." *Journal of American Medical Association*, January 23rd, 1904.

Gould. "History and etiology of migraine." *Journal of American Medical Association*, January 16 and 23, 1904.

Hirschberg. "Amaurotic idiocy." *Centralblatt für Augenheilkunde*, January, 1904.

Onfray. "Metastatic ophthalmia from cancer of œsophagus." *Archives d'Ophtolmologie*, January, 1904.

Puccioni. "Ocular tuberculosis." *Bollettino dell' Ospedale Oftalmico di Roma*, January, 1904.

Vossius. "Purulent conjunctivitis after diarrhœa." *Die Ophthalmologische Klinik*, 1904, ii.

Woodward. "Ocular complications of mumps." *New York Medicol Journal*, January 2nd, 1904.

## Miscellaneous.

Allport. "Relationship between the ophthalmologist and the general hospital." *American Medicine*, January 30th, 1904.

Delzoppo and Soli. "Abortion caused by an ocular lesion." *Annali di Ottalmologia*, 1904, i.

Hansell. "Hallucinations of vision." *American Medicine*, January 16.

Knapp. "Biography of Helmholtz." *Archives of Ophthalmology*, January, 1904.

Lobsien. "The knowledge of colour on the part of children." *Zeitschrift für Psychologie*, xxxiv., 1.

de Schweinitz, Ball and Weeks. "Influence of the sympathetic upon the eye." *Journal of American Medical Association*, January, 1904.

Stevenson. "Influence of the semi-circular canals on the movements of the eyes and head." *Liverpool Medico-Chirurgical Journal*, January, 1904.

Truc, Delord and Chavernac. "The ocular stigmata of criminality." *Annales d'Oculistique*, January, 1904.

Wise. "Poisoning from atropine eye drops." *British Medical Journal*, January 23rd, 1904.

# THE MECHANISM OF ACCOMMODATION.

By M. Tscherning, M.D.

The *Ophthalmic Review* of January, 1904, contains a paper on the mechanism of accommodation in man read by Dr. Karl Grossmann before the Section of Ophthalmology of the British Medical Association. Dr. Grossmann has had the rare opportunity of studying the eyes of a patient affected with complete congenital aniridia of both eyes, and has been able to make a series of important observations on the changes which occur during the act of accommodation.

It appears to me, from Dr. Grossmann's remarks, that he is unacquainted with the latest work on the accommodation done at my laboratory at the Sorbonne, work which might easily have escaped his notice, for the account of it was published by one of my students in a journal[1] rarely read by ophthalmologists.

It is important, therefore, to give a brief résumé of this recent work: We determined the thickness of the crystalline lens and measured the curvature of its surfaces at different places, not only when the eye was in repose but also when it was making a considerable effort of accommodation.

The following table shows the results we obtained in four cases:—

| Name of Patient | Dr. Cro·ini, aged 28 yrs. | | Louis D., aged 15 yrs. | | Henri T., aged 11 yrs. | | Miss M., aged 24 yrs. | |
|---|---|---|---|---|---|---|---|---|
| Degree of accommodation .. | 0.3D | 7D | 0D | 8D | 0D | 8D | 0D | 4D |
| | mm. | mm. | mm. | mm. | mm. | mm. | mm. | mm. |
| Radius of curvature of the anterior surface of the lens — at the centre .... | 10.4 | 6.3 | 11.3 | 6.6 | 11.5 | 6.6 | 9.6 | 7.0 |
| Radius of curvature of the anterior surface of the lens — at 3 mm. from the axis .... | 18.0 | 25.9 | 14.9 | 15.5 | 13.8 | 18.5 | 12.9 | 17.8 |
| Radius of curvature of the post. surface at the centre.. | 6.3 | 5.2 | 5.2 | 4.3 | 5.6 | 4.5 | 5.1 | 4.3 |
| Distance of the cornea — from the anterior surface.. | 3.6 | 3.3 | 4.0 | 3.6 | 3.9 | 3.5 | 3.9 | 3.6 |
| Distance of the cornea — from the posterior surface.. | 6.9 | 6.8 | 7.0 | 7.2 | 7.0 | 7.1 | 6.8 | 7.0 |
| Thickness of the lens ..... | 3.3 | 3.5 | 3.0 | 3.6 | 3.1 | 3.6 | 2.9 | 3.4 |
| Accommodation produced by — the ant. surface.. | 4.5D | | 4.6D | | 4.8D | | | |
| Accommodation produced by — the post. surface .. | 2.5D | | 2.6D | | 3.1D | | | |
| Equivalent in dioptries of the change in the anterior surface — at the centre .... | 4.5D | | 4.6D | | 4.8D | | | |
| Equivalent in dioptries of the change in the anterior surface — at 3 mm. from the axis .... | 1.4D | | 2.4D | | 1.2D | | | |

(1). Ed. Besio, "La forme du cristallin humain." *Journal de Physiologie et de Pathologie Générale.* Juillet et Septembre, 1901.

From these figures we have drawn the following conclusions:-

1. The change in the anterior surface of the lens produces about six-tenths of the accommodation; the change in the posterior surface four-tenths.

2. The lens increases in thickness during accommodation; the anterior surface moved forward in all our cases, while the posterior surface moved a little backward, except in the first case, where it seemed rather to move slightly forward.[2]

3. The anterior surface becomes flattened towards the periphery. This flattening, already manifest in the state of rest, becomes strongly marked during accommodation, while at the same time the curvature in the middle increases.

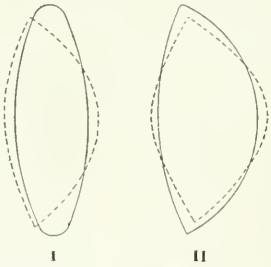


FIG. 1. Form of the lens in a state of rest ( ), and during an accommodation of 8D. (- - - -). I. After the measurements of Besio. II. After Grossmann.

4. By comparing, in dioptries, the refractive value of the changes in the anterior surface of the lens, we find a difference of about three dioptries between the central and the peripheral parts. In addition to this, on examining the eye by skiascopy or otherwise, we find a difference of five or six dioptries between the central and peripheral accommodation; from which we may infer that the posterior surface of the lens must also become flattened towards the periphery during accommodation.

Fig. I represents the shape of the lens in a state of

(2). In this respect individual differences appear to exist. In a case which I examined some years ago, the anterior surface did not move, but the posterior surface moved backward. Such a difference may be accounted for by a slight displacement of the lens forward, which, in fact, occurs in most eyes.

rest and during an accommodation of eight dioptries as shown by our measurements in the right eye of Louis D. By comparing this drawing with that of Dr. Grossmann (Fig. 1, II.) it will be observed that the only appreciable difference is due to the fact that this author has exaggerated the backward movement of the peripheral parts of the anterior surface. In other respects they are quite in accord, and I may add that Besio's measurements also make it quite certain that the diameter of the lens must diminish during accommodation, for the increase of thickness is too great to be explained solely by the flattening of the surfaces at the periphery.

Dr. Grossmann's work is nevertheless very important inasmuch as he has, by direct observations, established the three facts of which in future there should be no doubt, namely, that during accommodation the lens increases in thickness, diminishes in width, and becomes flatter in the peripheral parts of its posterior surface.

Although the change of curvature at the anterior pole is much greater than that at the posterior pole, my Fig. 1, I. shows that the change in the posterior surface, taken as a whole, is much more considerable than that at the anterior surface, and Dr. Grossmann's Fig. 1, II. seems to indicate this also. We shall see that an analogous difference exists in the mobility of the two extremities of the ciliary muscle.

Now that we have precise information as to the form of the lens in accommodation, it is more easy to imagine the mechanism by which its change in form may be brought about. I may be allowed here to give a short statement of my views concerning this mechanism.

There can be no doubt that accommodation is due to a contraction of the ciliary muscle, for there are no other muscles in the interior of the eye, excepting those of the iris—which have no rôle in accommodations. As to the action of the ciliary muscle Helmholtz makes the following statement ("Physiol. Optik.," 2nd edition, p. 23):—"Bruecke, der den Muskel entdeckte, nahm an, dass er die Aderhaut (und die mit dieser an der ora serrata engverbundene Netzhaut und Glashaut) um den Glaskoer. per anspanne, Donders dagegen dass die Aderhaut sein fester Ansatzpunkt sei, und er im Gegentheil den elastischen Theil der inneren Wand des Schlemmschen

Kanals verlangere und so den Ansatz der Iris nach hinten rücke. In Wahrheit verbinden sich beide Wirkungen mit einander."

There cannot be much doubt that contraction of the ciliary muscle is followed by the effects here described by Helmholtz, for we see the peripheral part of the posterior wall of the chamber move backwards slightly during accommodation, at the place which corresponds to the anterior extremity of the muscle, and, in addition to this, Hensen and Voelkers have shown that the posterior extremity of the muscle moved forwards during accommodation. In their experiments (on dogs) the equatorial part of the choroid was drawn forward about one-half of a millimetre, and it follows that the posterior extremity of the muscle must move forwards or rather inwards (see Fig. 3) an equivalent distance.

But I have never been able to understand how Helmholtz, holding the above mentioned opinions as to the effect of the contraction of the muscle, could imagine that this contraction could produce a relaxation of the zonula (the fibres, I mean, which pass to the anterior surface of the lens). We should distinguish between the *free part* of the zonula, which passes from the lens to the ciliary body to be inserted a little behind the summits of the ciliary processes, and the *adherent part*, which is continued on to the *ora serrata*. The latter part of the zonula adheres on the one side to the ciliary body and on the other to the vitreous body in such wise that they cannot be separated without tearing. The place of the insertion of the free zonula is found to be well in front on the ciliary body, nearly on a level with the insertion of the muscle in the wall of Schlemm's canal.

Now, as the fibres of the zonula which pass to the anterior surface of the lens take a direction almost parallel to that of the muscle, it is obvious they must become tense when the muscle contracts, while the fibres which go to the posterior surface will be relaxed.[3] I have shown

(3). According to recent authors there is a certain interlacing of the zonular fibres, those which pass to the posterior surface of the lens being inserted more in front of the ciliary body in the neighbourhood of the so-called sphincter of Muller. If the fibres of Muller really exist, their contraction ought to produce a relaxation of the fibres of the zonula going to the posterior surface of the lens. Perhaps they may also account for the slight movement of the summits of the ciliary processes towards the axis of the eye, which has been observed by Coccius and Grossmann. These summits, as we have seen, are to be found in the posterior chamber of the eye. The zonular fibres appear to be inserted, not on the ciliary processes, but in the depressions which separate them.

that traction made on the zonula of the dead lens produces a deformation of its anterior surface, analogous to that which we observe during accommodation, the curvature increasing in the middle and lessening towards the edges. This phenomenon, which is due to the greater resistance of the central parts of the lens, has been verified by Dr. Czellitzer at the Heidelberg Laboratory.

There can, then, be no difficulty in understanding the mechanism of the changes in the anterior surface of the lens; but how shall we explain the changes observed in the posterior surface?

I may here remark that my theory of the mechanism of accommodation meets with a certain opposition, by reason of the great authority of Helmholtz and because of certain false notions, which still exist among medical men, concerning the physical properties of the vitreous body. It is admitted by all observers that the vitreous body has the consistency of jelly; but many reason about it, as if it were a liquid. We must not judge of the vitreous body from the conditions formed in an eye examined some time after death, or from observations made during an operation for cataract. The consistency of the vitreous diminishes with age, thus we find it much denser in the calf than in the cow. It is difficult to obtain quite fresh human eyes; but if we examine the eye of a young animal we find that the vitreous has a dense consistency, more dense certainly than that of the cortical masses of the cristalline lens. It is also to be remarked that the vitreous body is everywhere adherent to the hyaloid membrane. Dr. Grossmann expresses doubt as to this, at least in so far as concerns the posterior capsule of the lens, but the fact is easily verified. The following experiment is conclusive:—In the fresh eye of a young animal (a calf), after removing the cornea and the iris, if we compress the eye, the lens and vitreous body are pressed out together in a single mass; we cannot separate them without tearing the vitreous body. The lens is surrounded by the adherent part of the zonula. Pigmentary fragments are often found adhering to this membrane, a sign of the intimate adhesion which here exists between the vitreous and the membranes of the eye. Here and there may be found, on the zonula, the whole of the pigmentary layer of the ciliary body.

In another experiment we may dissect off the posterior half of the eye, as I have often done to measure the posterior surface of the lens *in situ;* we will then observe how difficult it is to raise the vitreous humour from the ciliary body and from the lens. The adhesion between the ciliary body and the vitreous is so intimate that we might almost say that the ciliary muscle is inserted posteriorly on the vitreous body, and this is true not only of the radiating fibres but also of the longitudinal fibres, by reason of the elasticity of the choroid.

In consequence of the contraction of the ciliary muscle the peripheral anterior parts of the vitreous body will therefore be drawn forward towards the lens. If we bear in mind that the zonula is attached not to the very edge of the lens but to parts on the anterior surface, a little within the edge, it will not be difficult to understand why the diameter of the lens diminishes during accommodation. It is for the same reason that the posterior surface becomes flattened towards the edges; the peripheral parts of the lens are compressed between the anterior capsule drawn backwards in consequence of the traction on the zonula, and the posterior capsule pushed forwards by the vitreous body. We understand also why under these circumstances there is a protrusion at the posterior pole of the lens, where the vitreous humour is not drawn forward and where its resistance is farther diminished by the presence of Cloquet's canal. It is probable that in most cases the lens is pushed a little forward, but that this displacement is corrected or overcorrected in so far as the posterior surface is concerned, by the protrusion of the posterior pole, in such manner that the posterior surface, in the middle, remains in its place or moves backward a little, while the anterior surface moves forward. The advancement of the lens stretches the anterior zonula, so that we are not obliged to admit that the anterior insertion of the ciliary muscle moves backward. If I have, nevertheless, admitted a slight backward movement of the anterior insertion, it is because we see such a movement at the angle of the anterior chamber, and because I have observed cases in which there was little or no advancement of the anterior surface.

I believe that this way of explaining the mechanism of accommodation may replace with advantage the more

or less mystical notions concerning the nature of the elasticity of the lens with which we have been satisfied up to the present time. But there is still another series of phenomena to be observed when the accommodation is exerted to its maximum, which may, I think, furnish a direct proof that I am right in admitting the action of the ciliary muscle on the vitreous body as the second factor in the mechanism of accommodation, besides the traction exerted on the anterior zonula.

In the first place there is the so-called descent of the lens towards the end of the accommodation. I have found that the image reflected by the posterior surface descends a little when the accommodation reaches its maximum. Sometimes the image of the anterior surface descends also at the same time, but its displacement is much less than that of the image of the posterior surface, and there are persons in whom no such displacement of the image of the anterior surface is to be observed. Observation by oblique illumination and by the entoptic method shows that the lens substance is really displaced a little in a downward direction. Professor Hess has recently shown that this displacement occurs under the influence of weight; it takes place towards the temple or towards the nose, when the head is inclined towards one shoulder or the other.

This phenomenon seemed to me inexplicable by the theory of Helmholtz. It is the more curious that together with another phenomenon, to which I shall presently refer, it forms at the present time the very foundation of the hypothesis of Helmholtz. The reasons which Helmholtz himself gave in support of his ideas no longer exist; it is sufficiently proved, at least in my opinion, that the shape of the dead lens bears no resemblance to that of the lens during the accommodation, but it is said that the observation in question proves that the zonula is relaxed, and that in consequence the theory of Helmholtz must still be right. One seems to imagine the lens to be suspended between two liquids, and to fall lower towards the end of accommodation in consequence of the relaxation of the zonula. Nothing can be farther from the truth than such a conception. The lens and the vitreous body form two gelatinous masses which are united together and one cannot be displaced without the other. It is true

that the phenomenon *might* indicate a displacement of the entire lens. As the image of the posterior surface is much displaced, and that of the anterior surface displaced not at all or very little, the descent of the lens must take place not downwards but downwards and backwards, the superior parts moving a little forwards, somewhat as I have drawn it (Fig. 2, I.).

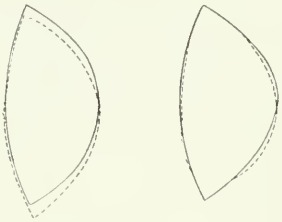


Fig. 2.

According to the observation of Hess, of which there can be no doubt, this displacement occurs under the influence of weight, and, as I have shown in the foregoing remarks, the vitreous body must partake in the movement. I do not see how a relaxation of the zonula would produce such an effect.

But the phenomenon is also capable of another explanation. The substance of the crystalline lens is, in fact, free in its capsule, and the phenomenon can be quite as well explained if we admit that the crystalline substance is displaced a little downwards by reason of the relaxation of the posterior capsule. The phenomenon would thus indicate not a displacement but a deformation of the lens as shown in my drawing (Fig. 2, II.).

Another phenomenon of the same order is the trembling of the little image and also of the lenticular mass observed in consequence of the movement of the eye after an instillation of eserine. It is, in general, not to be seen during the physiological act of accommodation, it may be because the patient relaxes his accommodation a little when he changes the direction of his glance, or it may be

that we have here to do with some special effect of eserine; we might, for instance, imagine that a very prolonged accommodative effort would be required to produce the effect in question.

It has been said that the lens trembles in consequence of the relaxation of the zonula, admitted by Helmholtz, but I do not believe that anyone has seen the image of the anterior surface tremble; I think also that most clinicians will agree with me that generally no trembling is to be observed in cases of subluxation of the lens. My own opinion on this phenomenon is that it depends, like the preceding one, on the relaxation of the posterior capsule.

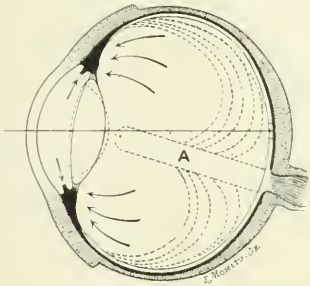


FIG. [illegible] Section of an eye showing the lens at rest ( ), and also in accommodation (- - -). The arrows show the directions of the traction. A, Cloquet's canal.

But there is an inference which seems to me to force itself upon us by reason of these observations, an inference which will seem perhaps surprising, namely, that the central parts of the vitreous body become liquid when the accommodation reaches its maximum. I do not believe it possible to give any other satisfactory explanation of the trembling of the little lenticular image. We can also readily understand the slight deformation of the lens under the influence of weight at the moment when there is nothing more to keep the protrusion at the posterior pole in its place.

In what way can this change be brought about? Unhappily our knowledge of the structure of the vitreous

body is far from perfect. Anatomists appear to be agreed as to the existence of Cloquet's canal (Fig. 3, A.), which is said to be about two millimetres in width and to traverse the vitreous body from the papilla to the posterior pole of the lens. Certain observers distinguish between a cortical portion and a nucleus (Fig. 3). The cortical portion which is said to fill the posterior half of the globe is composed of concentric layers, while the nucleus, the only part in contact with the ciliary body and the lens, is said to be traversed by septa passing from the ciliary body to the central canal. We must not, however, consider these septa as membranes; they are comparable rather to the network of a sponge.

It appears to me probable that during accommodation the ciliary muscle draws upon the nucleus or rather upon the network of the nucleus and thus produces a dilatation of Cloquet's canal together with the change in the posterior surface of the lens. It may be said also that certain other facts observed by anatomists seem here to find their explanation. I may mention the radiating fibres of the ciliary muscle, which terminate by forming loops in front of the vitreous humour. The function of these fibres has not been explained up to the present time, but their direction shows that they must necessarily exercise such a traction as I have supposed. Anatomists have also noted, as it seems with a certain astonishment, that the fibres of the zonula lose themselves, at least in part, in the vitreous body.

---

## TENTH INTERNATIONAL CONGRESS OF OPHTHALMOLOGY IN LUCERNE.

We have received a second circular from the Executive, announcing an alteration in the date of meeting.

The official reception of members will now take place in the evening of September 13th; the mornings and afternoons of the 14th, 15th and 16th will be devoted to scientific work, and on the 17th an excursion will bring the Congress to a close.

Only those papers will have the right to be discussed, which shall have been printed and sent beforehand to all the members of the Congress. Any Manuscripts must be in the hands of Prof. Mellinger, Bâle, before 1st May at latest.

This first part of the Proceedings of the Congress containing these

works will be sent to the Members at the same time as their tickets for the *subscription* (25 francs).

Any object of interest to oculists, either practical or historical (instruments, books, illustrations, appliances, etc.) will be gladly received for the Exhibition attached to the Congress, and should be announced before July 1st to Prof. Siegrist, Berne.

Those colleagues wishing to secure accommodation at Lucerne beforehand are advised to apply before the 1st of September to Dr. F. Stocker, president of the local Committee at Lucerne. He will engage for them a room at one of the best hotels (early breakfast included) at five francs a day each person.

The town of Lucerne is treating the Congress most liberally; throwing open all objects of interest and arranging fêtes of all descriptions, and the mountain railway companies and steamboats have promised a considerable reduction in their fares.

Prof. Siegrist has been appointed to take the place of Prof. Pflüger, who has died since the previous circular was issued; and Dr. E. Landolt, of Paris, has been elected Vice-President.

Full information regarding the Congress can be obtained from

Walter H. Jessop, M.B., 73, Harley Street, London.

George Mackay, M.D., 20, Drumsheugh Gardens, Edinburgh.

Henry R. Swanzy, M.B., 23, Merrion Square, Dublin.

Dr. de Schweinitz, 1,401, Locust Street, Philadelphia, U.S.A.

Dr. Coote, Quebec, Canada.

Dr. Alfred Osborne, Alexandria, Egypt.

---

## REVIEWS.

Cirincione (Genoa) and Calderaro (Sienna). **Chloroma.** *La Clinica Oculistica*, Sept.-Nov., 1903.

Chloroma may be defined as a malignant neoplasm of a more or less intense greenish colour; it is multiple, and almost invariably affects the head in whatever other situations it may occur also; it usually forms more or less flattened masses. So rare is the disease that several good treatises on pathological anatomy do not so much as mention it. Of the sixteen cases which the authors say is all they have been able to discover in literature, several are perhaps a little doubtful in that no proper anatomical examination was conducted. It is a disease which ought specially to interest ophthalmic surgeons since in only two of the recorded cases had the growth failed to involve the orbit, and in several instances the occurrence there was the first untoward symptom.

The authors first give a résumé of the previous cases down to 1902, which are recorded by Burns, Mackenzie, King, Aran, Hillier, Huber, Waldstein, Dressler, Behring and Wicherkiewicz, Chiari, Gade, Recklinghausen, Dock, Horing, Paviot and Gaulois, Schmidt, Horner, Ayres and Rivel. On two points there is serious difference of opinion, for (1) the tissue is described by Virchow and some others as resembling a small-celled sarcoma, while others again describe it as a lymphoma in a leucocythæmic or pseudo-leucocythæmic condition; and again (2) the true source of the green colouration is matter of dispute. The authors' case may briefly be described thus:—

A.B., a boy, aged 15, was not able to give any satisfactory account of the origin and development of his illness during the time when he was under the authors' care, which was only at the very close of his life; but from the physician who had previously attended him they learned that the disease had apparently begun some three and a half months before, the initial symptom having been pain all over the left leg and thigh, especially about the trochanter and the popliteal space; the pain was continuous, but was not worse at night; the temperature had not risen. In a few days the seat of pain changed to the left temporal fossa, and hearing became lost on that side. At this time the left eye began to protrude, and he was brought under the care of the authors. The boy was then very pallid, but the heart, etc., seemed normal; there was no goitre, and the only definite indication appeared to be the exophthalmos on the left side. The left eye protruded "like a large lemon," the upper eyelid being greatly stretched; the cornea was clear, though anæsthetic at its lower part, and the iris acted both to light and to accommodation. On palpation a firm elastic mass could be made out in the orbit; the edge at the upper part of the orbit, where it could best be felt, was rounded and roughly granular; the globe could not be pushed back into the orbit, there was no pulsation or murmur, and no local increase of temperature. In most directions, owing to the interference with ocular movements, there was diplopia. The arteries in the fundus were normal in size, and the disc margins quite clear and sharp, but the veins were greatly distended and tortuous. In five days it was evident that the proptosis was increasing with fearful rapidity, the neoplasm itself was now outside the limits of the orbit, and the cornea was beginning to suffer. The patient at this time complained of severe pain in the head—a symptom which had not previously

been present extending also down the neck, where there was some swelling, probably glandular. The right eye, which had hitherto been quite normal, now was seen to be proptosed also, and on thrusting the finger into the orbit a flattish knobby mass similar to that on the opposite side could be distinctly felt. The ophthalmoscope showed distension and varicosity of these veins also. Three days later the left eye was quite blind; there were traces of albumin in the urine, though it contained no abnormal pigments or blood-pigments. The blood showed increase of white corpuscles and slight diminution of the red, and a number (about 1 to every 200 r.b.c) of polynucleated leucocytes. Next day the temperature began to rise, and there were rigors; the condition of the right eye became distinctly worse. In the hope rather than the expectation that there might be a collection of pus in the orbit, an exploratory puncture was made, but no pus was found; however, after 24 hours there was certainly less exophthalmos on both sides, and the globes were more mobile. In a very short time the exophthalmos went down, and the finger could detect any neoplasm only when pushed far into the orbit; this improvement had followed the copious discharge of a sero-sanguineous fluid from the left orbit. The same evening, however, the patient became delirious, and his temperature went up higher; he died on the 18th day after his admission under the care of the authors.

There is a very long report of the *autopsy*, from which we extract the following points:—The left inferior petrosal sinus was thickened and contained a flat greenish purulent mass, and the right was similarly affected. There were fifteen such patches also on the inner surface of the cranium, their colour being a dirty yellow, and the walls were eroded in parts. The longitudinal sinus was also affected similarly to the petrosal. The neoplasm found in the orbits had a firm, almost cartilaginous feeling; it was smooth and bloodless, and appeared to be limited to the parts outside the cone of muscles. No trace of the lachrymal gland could be found in the left orbit, but in the right it was discovered adhering to the tumour. There was an uninterrupted chain of enlarged glands from the pre-auricular down the neck; these glands were soft, elastic, and greyish. Even in the thyroid cartilage there was a tiny nodule of new growth, and near the temporo-maxillary articulation were a number of purulent areas, each the size of a cherry-stone, scattered through the muscular substance. Into

the other very interesting details of the condition of the thoracic and other organs it is not necessary to enter here, but it ought to be mentioned that foci existed in the muscles of the thigh similar to those in the temporal muscle; in the elbows too and in the soft parts of the left arm were foci of pus. A large growth was found affecting the sacrum and extending into the pelvis, implicating the rectum; it also was of a yellowish colour with a strong infusion of green.

In the fresh scrapings of the tumour three kinds of elements were found; long cells with fine transparent prolongations (fibro-cellular), large many-sided cells with round nuclei and semi-transparent protoplasm, and small rounded cells like leucocytes. A point which impressed itself upon the authors as being unusual was the singularly great elasticity and resisting power of the sections made after embedding in paraffin, a fact which gave facilities for the making of peculiarly large and fine sections. The fundamental tissue of the growth was fibrillar and transparent, not abundant, interlacing in every direction, allowing the formation in its meshes of small masses of cells. Some of these, and the most numerous of them, were large with a large fusiform nucleus, others were polyhedral with a round nucleus; the nucleus took on a stain deeply, but the protoplasm remained perfectly pure. Where the tissue was adherent to bone the fibrillar element was more copious, but in the more peripheral parts of the tumour the cellular elements prevailed. Besides numerous other matters, the authors note that the capillaries were very numerous indeed wherever the tumour was growing, the larger vessels being apparently formed of tumour tissue lined with endothelium, the capillaries having a double layer of endothelium and having a lumen in parts barely sufficient for the passage of a red blood-corpuscle; many indeed were quite blocked. It has sometimes been maintained that the lachrymal gland is the seat of origin of the tumour, but in this case the indications were to the contrary, for on one side the tumour was quite free from the gland, though on the other the gland was embedded in the growth. The bloody oozing from the orbit was explained by the fact of the complete closure of the ophthalmic vein by the neoplasm. It was only in the front part of the tumour that there was any real indication of true invasion of the orbital tissues, but here little islets of the neoplasm tissue were observed in advance of the main body scattered among the interstices even of the subcutaneous tissue. These consisted of small cells, not united

into bundles but intersecting in a somewhat regular fashion, and to a certain extent resembling adenoid tissue. The authors considered that the indications were that the round cells of the neoplasm were an undeveloped form of the longer fibrous cells, which were the "adult" tissue. The tumours ended abruptly at the apex of each orbit, and did not pass into the cranial cavity.

A question which greatly exercised the attention of the authors was the source of the peculiar pigmenting material; was it derived from blood or from bile? A small piece of the tumour immersed in distilled water began to part with its pigment in about three hours, and after 18 hours it was of a greyish-white hue. The water in which it had been soaking did not, however, present any colouration, nor did it show any absorption bands when examined with the spectroscope. Sulphate of ammonium added to it in solution did not bring about any modification. From these facts it was concluded that the colouring matter was not derived from the blood. Another similar piece of tumour tissue was immersed in chloroform and in about one hour had lost all colour, while the chloroform had acquired a faint greenish tinge which it retained for about six hours. The absence of urobilin was considered proved by the fact that no fluorescence occurred when to a portion of this chloroform containing the colouring material absolute alcohol alkalinised with ammonia was added, and then an alcoholic solution of chloride of zinc. On the addition of the ammonia the colour of the chloroform became more definitely green. Again spectroscopic examination was negative. It appeared certain then that no biliary pigment could be present, a conclusion in which the authors are in agreement with Gmelin, Maréchal and Huppert.

Histological examination with various colouring reagents, and in extremely fine sections embedded in a variety of media, totally failed to bring to light any substance, either intra-cellular or extra-cellular, either granular or homogeneous, to which the green tint could be attributed. The reaction with osmic acid, it is true, showed here and there the presence of granules in the cellular protoplasm, but not to any greater degree than is frequent in sections of ordinary sarcomata. A point to which special attention is drawn is that in the part particularly in which the green colour was most intense, namely, in the sacral tumour, there were numerous foci of microbes in colony, and the question presented itself—can these be the

cause, direct or indirect, of the green tinting? It is quite true that the region itself was not coloured green, and the injection into a guinea-pig of a culture taken from those areas was not followed by the development of any tint, yet it is quite possible that where the soil is different from usual the organism may take on a different habit. As the authors admit, this is nothing more than a hypothesis, but there are some analogous circumstances; there are other chromogenic bacteria which behave differently in this respect according to the soil on which they may happen to grow. The theories of Virchow and others that the colour is due to fatty granules in the cellular protoplasm, and of Lubarsch and others that it is due to a transformation of old hæmorrhagic foci, the authors believe they have succeeded in subverting, for the reasons briefly sketched above. They consider, further, that chloroma has no claim to a special place among tumours, its essential features not being peculiar to itself, and its prominent clinical character, the green colour, being really an extraneous matter altogether, and probably due to the action of "accidental" bacteria flourishing in the neoplasmic tissue.

W. G. S

---

Elschnig (Vienna). **The Light-Reflex on the Retinal Arteries of the Human Eye.** *Klinische Monatsblätter für Augenheilkunde.* Vol. xlii., p. 37.

The explanation of the light-reflex on the retinal vessels has been ever since its first discovery a subject of interest to ophthalmologists. The discoverer, Jaeger, attributed it at first to the reflection from the vascular walls, though he subsequently changed this theory for that which regards it as due to the blood column itself. Jaeger's original theory was pretty generally held in the ophthalmological world till 1891, when Dimmer brought forward another, which, while accepting Jaeger's second theory with respect to the veins (viz., that the reflex came from the actual blood column), attributed the arterial reflex to the axial stream, and not to the surface of the blood column. It seems hard to believe that the reflex from the arteries should have a cause quite other than that from the veins, and we doubt whether Dimmer's views are as generally accepted as is stated by Elschnig. Be that as it may, Elschnig now brings forward observations

which he thinks completely disprove Dimmer's theory with respect to the arterial reflex.

It is known since Jaeger's time that if one, when inspecting the retina with the erect image, exert pressure on the globe, the vessels on the disc become empty, and the light-reflex is abolished. Dimmer finds that the reflex, though vanished from the disc vessels, remains as bright as ever on the peripheral arteries. If prolonged high pressure finally destroys the arterial reflex, the reflex from the veins disappears at the same moment or earlier. It is impossible to abolish the arterial reflex without simultaneously destroying that from the adjacent veins.

The persistence of the reflex in any artery after cessation of the axial stream which must occur when the central vessels are emptied by pressure is demonstration that the axial stream is not the cause of the arterial reflex. A similar conclusion must be drawn from Elschnig's observation of distinct arterial reflex in a case of embolism of the central artery where no pulsation whatever could be induced by pressure.

It is pleasing to those who have always held that Dimmer's views on this matter are unsound to have a definite demonstration of the unsoundness, but to the clinical observer this demonstration was hardly necessary. The more one looks at the vessels the more impossible is it to believe that the reflex on the arteries and on the veins can be produced by other than the same cause, and that that cause is the vascular wall, as first suggested by Jæger, is made most probable by many considerations, which have been pointed out by Schneller in *Graefe's Archives* many years ago (vide *Ophthalmic Review*, Vol. xi., p. 102). Dimmer's original paper is abstracted in the *Ophthalmic Review*, Vol. xi., p. 149.

J. B. S.

---

## OPHTHALMOLOGICAL SOCIETY OF THE UNITED KINGDOM.

*February 11th, 1904.*

The President, Mr. John Tweedy, in the Chair.

Cases and Card Specimens.

*Specimens from a Case of Epithelioma of the Ocular Conjunctiva shown on January 11th, 1903.*—Mr. A. Ogilvy and Mr. S. Stephenson.

The specimens shown, viz., the eyeball as a jelly specimen and two microscopic slides, both being specimens of undoubted epithelioma, which did not invade the cornea at all, and the sclerotic only slightly,

were from a patient who had been seen for the first time on December 12th, 1902, suffering from what was apparently an ordinary pterygium at the inner side of the left cornea. This had existed for some two or three months, but latterly had become inflamed and was thought to be encroaching on the cornea. In January, 1903, the pterygium had been dissected back from the cornea and for some 3mms. off the sclerotic, the wound had healed well, but out of the cicatrix a small white mass, the size of a pin's head, had subsequently grown; this had also been snipped off. This white tissue had immediately reappeared and grown rapidly; it was therefore removed, and a portion of it on microscopic examination had been found to be epitheliomatous. Within a week of its removal it had again reappeared, and at this time had been brought before the Society, when the almost unanimous opinion had been expressed that it was an epithelioma and that the eyeball ought to be enucleated. This was accordingly done about a month later. The vision of the eye up till the time of its enucleation had remained $^5/_6$ and Jäger I. The treatment had been X-ray applications and large doses of arsenic internally. No recurrence had taken place in the socket. Mr. Stephenson, who had examined the growth microscopically, considered it to be a typical example of flat-celled epithelial carcinoma originating from the parts about the limbus.

*Traumatic Aniridia.*—Mr. Arnold Lawson.

In this patient, a young man, no trace of the iris could be seen excepting over a small segment inwards where a narrow, jagged remnant was still adherent to the ciliary body. The lens appeared to be subluxated, the outer edge being directed backwards into the vitreous chamber, together with a general sinking backwards of the lens as a whole; some suspensory fibres could be made out by oblique illumination from the inner side. The lens retained its transparency. A whitish membrane could be made out lying at the lowest part of the vitreous, which might possibly represent the torn-off iris. A yellowish reflex on the outer side probably marked the spot where some inflammatory exudates were first noticed after an injury, two years previously. Another mass represented a detachment of the retina which had previously been made out. The patient had first applied for relief when suffering from the effects of an explosion of gunpowder which had blown out the breech of a gun he had just been cleaning. He then had a small perforating wound on the outer side of the cornea and $\frac{1}{4}$ of an inch behind the limbus. No foreign body could be made out by X-rays, but the presence of considerable hæmorrhage in the retina at the site of the wound with a large detachment downwards, made it more than probable that one was present. The iris at this time was intact and the lens

*in situ.* Sixteen months afterwards he was pitched out of a barrow and had fallen on his right side, striking the right temple a severe blow. On examination of the right eye it was found to be much congested and full of blood which prevented any examination of the fundus, he was not seen again for eight months, and when next examined presented the above appearances.

*Unusual Opacity affecting the Posterior part of the Lens or the Capsule.* Mr. G. Hartridge.

This case presented a somewhat star-shaped radiation apparently at the posterior capsule, which was variously attributed to (1) an actual opacity of the posterior part of the lens; (2) opacity of the capsule only; and (3) folding of the capsule due to slight shrinking of the lens.

*Congenital Kerato-iritis (double) in an infant.*—Mr. G. W. Thompson.

When seen 9 days after birth, the corneæ appeared hazy all over, the haziness occupying the middle and deeper layers of the corneal tissue, the surface was intact, the haze uniform in density with no specially dense area suggestive of previous perforation, and there had been no discharge from the eyes. When seen two months later the opacity had become less dense, and by oblique illumination the fenestrated remains of the iris could be seen glued to the back of the cornea, the adhesion extending to the extreme periphery in each eye. The tension was increased in both eyes with apparently little pain. There being no history of syphilis in the family, and no evidence of ophthalmia neonatorum, the appearances were thought to be due to tubercular trouble.

*Peculiar Changes of and around the Optic Disc in a Woman.*—Mr. G. W. Thompson.

This patient, aged 27, complained of having swollen lids and watery eyes. The vision with correcting glasses was $^{6}/_{6}$ in each eye. The right optic disc showed a flocculent, dense, greyish-white mass, obscuring the edges of the disc and extending slightly on to the retina all round; a deep, physiological cup, however, was clearly visible. This white mass was superimposed over the disc, and the disc itself did not appear to be swollen. The left optic disc was obscured in a similar manner, but at the upper and inner part a single, denser, metallic-looking patch, suggestive of some hyaline or calcareous change was present. The fields of vision were normal, and there was no scotomata. The urine was normal and there were no changes in the vessel walls to suggest any albuminuric condition. Mr. Thompson expressed doubt whether the case should be regarded as one of spurious optic neuritis or of some alteration of the hyaloid.

*Nose Blinking Phenomena: The Innervation of the Orbicularis Palpebrarum.*—Mr. N. Bishop Harman.

Four cases were shown with this movement, which consisted of a movement of the skin of the nose, affecting the skin lying along a line drawn between the inner canthus of the eye and the anterior extremity of the nostril. It is most suggestive of the movement of something under the skin, *e.g.*, a slip of muscle which by its contraction pulls up the more moveable tip of the nose. The movement is most marked over the lateral cartilages, and is hardly seen at all above the cartilages, and nearer the canthus. It appeared to be due to portion of the levator anguli oris alaeque nasi. The movement is distinctly muscular in origin and not merely a disturbance of the skin of the nose by involuntary blinking.

Case i. High myope, lateral nystagmus, frequent blinking and with each blink there was a movement of the skin of the nose along each side to the tip of the nose, but more marked on the right side than on the left.

Case ii. A lad, aged 12, vision normal. With each blink a similar movement on the side of the nose, more marked on the right side than on the left, so that the tip of the nose was at times moved to the right.

Case iii. A woman, aged 38, normal sighted. With each blink this same movement, bilateral, and equal on both sides.

Case iv. Son of the last patient, a hypermetrope, this movement bilateral and equal.

This phenomenon was stated to be found in about 20 per cent. of all subjects. The writer considered that with each blink (which is the simplest visible expression of a normal involuntary contraction of the orbicularis palpebrarum) there was a simultaneous and equally involuntary contraction of a nasal muscle, and the movement in consequence of the end or wing of the nose. On the supposition that the facial nucleus is the proper source of the innervation of the orbicularis palpebrarum, the blink may be explained as the result of a reflex from the conjunctiva by the trigeminal nerve and its nucleus, through the neighbouring nucleus of the facial to the orbicularis which acts as the guard of the conjunctiva. The same stimulus which, transmitted to the orbicularis, caused the blink, is transmitted to this slip of muscle which twitches the nose. The nuclei of the sixth and seventh were originally joined in the "facial complex" and both the muscles in question had a common spiracular origin, so the physiological connection remains in those subjects presenting the phenomenon, the differentiation of nerves and muscles not having been quite complete.

*Two cases of Cerebral Degeneration from the same family, associated with Macular Changes.*—Mr. S. Mayou.

Case I. A boy, aged 10, till four years of age had been bright and intelligent, with good vision. After an attack of measles about this time both the vision and the intellect began to deteriorate, and latterly have become rapidly worse, the vision being best at night. The boy walked sideways, with his eyes and head turned towards the left, excentric fixation and occasional divergence of the left eye. The pupils were equal in size and both were dilated, the vision was finger-counting with difficulty at a distance of two feet. An examination of the fundus showed the disc to be of a good colour but very sharply defined down and out, at the macula in each eye a small reddish-black spot surrounded by a coarsely granular pigmented condition of the retina. The periphery of the retina showed no changes.

Case II. A girl, aged nine years, had been strong, healthy, and intelligent up to three years ago, at which time her intellect began to fail but her sight appeared to remain good. The pupils were equal but sluggish in reaction. An examination of the fundus showed pallor of both discs, especially down and out where the margins were very sharply defined. At the macula the same granular pigmented condition was found as in Case I., but the dark spot was not so well marked, and the whole condition was not so extensive as in the other case, being much more limited to the macula.

Case III. A girl, aged eight years, was stated to be very backward at school and had been sent down from the first standard to the infants' school. The vision $^{6}/_{36}$ could not be improved. The pupils equal and sluggish. The fundus only showed some faint stippling at the macular region with no other changes of any kind.

All these children were the offspring of first cousins; the mother gave a doubtful history of specific disease. There was no history of insanity in the family except that the father's brother had always been very dull when a child. Only one miscarriage—at the third month—and six living children; the first was the miscarriage, after which came the three above described children, the last three were reported to be bright and healthy.

The chief points in the cases of a class to which these seem to belong are:—(1) A syphilitic history in the parents, but no other evidence of congenital syphilis in the children. (2) The simultaneous onset of the ocular and mental conditions usually between the ages of 7 and 14. (3) The loss of central vision. (4) The typical appearance of the macula described above.

*Epibulbar Tumour.*—Mr. W. H. H. Jessop.

The patient, a woman, aged 62, had suffered from some inflammation of the right eye five years ago, after which—four years ago—the growth began as a small white nodule above, and close to, the limbus. Four months ago a large mass came down from under the upper lid and obscured the sight. The patient has had no pain, though the whole width of the palpebral fissure had been occupied by the growth, which was also adherent to the lower and outer part of the cornea; no ulceration of the mass existed at any spot; the whole growth was more or less uniformly pigmented. The vision of the right eye was finger counting only, of the left $^{6}/_{18}$ (with commencing lenticular opacities). No enlarged glands could be felt.

PAPERS.

*Gonorrhoal Conjunctivitis in an Adult, treated with Peroxide of Hydrogen.*—Dr. Adolph Bronner.

The eyelids in this case were so swollen that the cornea could only be seen with the greatest pain and difficulty. The discharge was found to contain many gonococci. Ten per cent. peroxide of hydrogen drops, together with three per cent. nitrate of silver were applied, with considerable diminution in the amount of discharge, but the cornea began to look hazy, and since it was thought that this haziness might be due to the peroxide drops they were stopped. Atropine and protargol, five per cent., were then applied instead. Central ulceration of the cornea took place, peroxide drops were recommenced, with the result that the ulcer did not extent and became less infiltrated. The writer considered that the peroxide drops arrested the extension of the ulcer and caused it to heal with a very slight macula only. He recommended Merck's thirty per cent. solution, which is said to keep almost indefinitely.

*On Congenital Anterior Staphyloma.*—Mr. J. Herbert Parsons.

The notes of a case of this extremely rare congenital anomaly formed the basis of this paper. A girl aged three days was brought to the Hospital with an anterior staphyloma of the left eye, which condition had been present at birth. The mother was healthy, and the confinement had been normal, no instruments had been used, and the child had been born immediately after the rupture of the membranes. There was one other child, aged 9, with no deformity of any sort. The left eye showed a complete anterior staphyloma projecting for ½ an inch beyond the lids, no anterior chamber, the iris adherent to the pseudo-cornea, which was very thin and almost transparent. The pupil could be made out and the iris tissue was most stretched at the lower part where it had somewhat the appearance of a coloboma, but striations of

pigment could be made out over this area. There was a slight mucous discharge, cultivations from which showed staphylococcus albus. The eye had been excised at once and was somewhat hour-glass shaped, the antero-posterior diameter being 22mm., the transverse and vertical 12mm.; the staphyloma measured 10mm. from the anterior pole to the groove on the sclerotic. An examination of the sagittally-cut globe showed that the anterior staphyloma formed rather more than a hemisphere, its anterior part was extremely thin, composed of iris covered by a transparent membrane. The posterior chamber contained masses of yellow inflammatory material, and the lens was *in situ* on a level with the ciliary body. The retina and choroid were *in situ*, and the vitreous contained yellow material. Microscopically, the cornea at the sides consisted of well-marked substantia propria covered with stratified epithelium, the interlamellar spaces were packed with leucocytes. Bowman's membrane was not present, and Descemet's membrane was only present on each side for a distance of 1mm. The thin membrane forming the greater part of the staphyloma was formed of the much stretched sustantia propria without any epithelium on its surface, the layers being much infiltrated. Just internal to this membrane was an almost homogenous layer of about half the thickness which showed faint striations, next to which came the remains of the much stretched iris reduced to distorted retinal pigment epithelium. The lens showed no evidence of anterior capsular cataract. The ciliary body was detached posteriorly, the ciliary processes being drawn inwards towards the lens and stretched. The retina was *in situ* but slightly folded, the choroid was detached anteriorly, the subchoroidal space contained coagulum, and the pigment was as yet undeveloped. The optic nerve was densely infiltrated. A very complete epitome of all the recorded cases was given, from which the author concluded that exactly the same features are found in cases of anterior congenital staphyloma as in staphylomata developing in the usual manner after birth, that they show evidence of having been brought about by perforation of the cornea while intra-uterine, just as the usual staphylomata after birth develop from some perforating ulceration. The pros and cons of the possibility of intra-uterine ulceration from infection were discussed at length, the author pointing out that anthrax, glanders, tubercle, typhus, pneumococcus, etc., can be transmitted to the fœtus, also that intra-uterine panophthalmitis can occur, one case in a goat having been published, also that on the Continent most cases of microphthalmia are attributed to intra-uterine phthisis bulbi.

*Night-blindness and Lens touching.*—Major H. Smith.

Taken as read.

REGINALD E. BICKERTON.

## CLINICAL NOTES.

Hereditary Aniridia.—Moissonnier (Tours) records the presence of this very rare condition in a mother and two daughters. The mother was a rag-picker, aged 42, of very limited intelligence, both of whose corneæ presented diffuse superficial opacities, the right eye being the worse of the two; there was horizontal nystagmus. No trace of an iris was to be made out in either eye. The lenses were *in situ*, but contained fine disseminated opacities, more numerous towards the periphery. Accommodation was present, however, to an extent suited to the age of the patient. Vision had never been good all the patient's life, but had always been sufficient for the very moderate requirements of her work; there was hypermetropia to the extent of approximately 5 D., but examination was rendered a little difficult by the condition of the corneæ. Moissonnier failed to obtain any view of the ciliary body. The patient had a small head, was short but looked well; she was, however, a little feeble mentally, talkative and unreflecting, a degenerate. She had had three living children, one of whom was a boy with quite normal looking eyes: he died when a child. The other two were daughters: of these the elder, aged 19, was completely blind, but had never previously been brought to any doctor. Her irides were entirely absent, the lenses, too, were subluxated upwards. Here again the ciliary processes could not be seen. Above, about 4 mm. posterior to the corneo-scleral junction, there was a little patch of staphyloma. The indications were that the eye had been lost by glaucoma, and this appeared from the account given by the relatives to have taken place at about the age of 14; the tension, however, was not seriously increased.

The younger daughter (15) was also rather poorly developed; she had moderately good vision, hypermetropia of 3 D.; the corneæ were quite healthy. The left lens was opaque, and the irides were entirely absent.—*Archives d' Ophtalmologie*, October, 1903.

Plastic Operations on the Eyelids.—The various methods of operation for the repair of destruction of the eyelids are numberless, because in certain cases one manner of operating serves better, in other instances a different plan. The operation suggested by Rollet may be found useful, either for the upper or the lower lid. Suppose that the upper lid is destroyed over its whole length, then his plan is to mark out two horns of skin, each as long as the lid ought to be, pointing

upwards, passing the ends of the eyebrow. The bases of the horns are left attached, but from the tips they are dissected up and, each rotated through a right angle so that they meet one another, are laid side by side in the gap prepared for them so as to form a uniform skin surface. The spaces left by the removal of the horns are filled in easily by drawing the margins together after slight dissection. Should it be the lower lid which requires treatment the procedure is the same, save that the horns point downwards.—*Ophthalmoscope*, February, 1904.

Sublamin.—In sublamin are combined the powerful germicidal action of sublimate of mercury and the mildness of boracic acid. Imre (Hodmezövasarhely), who has a high opinion of argentamin as an alkaline silver preparation, thinks well also of sublamin because of the absence of acidity. Sublamin is an ethylene diamine mercury sulphate; it exists as white needles, easily soluble in water and in glycerine. Mercury forms 44 per cent. of the salt. A solution of albumen produces with a strong solution (1 per cent. or more) no coagulum even at or above body-temperature, but sodium chloride does. It is more useful than sublimate of mercury in the disinfection of the hands because it does not irritate the skin; the strength of the solution can be increased, and it affects deeper layers of the skin. Imre has found it very useful in the treatment of conjunctivitis in the strength of 1—1000; if used too frequently, however, it is capable of injuring the epithelium and causing the formation of a false membrane.—*Wochenschrift für Therapie and Hygiene des Auges*, vii., 4.

The Colour of the Macula Lutea.—The statement of Gullstrand at the Heidelberg Congress of last year that no difference is to be seen between the colour of the macular region and that of the rest of the retina of freshly enucleated eyes is opposed to Schmidt-Rimpler's observations published in 1875. The latter has consequently made another series of observations which fully substantiate his former conclusions, viz., that there is a distinct yellow colour in the macular region of the retina when examined immediately after enucleation. This colour remains visible in salt solution for as long as three weeks, and does not depend upon the presence of pigment epithelium. It is seen in eyes which have long been blind, as well as in eyes removed for recent injury. The actual seat of the colouration is hard to make out. It seems a diffuse colouring of the whole

retina.—Schmidt-Rimpler (Halle), *v. Graefe's Archiv für Ophthalmologie*, 57, 1.

Sub-conjunctival Extraction.—Czermak (Prague) suggests the following method of operating:—While the patient looks directly outwards, or outwards and somewhat upwards, he seizes the conjunctiva close to the nasal side of the cornea and makes his puncture through conjunctiva into the anterior chamber at about the horizontal meridian. The capsule may at this stage be opened with the Graefe's knife and the counter puncture made; the knife is then withdrawn. With iris forceps and scissors he now makes a vertical section in the conjunctiva extending downwards from the temporal puncture to the bottom of the *cul-de-sac*. The scissors are then used to tunnel under the whole area of cunjunctiva between this section to the temporal side, a corresponding line to the nasal side, and the corneal margin above; a large pocket is thus formed under the conjunctiva. With a pair of blunt-pointed scissors the corneo-scleral section is now made in three or four snips, the opening of the conjunctival pocket being all the while held closed by forceps. After laceration of the capsule, if this has not been accomplished before, the lens is delivered into the pocket and so out of the eye; the conjunctival section is then closed by means of a single suture. In this manner an endeavour is made to perform the operation sub-conjunctivally, and therefore with diminished risk of sepsis.—*Klinische Monatsblätter für Augenheilkunde*, November-December, 1903.

Sub-conjunctival Injections of Alcohol.—Moved thereto by the observation of the antiseptic action of alcohol, Peschel (Frankfort) has adopted the plan of sub-conjunctival injection in a number of affections of the eye. Alcohol produces a local stimulation of tissue, dilates the arteries and increases the blood-pressure, thus flushing out the part, and by increasing the lymph flow it encourages absorption of exudations; he thinks, too, that though when taken internally it does not increase the number of leucocytes, it probably has a purely local effect of this nature. The hastening effect upon osmosis is rendered so much the greater if salt is added to the alcohol; the local œdema following injection is both considerable and obstinate, but it is quite harmless. He seems to have treated in this fashion with greater or less success most of the commoner affections both of the anterior and of the posterior parts of the eye.—*Klinische Monatsblätter für Augenheilkunde*, November-December, 1903.

METASTATIC OPHTHALMIA CAUSED BY TALAMON-FRAENKEL DIPLOCOCCUS.—The present is not the first recorded case in which this particular organism was the cause of the metastasis, but instances have been so rare that this one is well worth recording. A man, aged 41, complained first of lumbar pains and tremors in the arms, but under arsenic and strychnine, with cessation of alcohol and tobacco, he recovered. The symptoms recurred, however, and at this time he was noticed to become very irritable; he had hallucinations of vision as well which greatly upset him mentally—so much so that he contemplated suicide. His lower limbs became enfeebled and he had sciatica and other nerve-pains. A few days later he had rigors, pain in the left lumbar region, and a cough with blood-stained muco-purulent secretion. Pneumococci were found in the sputum, and he was considered to have left-sided pneumonia. A second, but not the first, blood examination showed the Fraenkel-Talamon "lanceolated" diplococcus. A fortnight later he complained of loss of sight in the left eye, and in a day or two a well marked purulent metastatic ophthalmia was manifest. In a week or more later he died, having all the symptoms of sub-acute panophthalmitis. Unfortunately no autopsy could be secured, but a few days before the patient died the author had drawn off the contents of the anterior chamber with the view of making observations and cultures; he had also tapped the vitreous chamber, and in the putrid fluids thus obtained he was able to verify the existence of the Fraenkel-Talamon diplococcus.—*Annali di Ottalmologia*, Vol. xxxii., 11, 12.

ALOPECIA AREATA AND EYE-STAIN.—Alopecia has recently been shown to be not infrequently associated with errors in dentition (abnormal eruption in some cases, caries in others) as well as with headache and localised neuralgic areas. Whitfield records four cases in which the irritation leading to these consequences seemed to have its origin in errors of refraction, because, though the skin condition had resisted all other treatment, correction of the optical error was followed by relief of the pains and by the growth of a fresh crop of hair on the denuded areas.—*Lancet*, March 5, 1904.

MODIFICATION OF SIMPLE EXTRACTION.—The risk of prolapse of the iris in simple extraction is avoided by Chandler (Boston) by a compromise between that operation and the "combined" method. By means of fine forceps and of thin-bladed scissors he makes a small round "button-hole" in the

iris as close as possible to its root. Through this the aqueous humour can drain as through an ordinary iridectomy aperture, and through it cortical matter can be removed, particularly if one employs the washing out method. He thus secures a round pupil with exceedingly small risk of prolapse, and is entirely satisfied with the procedure.—*Archives of Ophthalmology*, January, 1904.

Defective Vision and Idiocy.—Hirschberg (Berlin) records a case closely resembling the type of Amaurotic Congenital Idiocy familiar to one through the writings of Tay, Magnus and others, but differing from it in certain features. The patients in the form which we may call the more usual, though it is apparently very rare, are infants of Jewish descent, the disease may affect several members of a family, vision goes down to *nil*, the macula shows a characteristic lesion, and the disc becomes atrophied; the patients usually die by the end of the second year. In Hirschberg's present case the patient was a boy of 15, of Christian descent, the father and mother, though apparently quite healthy, being cousins. There had been no miscarriages, and there were four healthy children older than the patient. Physically, the boy seems to have been quite well, though he never had very good sight, especially in evenings and in bad weather; on this latter account and by reason of his mental feebleness he had never made much progress at school. His vision was very poor. Ophthalmoscopy was not easy for he was very restless, but two features were clearly discernible—his macula was surrounded by a bright whitish ring, not so blue as in the classical variety of the disease, and there was a good deal of stippling about the periphery; the arteries of the disc very narrow, and the disc itself very pale.—*Centralblatt für praktische Augenheilkunde*, January, 1904.

---

## Bibliography.


### Anatomy and Physiology.

Bach. Centres and paths of pupil reflexes. *Zeits. f. Augen.*, February.
Bietti. Entoptic phenomenon in forced expiration. *Ann. di Ott.*, 3, 1904.
Broca and Sulzer. Time element in retinal functions. *Ann. d'Ocul.*, February.
Langley and Anderson. Union of V. nerve with superior cervical ganglion. *Journal of Physiology*, xxx., 5, 6.
Monesi. Lachrymal apparatus in foetus. *Ann. di Ott.*, 3, 1904.
Pfister. Nutrition of lens. *Corres. fur Schweizer Aerzt.*, 15, February.
Tartuferi. Elastic tissue of cornea. *Ann. di Ott.*, 3, 1904.

### Congenital Abnormalities.

de Vries. A malformation of globe *Graefe's Archiv.*, lvii., 3.
Zia. Congenital pigmentation of disc. *Die Ophthal. Klinik.*, viii., 4.

## Hygiene.

### Pathology and Bacteriology.

Bossalino. Bacteriology of conjunctiva. *Ann. di Ott.*, 3 and 4, 1904.
Schottelius. Bacteriology of conjunctivitis in measles. *Munch Med. Woch.*, 9, 1904.

### Instruments and Apparatus.

Asmus. Cleansing of instruments. *Zeits. f. Augen.*, March.
Asmus. Schumann's electro-magnet. *Klin. Mon. f. Augen.*, March.
Black. A new cataract knife. *Ophthal. Record*. February.
Blokusewski. Modified drop-bottle. *Klin. Mon. f. Augen.*, March.
Farber. Camera for photography of fundus. *Woch. f. Ther. u. Hyg. des Auges*, vii., 21.
Jourdan. Electrolysis needle. *Woch. f. Ther. u. Hyg. des Auges*, vii., 23.
Remy. Diploscope. *Rev. d'Ophtal.*, January, 1904.
Stanley. Spectacle frames for ptosis. *Lancet*, 27th February.
Stevenson. Shade for use in retinoscopy. *Ophthalmic Record*, February.
Todd. Eye irrigator. *Ophthalmic Record*, February.
Wishart. Ophthalmodynamometer. *Ophthalmic Record*, February.

### Therapeutics.

Barnes. Silver compounds. *Ophthalmoscope*, March.
Darier. Dionine. *Ophthalmoscope*, March.
Oliver. Mydriatics. *Woch. fur Ther. und Hyg. des Auges*, vii., 21.
Reber. Dionine. *Therapeutic Gazette*, 2, 1904.
Romer. Serumtherapy of ulcus serpens. *Zeits. f. Augen.*, March.
Spoto. Dionine. *La Clin Oculistica*, February.
Treutler. Mydriatics. *Woch. f. Ther. u. Hyg. des Auges*, vii., 24.
Wolffberg. Compressed Ophthalmic Tablets. *Woch. f. Ther. u. Hyg. des Auges*, vii., 25
Zazkin. Adrenalin. *Woch. f. Ther. Hyg. des Auges*, vii., 25

### Operations,

Basso. Depression of cataract. *La Clinica Oculist*, January.
Bouchart. Iridectomy, therapeutic value of. *La Clin. Ophtal*, 15 January
Sommer. Technique of iridectomy in glaucoma. *Woch. f. Ther. u. Hyg. des Auges*, vii., 23.

### Traumatisms.

Bachauer. Choked disc after head injuries. *Deutsche Med. Woch*, 9, 1904.
Gonin. Ocular lesions from lighting. *Ann. d'Ocul.*, February.
Mahillon. Colour fields after injuries. *Rev. d'Ophtal.*, January, 1904.
De Micas. Foreign bodies in anterior chamber. *Recueil d'Ophtal.*, January, 1904.
Ulbrich. Rare injury of cornea. *Klin. Mon. f. Augen.*, March.

### Tumours.

Baas. Carcinoma in lachrymal gland. *Graefe's Archiv.*, lvii., 3.
Lotin. Melano-sarcoma of lids. *Klin. Mon. f. Augen.*, March.

### Sympathetic Ophthalmia.

Barrett. Risk of sympathetic ophthalmia. *Intercol. Med. Jl. of Australasia*, 20 January.
Massi. Osseous degeneration and sympathetic ophthalmia. *Boll. dell' Osped.*, Rome, February.
Ruge. Sympathetic ophthalmia. *Graefe's Archiv.*, lvii., 3.

### Glaucoma.

Bywater. Iridectomy in glaucoma. *Brit. Med. Journ.*, 27 February.

### Amblyopia and Visual Defects.

Birch-Hirschfeld. Toxic amblyopia. *Ophthalmoscope*, March.
Bruner. Amblyopia from methyl alcohol. *Ophthalmic Record*, February.
Darier. Amblyopia ex anopsia. *Die Ophthal. Klinik*, 5, 1904.

### Refraction and Optical Questions.

Brawley. Angle gamma and strabismus. *Ophthalmic Record*, February.
Schulek. Binocular vision. *Woch. f. Ther. u. Hyg. des Auges*, vii., 2.
Seggel. Myopia. *Klin. Mon. f. Augen*, March.
Suell. Extraction of lens for myopia. *Brit. Med. Journ.*, 27 February, 1904.

## Regional Affections.

### Eyelids.

Calderaro. Ectropion from scleroderma. *La Clinica Oculist*, January.
Gidney. Symblepharon. *Ind. Med. Gaz.*, February.
Hertzog. Pathology of the cilia. *Zeits. f. Augen.*, February.
James. Operation for entropion. *Ophthalmic Record*, February.
Lotin. Melanosarcoma of eyelids. *Klin. Mon. f. Augen.*, March.
Schirmer. Lid paralysis. *Zeits. f. Augen.*, February.

## Lachrymal Apparatus.

Baas. Carcinoma in lachrymal gland. *Graef's Archiv.*, lvii., 3.
Monesi. Lachrymal apparatus in fœtus. *Annali di Ottal.*, 3 and 4. 1904.
Schulz. Substitute for excision of sac. *La Clin. Ophtal.*, 10 March.

## Conjunctiva.

Bossalino. Bacteriology of Conjunctiva. *Annali di Ott.*, 3 and 4. 1904.
Bauber. Prophylaxis of Oph. Neonat. *Münch. Med. Woch.*, 7, 1904.
Likiernik. Mechanical treatment of trachoma. *Centl. f. Augen*, February.
de Micas. Large foreign body in conjunctival sac. *La Clin. Ophtal.*, 10 March.
Braun. Removal of anilin tinting from conjunctiva. *Centl. f. Augen.*, February.
Schottelius. Bacteriology of conjunctivitis in measles. *Münch. Med. Woch.*, 9, 1904.
Steiner. Amyloid degeneration of conjunctiva. *Centl. f. Augen.*, February.
Trousseau. Prognostic value of subconjunctival haemges. *La Clin. Ophtal.*, 15 January.
Valois. Electric ophthalmia. *La Clin. Ophtal.*, 10 March.

## Cornea and Sclerotic.

Ammann. Cord-like episcleritis. *Die Ophthal. Klinik.*, 5, 1904
Brose. Ulcus cornæ serpens. *Ophthalmic Record*, February.
Colombo. Corneal epithelium in repair of wounds. *Ann. di Ott.*, 3, 1904.
Romer. Serumtherapy of ulcus serpens. *Zeits. f. Augen.*, March.
Tartuferi. Elastic tissue of cornea. *Ann. di Ott.*, 3, 4, 1904.
Ulrich. Rare injury of cornea. *Klin. Mon. f. Augen.*, March.

## Iris and Ciliary Body.

Syphiloma of ciliary body. *Amer. Journ. of Ophthal.*, January.

## Lens.

Chiari. Traumatic cataract from rupture of posterior capsule. *Ann. di Ott.*, 3, 1904.
Hess. Mechanism of accommodation. *La Clinica Oculistica*, February.

## Choroid and Vitreous.

Roosa. Choroiditis caused by excessive use of the eyes. *N.Y. Med. Record*, 20 February.

## Retina.

Alleman. Retinal symptoms of vascular degeneration. *Amer. Medicine*, 20 February.
Baas. Crystal-formation in detached retina. *Graefe's Archiv.*, lvii., 3
Jessop. Prognosis in glioma. St. Bart.'s. Hosp. Repta., xxxix.
True. Malaria and detachment of retina. *Rev. gén. d'Ophtal.*, February.

## Optic Nerve.

Pick. False optic neuritis. *Zeits. f.. Augen.*, March.

## Muscles (and Strabismus).

Delage. Torsion of the eye. *Recueil d'Oph.*. February.
Inouye. Persistent convergence. *Die Ophthal. Klinik.*, 5, 1904.
Koster. Recurrent paralysis of the third nerve. *Zeits. f. Augen.*, March.

## Orbit.

Axenfeld. Latent osteoma of frontal sinus. *Klin. Mon. f. Augen.*, March.
Birch-Hirschfeld. Osteoma of orbit. *Klin. Mon. f. Augen.*, March.
Fish. Frontal sinusitis and ophthalmoplegia. *N. Y. Medical Journal*, 27 February.

## Relations with Medicines.

Alleman. Retinal symptoms of vascular degeneration. *Amer. Medicine*, 20 February.
Becke. Eye symptoms of cerebellar disease. *Zeits. f. Augen.*, Mch.
Birch-Hirschfeld and Kraft. Eye disease in acanthosis nigricans. *Klin. Mon. f. Augen.*, March.
de Micas. Ocular element in prognosis in general distance. *Recueil d'Ophtal.*, February.
Muncaster. Neurasthenia and eyes. *Ophthalmic Record*, February.
Parry. Vertigo with Ocular symptoms. *Lancet*, 5 March.
True. Malaria and detachment of retina. *Rev. Gén. d'Ophtal.*, February.
Westphal. Movements in paralysed muscles of the eyes in Korsakow's disease. *Berlin Klin. Woch.*, 8, 1904.
Whitfield. Alopecia and eye-strain. *Lancet*, 5 March, 1904.

## Miscellaneous.

Ayres. Method of ascertaining tension. *Amer. Journ. of Ophthal.*, January.
Collins. Recent work in ophthalmology. *Practitioner*, March, 1904.
Evans. Compensation for injuries to the eyes. *Brit. Med. Journal*, 27 February.
Heimann. The blind in Prussia, etc. *Woch. f. Ther. u. Hyg. des Auges.*, vii., 24.
Osborne. The first ophthalmological "flying column" in Egypt. *Woch. f. Ther. und Hyg. des Auges.*, vii., 21.
Romer. Immunisation in ophthalmology. *La Clin. Ophtal.*, 15 January.
Weill. Heterophthalmos. *Zeits. f. Augen.*, February.

# A CASE OF RECURRENT PARALYSIS OF THE THIRD NERVE.

By L. Werner, F.R.C.S., Dublin.

A case of this kind has recently been related by Dr. W. G. Sym in this journal (vol. xxii., p. 303), and it occurred to me that the following description of a typical example of the affection, which came under my notice, might be of interest in connection with it, more especially as the details are somewhat different.

K. L., a healthy-looking country woman, aged 20 years and unmarried, came to me in October, 1901, complaining of defective vision in the right eye; this was due to mixed astigmatism, but it had not attracted her attention until other eye symptoms began to develop.

She gave the following account of herself:—Since childhood she has been subject to periodical attacks of headache and vomiting, which occur at intervals of four to six weeks. For three years past these attacks have increased in severity, and have taken place every month. The pain, which is always confined to the right side, is felt in the frontal and temporal regions, as well as in the eye itself, is of a dull, heavy character, and continues without intermission until the end of the attack, which lasts two days. It diminishes, however, in severity on the second day. A dry retching accompanies the headache, but only for the first day; it begins with, or soon after the latter, but never before it. These attacks may come on at any time during the day or night. Vision is not affected, there are no scotomata and no flashes of light.

Such was her condition up to three years ago, when, after a particularly severe attack, other symptoms were superadded. On the second day of her illness the upper eyelid of the right eye began to droop, and on the follow-

ing day the eye was completely closed, and remained so for about six weeks, after which time she regained the power of opening her eye. The headache did not last longer than usual, but she had to remain in bed for six weeks, feeling weak, owing to her inability to take much solid food, on account of the condition of her mouth and tongue, which she described as covered with a white scum. At the same time "water" kept constantly dribbling from her mouth both day and night. She has never been able to read with the right eye since this attack, although her recovery was otherwise complete.

The headache and vomiting continued to occur periodically, but were not accompanied by any return of the eye symptoms until October, 1900, that is to say, after an interval of two years, when she at first saw double and then the eye closed for three weeks. She again recovered, but the "bilious" attacks have continued up to the present.

When I saw her (October, 1901), her condition was as follows:—No trace of ptosis, no strabismus or diplopia in any position. The lower lid was perhaps a trifle retracted, when compared with the other side, but this may have been a normal condition. The only symptoms in fact were some dilatation of the pupil and inability to read. No other nerves were affected. No anæsthesia or deafness. Examination of the orbit, nose and naso-pharynx revealed nothing abnormal. $V = {}^{6}/_{60}$ and with $+1{\cdot}0$ Sph. and $-2{\cdot}5$ Cyl. ax. horiz. it rose to ${}^{6}/_{9}$. The pupil measured 5·5mm. in medium light, as compared with 3mm. in the left eye. All the reactions were present but sluggish. She had very little power of accommodation; with the addition of $+4$ to her correcting glasses, she could read Snellen D. $= 0{\cdot}5$ at about 16 or 18cm. Disc normal. Left eye also normal. $V. = {}^{6}/_{6}$.

*Personal history.* Had measles and typhoid fever several years ago. Last May had a rash all over her body and her skin was inclined to peel, but it was not accompanied by sore throat or pains in her bones. Suffers from constipation, bowels moving generally every third day. Menstruation began at the age of thirteen and had been regular until three years ago, when she was troubled with amenorrhœa which lasted for two and a half years. Since March, however, she has been quite well again, in this respect. The "bilious" attacks have no relation, she says, to the menstrual periods.

*Family history.* Father died of typhoid. Mother alive and in good health. Has four brothers and two sisters, who are all apparently healthy, with the exception of one sister who had hæmorrhages from the lungs three years ago, but is now well. None of them have ever suffered from headaches or eye troubles.

It is evident from the preceding description that this is a typical case of recurrent paralysis of the third nerve. The "bilious" attacks began, as they nearly always do, in early youth, the headache was always unilateral and on the same side as the affected eye, and was not accompanied by photopsiæ; moreover it was not lancinating or neuralgic in character. The persistence of an internal ophthalmoplegia, in the intervals between the later attacks, stamps the case as belonging to the periodically exacerbating variety of the disease. The third nerve alone was involved; paralysis of the sixth, as in Sym's case, is exceptional. Excessive salivation, which proved very distressing to my patient, has been occasionally noted, as have also profuse perspiration and increased nasal secretion. It may be observed that the two paralytic attacks occurred while the patient was suffering from amenorrhœa, but on the other

hand, the uncomplicated bilious attacks, which were of the same nature, took place during the same time, and also when the menstruation was normal, and even at an age when menstruation had not yet set in. So that in this instance little or no importance can be attached to it as a cause.

Our knowledge of the pathology of this disease is most unsatisfactory and for the most part purely speculative. It is true that in three or four of the periodically progressive cases a definite lesion of the third nerve was found, which in itself, though quite sufficient to account for the paralysis, fails altogether to explain the other symptoms and features of the disease. It seems to me that an accumulation of toxins in the system, from constitutional or other causes, would best explain the symptoms in the majority of the cases. The poison might be generated by gastro-intestinal derangements which may themselves be the cause of the "bilious" attacks, or it might be introduced from without, or produced in other parts of the system, and in turn cause gastric symptoms directly, or indirectly by affecting the nerve centres. This would explain the long duration of the disease, the attacks without paralysis, the purely intermittent paralyses, and the exacerbating forms with permanent paralyses in the interval between the attacks. The nature or quantity of the poison present in the system would, in some cases, be sufficient to cause an inflammation of the nerve or nucleus which would be transient in its effects, or if it reached a certain degree, would inflict more or less permanent damage. Priestley Smith mentions an interesting case which seems to bear out this view; acting on the supposition that some poison, probably urea, was at work, he dieted his patient, and ordered him to take a pint of hot

water twice daily, with the result that considerable improvement took place and continued while the patient was under observation—five or six years. The existence of constipation in many of the cases, also tends to point in this direction.

The case recorded by Sym differs in several respects from the general type. As he points out, the headache was not unilateral, and the sixth nerve was also involved, but in addition there was no vomiting, and the age at which the first attack began was unusual. In 46 cases collected by Mingazzini the disease began after 30 years of age in only four.

The best account of this subject, so far as I know, is given by Willbrand and Saenger in *Die Neurologie des Auges*, Vol i, p. 483. Priestley Smith's observation quoted above will be found in the discussion on an interesting paper by Holmes Spicer and Ormerod, in the *Transactions of the Ophthalmological Society*, Vol. xvi., p. 277. It contains an analysis of 29 cases as well as seven original observations.

---

## REVIEWS.

CHAILLOUS. **Parinaud's "Infective Conjunctivitis."** *Annales d'Oculistique*, January, 1904.

IN 1889 Parinaud brought before the Ophthalmological Society of Paris three cases of a previously undifferentiated form of conjunctivitis. He described the disease as being undoubtedly infective, probably of animal origin, and invariably causing glandular suppuration. In his three cases the affection was unilateral. Sans, in 1890, published two similar cases. In 1896 Despagnet recorded a case with the interesting fact that suppuration of the affected glands did not invariably occur. In 1897 Morax recorded another case from Parinaud's clinique. In 1898 Gifford, in the *American Journal of Pathology*, described five cases, followed in the *Ophthalmic Record*, of

1901, by a case of Ella Wylie's. The most recent publications previous to the present paper are two in 1903, one by Jocqs, the other by Chaillous and Mlle. Toufesco.

In the present paper are four previously unpublished cases of Chaillous and one of Roche, which last occurred at Parinaud's clinique. In all, therefore, there are now 20 cases recorded. Parinaud's infective conjunctivitis resembles at first sight a very acute form of trachoma. The granulations, which at first are semi-transparent and of the size of a millet seed, soon become yellowish, and later red and opaque. They have the usual situations of the trachoma granule, but often involve the lower *cul de sac* and may even extend on to the bulbar conjunctiva. The discharge is mucoid and seldom muco-purulent. The lids are much swollen and contain localised indurations which suggest the presence of a chalazion. The parotid region is occupied by an inflammatory swelling extending down into the neck, and in this swelling enlarged glands can be felt.

The attack is usually accompanied by a slight rise of temperature and may be ushered in by rigors. This febrile condition may persist for many days. There is very little pain either from the infected conjunctiva or from the enlarged glands. The conjunctival condition shows a tendency to spontaneous cure after four or five months without leaving cicatrices. The enlarged glands in the pre-auricular region and behind the angle of the jaw usually suppurate. This suppuration is one of the chief characteristics of the disease, as Parinaud pointed out in 1889, for, though temporary enlargement of the pre-auricular glands is common with other inflammatory conditions of the lids, suppuration is rare. Ella Wylie, in 1901, drew attention to the presence of numerous erosions of the conjunctiva situated between the granulations, and since that time the presence of these erosions has been noted in a large proportion of cases.

The statement of Parinaud with regard to suppuration of glands must be modified, as out of the 20 cases now recorded, all of which showed enlarged glands, in six cases only did suppuration occur. Parinaud's first three cases all showed suppuration of glands, this also occurred in a case described by Sans, and in the two following:—

I. (Jocqs). A doctor in Paris brought his son, aged nine years, with an affection of the right eye, and gave the

following history:—Three months previously an abscess appeared in the right parotid region which was incised, a few days later the right upper lid became swollen and the glands in the sub-maxillary region enlarged; these, however, did not suppurate. When seen by Dr. Jocqs there was a slight muco-purulent discharge, and the right upper lid was in a condition of partial ptosis from inflammatory swelling. On everting the lid the whole of the *cul de sac* was found to be filled with granulations which extended over the outer two-thirds of the palpebral conjunctiva. After treatment with the galvano-cautery a cure was effected in about two months. The patient was shown to M. Parinaud, who confirmed the diagnosis.

II. (Ella Wylie, *Ophthalmic Record*, June, 1901). Patient was aged 32 years, and gave a history of only ten days. When first seen there was some swelling of the left upper lid with abundant muco-purulent discharge. The superior palpebral conjunctiva was œdematous and very vascular; the lower conjunctival *cul de sac* showed many small granules. The sub-maxillary glands on the same side were enlarged. The case was kept under observation, and two days later the swelling of the lids had increased, the granules in the lower *cul de sac* were now very large, and between these granules were many erosions. The conjunctiva of the upper *cul de sac* was so much swollen that it overlapped the cornea, and in the retro-tarsal fold were found many small granules but no erosions. The left side of the face was now much swollen. The patient had had some slight rigors and the temperature rose to 102·5 F. The symptoms slowly subsided, and three months from the onset the erosions had disappeared, but the granular condition still persisted. As the enlarged glands in the sub-maxillary region showed signs of fluctuation, they were incised. Six months from the onset complete recovery, except for slight ptosis, took place. The patient during this time lost a stone and a half in weight.

In none of the other cases recorded did suppuration of glands occur although all the cases were accompanied by enlarged glands. Gifford's five cases are then recorded; as the disease is hardly recognised in this country it may be well very briefly to summarise these cases:—

III. Patient's age was 43. The right eye only was affected.

Patient was first seen three weeks after the initial symptoms. There was a history of injury to the right eye with a piece of coal two days before the lids became inflamed. When first seen there was intense swelling of the right upper lid, the palpebral conjunctiva was completely covered with granulations, and the presence of many erosions was noted. The pre-auricular and sub-maxillary glands were enormously swollen, but suppuration in these glands did not occur. Slight ptosis remained after the patient had otherwise recovered.

IV. Patient was aged seven years. The left eyelids had been swollen for six months, and had been worse for the last two weeks. On examination it was found that both the upper and lower *cul-de-sacs* were filled with large granulations, many of which were pedunculated. The pre-auricular gland and those at the angle of the jaw were much swollen, but did not suppurate. The granulations were scraped under chloroform and a rapid cure resulted.

V. Patient's age was 33. First noticed a swelling of the left lids 14 days previously, followed 24 hours later by a discharge from the eye and swelling of the glands of the face and neck on the same side. On examination three large fungating granulations filled the upper *cul-de-sac*. In the middle of the *cul-de-sac* a large superficial ulcer was found about a quarter of an inch in diameter, with raised edges and a greyish irregular base. The pre-auricular and sub-maxillary glands were swollen, but eventually subsided without suppuration. The granulations were scraped and the ulcer cauterised with silver nitrate.

VI. The fourth patient, aged nine, showed pustular nodules in both *cul-de-sacs* on the left side, and in the lower rose large fungating vegetation; there were many large erosions of the conjunctiva in both lids. The pre-auricular glands were not involved, but a chain of enlarged glands could be felt behind the sterno-mastoid on the left side.

VII. The fifth patient, age 25, gave a history of two weeks' swelling of the right lids, which had become worse during the last few days. Both *cul-de-sacs* were filled with granulations and many erosions were seen, some in the bulbar conjunctiva, one-eighth of an inch in diameter, and some close to cornea. The pre-auricular and sub-maxillary glands were enlarged but did not suppurate.

Chaillous' five cases, followed by one of Roche's, complete the series:—

VIII. Patient, aged 41, gave a history of three weeks' inflammation of the left lid. When first seen there was considerable inflammatory swelling of the upper lid resembling in appearance a gonorrhœal ophthalmia. The palpebral conjunctiva showed no proper granules but was covered with innumerable white pin-point spots; towards the inner side of the superior *cul-de-sac* an erosion was seen nearly a quarter of an inch in diameter. The whole side of the face was swollen, the pre-auricular glands and those behind the angle of the jaw were enlarged and tender. The patient showed signs of general malaise. The diagnosis lay between tuberculous disease of the conjunctiva and Parinaud's infective conjunctivitis, and in order to determine this a guinea-pig was inoculated with material removed from the margin of the ulcer; no result followed. The conjunctiva and the ulcer were cauterised with the galvano-cautery; this was repeated three days and also five days later. Rapid improvement resulted, and two days after the last cauterisation, except for slight ptosis, the conjunctiva appeared healthy. The glands slowly subsided without suppuration.

IX. (Chaillous and Toufesco). Patient, aged 16 years, complained of trouble in the left eye, which had begun four days previously. June 10: On examination the left upper lid was seen to be much swollen, there was slight muco-purulent discharge. On everting the lower lid the conjunctiva of the *cul-de-sac* was found to be covered with opalescent vegetations arranged in a very regular manner. The upper lid showed similar vegetations growing from the tarsal conjunctiva as well as from the region of the *cul-de-sac*. The ocular conjunctiva showed no sign of infection. The pre-auricular gland was swollen and painful, as were other glands on the neck. The epitrochlear, axillary, and inguinal glands on the left side were also enlarged, but were indurated, movable and painless. *Family History:* The mother had had hæmoptysis. Out of eight children three only survive, of whom patient is the youngest. The first five children all died young. *History of present condition:* Patient works in a factory, and is much exposed to dust. A week before the ocular trouble began patient had a small abscess on the inner side of the left forearm. Two of his fellow-workmen at the same time had similar

abscesses. (In one case of Parinaud's the husband of the patient was suffering from an abscess in the jaw whilst the patient was being treated for infective conjunctivitis.) On examining the arm there was found a superficial induration with a small central ulcer; from this ulcer cocci resembling staphylococci were obtained. The conjunctival discharge was also examined bacteriologically but appeared to be sterile. June 11: The right eye discovered to be also affected; it showed a milder form of a similar condition to that in the left. June 12: The bulbar conjunctiva on the left side was beginning to be invaded in an irregular manner. June 14: The right pre-auricular gland became enlarged and tender and on the same side the cervical subclavicular axillary and epitrochlear glands could also be felt to be enlarged, but not to the same extent as on the left side. June 16: Patient seen by M. Parinaud and diagnosis confirmed; the question was raised as to whether the disease might be of aphthous origin. In order to investigate this the nasal mucous membrane of a sucking pig was inoculated with a scraping from the infected conjunctiva, without result. June 23: The right pre-auricular gland was excised. July 4: Nose and throat examined, and the presence of nasal catarrh and adenoids noted. *Progress:* The conjunctival affection slowly cleared up, but the glandular condition persisted. On October 11 the lids appeared normal but the palpebral conjunctiva showed thickenings of a papillary type somewhat resembling "spring catarrh."

X. (Roche). Patient, aged 55 years, gave a history of ten days' swelling of the lids on the left side with pain in the pre-auricular region and about the angle of the jaw. There was much œdema of the lids with marked chemosis. The palpebral conjunctiva was swollen and the presence of many prominent papillæ was noted. The pre-auricular and sub-maxillary glands on the left side were enlarged. A fortnight later the conjunctival affection on the left side had cleared, but the right eye was now affected in a similar manner though without the corresponding enlargement of glands.

XI. (Chaillous). Patient, aged two years, came with a history of five days' redness and swelling of the lids on the right side with some febrile symptoms. The eyelids on the right side were much swollen and there was a considerable amount of muco-purulent discharge. The conjunctiva of the lower lid had a reddish granular appearance, most marked

about the region of the *cul de sac*. The conjunctiva of the upper lid was affected to a less extent. The pre-auricular, angulo-maxillary, and cervical glands were enlarged and tender on the same side. The patient lived with his parents, who were butchers. The condition persisted for several weeks.

XII. (Chaillous). Patient, aged 59, complained that about a month previously the lids of the right eye became swollen; soon after a muco-purulent discharge began to flow. About the same time she suffered from general malaise and rigors. The right upper lid was much swollen and the conjunctiva of both upper and lower lids was red and thickened, and covered with pale granulations most marked about the *cul-de-sacs*. The pre-auricular gland on the same side was much swollen. The condition completely cleared up after treatment for a fortnight.

XIII. (Chaillous). Patient, aged 13 years, complained of swellings of the eyelids on the left side during the last fortnight. The lids were slightly reddened and œdematous. On eversion many prominent vegetations were found, growing chiefly from the region of the upper *cul de sac;* these hung over the cornea like a curtain. The growth was of a reddish colour and very irregular in shape; some of the most prominent of the vegetations were slightly umbilicated and many were pedunculated. There was a slight muco-purulent discharge. The left side of the face was much swollen from glandular enlargement in the pre-auricular, angulo-maxillary, and sub-maxillary regions. The microscopical examination of the discharge was negative. The mass of growth in the upper *cul de sac* was excised and the pre-auricular gland punctured, but no pus was found. Five weeks from the origin of the disease the conjunctiva appeared to be quite normal; the glands, however, were still enlarged.

From these observations the following characteristics are to be noted:—The disease is nearly always unilateral, for out of 20 cases two only were bilateral, and in both these cases the disease was at its maximum in one eye before the other was attacked.

*Symptoms.* The granulations vary extremely in size and appearance, their colour is either yellow, red or purple. Towards the termination of the disease the granulations resemble those of trachoma, but only for a short time, as the

conjunctiva soon regains its normal appearance. The presence of erosions is one of the most interesting signs, and this should be sought for in all cases. The erosions are usually found between the granulations, and, as a rule, can only be seen after separating the granulations with a probe. No scarring results after the erosion has healed. This condition was found in eight out of the 20 cases here recorded. Enlargement of glands was present in all the cases, and in six suppuration occurred. The glands most commonly affected are the pre-auricular, angulo-maxillary and sub-maxillary; in one case enlargement of glands was general. Suppuration of glands appears to bear no relation to the presence of erosions.

*Prognosis.* The enlarged glands commonly persist many months after the conjunctival condition is cured. The conjunctiva almost invariably heals after two or three months and no scarring remains; in this the disease differs markedly from trachoma. The other chief differences are in the objective appearance of the granulations, the presence of enlarged glands, and the constitutional symptoms.

*Diagnosis.* It is more difficult to differentiate between Parinaud's infective conjunctivitis and tuberculous disease of the conjunctiva, as granulations, erosion, and enlarged glands occur in both diseases.

*Etiology.* Parinaud suggested the probability of the disease having an animal origin. Nine out of 20 patients had been exposed to animal infection. It is noteworthy that in no case is there any record of a patient infecting others. Parinaud removed some pus from a suppurating gland which was examined bacteriologically with negative results. Morax, in 1896, examined the conjunctival discharge bacteriologically and also inoculated the anterior chamber of a rabbit's eye with a piece of infected conjunctiva, but both attempts were without result. Gifford made experiments in three cases and only obtained organisms of secondary importance. He also made a microscopical examination of some of the large granulations in Case v. and found only granulomatous tissue with giant cells. Jocqs examined a piece of infected conjunctiva and found cocci, probably streptococci. Chaillous inoculated the subcutaneous tissue of a guinea-pig with a piece of conjunctiva without result. Ella Wylie found staphylococci and pneumococci, and considered them both as secondary. Three guinea-pigs inoculated with pus from a suppurating gland all died

from acute peritonitis due to streptococci. Morax examined the conjunctiva removed from Case ix. and Case xi. (Chaillous) and reported that the epithelium was normal, the sub-epithelial tissues, however, were much infiltrated with round cells, and in places this infiltration was so marked that a projection was caused which formed the granulation. The infiltrating cells were chromophilic, with large nuclei and poorly developed protoplasm. Many of the nuclei showed well marked karyo-kinesis, the cells resembled lymphocytes in appearance. There were also present larger cells having the characters of macrocytes. Many small blood-vessels were present, but the numbers were fewer than are usually seen in the trachoma granule. The sections of a piece of pre-auricular gland only showed general hypertrophy. Morax also inoculated two guinea-pigs, one with a piece of the gland, and the other with the conjunctiva, but without result. He also attempted to isolate organisms by means of gelatin and serum tubes, and lastly inoculated the anterior chamber of a rabbit with another piece of the gland, all without result. Darier's case (*Clinique Ophtalmologique,* 1903), which bore some resemblance to a case of Parinaud's infective conjunctivitis, contrasts markedly with these results, for, after hardening the specimen in formaline, Darier found giant cells and tubercle bacilli. Animal experiments were also made in Case xiii. without result. The microscope showed a very marked sub-epithelial infiltration of cells resembling lymphocytes. The infiltration resembled somewhat that of trachoma, but differed in being more diffuse and consisting almost entirely of lymphocytes, whereas in trachoma numbers of phagocytes are also seen.

*Treatment.* Antiseptic lotions and cauterising with silver nitrate or copper sulphate appear to have been useless in the above cases. Destruction of the vegetation with the galvano-cautery or actual excision of the same seems to be indicated.

*Conclusion.* There is, therefore a conjunctival affection characterised by coloured vegetations, variable in size and shape, and most often unilateral. Erosion or even ulceration of the conjunctiva may accompany these vegetations and in all cases enlargement of the pre-auricular and cervical glands has been noted. The glands in a certain proportion of cases suppurate. The natural tendency of the conjunctival affection is towards a cure, but the gland trouble continues for some months after the conjunctival affection has cleared up.

The clinical characteristics of this disease resemble in

many ways tuberculous diseases of the conjunctiva. The many animal experiments, however, which have been performed prove undoubtedly that the disease is not due to this organism. In most cases it will be necessary to make at least a microscopical examination before Parinaud's infective conjunctivitis can be unequivocally diagnosed. A useful list of references follows the original paper.

ELMORE BREWERTON.

---

KAMPHERSTEIN. **The Ocular Symptoms of Multiple Sclerosis.** *Archiv für Augenheilkunde*, December, 1903.

IT is only within comparatively recent years that optic atrophy has come to be recognised as one of the symptoms of multiple sclerosis. Uhthoff was the first to publish statistics on the subject abroad in the eighties, and in England Dr. Buzzard has published many articles bearing on it during the last dozen years.

Kampherstein's article is founded on thirty-seven cases, of which twenty-three were undoubted cases, and the remaining fourteen were probable ones, of multiple sclerosis. Twenty-six of the patients were men and only eleven were women. The majority were between eighteen and thirty-five years of age, but six out of the thirty-seven were between ten and fifteen, certainly an unusually early age for this disease.

With regard to the state of the discs, in only one instance was the optic atrophy far advanced. This was the case of a girl of twenty-five in whom the symptoms of multiple sclerosis were well marked. There was double optic atrophy with central scotoma for white in each eye, vision being reduced to counting fingers. It is noteworthy that even in cases where optic atrophy appears complete, absolute blindness has only been recorded in a single case (Uhthoff). Dr. Buzzard, writing in the *Brit. Med. Journ.*, 1893, Vol. ii., p. 781, had never seen a case.

In three instances there was atrophic discoloration of the whole papilla, in two of them in both eyes, one of them in one eye only. In neither of these cases was there any indication of past neuritis. In one—a man of twenty-five showing well marked symptoms of multiple sclerosis—vision was reduced in each eye to counting fingers, and in one eye there was a large central scotoma for white. In this case the history was that the disturbance of vision had come on four years

before any other symptoms were noticed, a fact which we may well bear in mind in relation to those unexplained cases of optic atrophy which we occasionally come across.

In the great majority of cases where the ophthalmoscope showed any change at all—20 out of 25—it was only slight: pallor confined to the temporal side of the disc in one eye in ten cases or in both eyes in eight, and in two cases a sector-shaped pallor in one disc. In all these cases, however, except four, the field of vision was more or less reduced. Only in 12 out of the 37 cases did the ophthalmoscope fail to show any pallor of either disc, a proportion of normal discs which is considerably smaller than that mentioned by previous observers. Buzzard, for instance, out of 100 cases found pallor of one or both discs in only 43, but it is obvious that in such observations much must depend on the observer's standard of normality.

In only one case was optic neuritis observed. This was in a man of 30. The disc margin was obscured in both eyes. There was no swelling, but there were signs of old hæmorrhages. Vision was $^5/_5$ in each eye and the fields were full. It was only after his appearance at the eye clinic that a diagnosis of multiple sclerosis was made. Previous observers have noted a somewhat larger proportion of cases of optic neuritis. Uhthoff, for instance, out of his 100 cases found six. They all, however, were of a slight and fugitive nature, and it seems quite possible that many such cases, giving rise to little or no disturbance of vision, pass unrecorded.

With regard to the fields of vision some anomaly was found in the majority of these cases when it was accurately taken. Only three patients out of the 37 had absolute central scotoma, two of them in both eyes and one in one only. Five had a relative central scotoma without any peripheral contraction, in four of them the scotoma being double. (This point may be borne in mind in the diagnosis of toxic amblyopia.) Three had a relative central scotoma with some peripheral contraction of the field, while four had some peripheral contraction with relatively intact central vision. In two there was merely a failure to recognise green, or red and green, thoughout the field. The history of one patient is given—a man of 28, who, on first being seen, had an absolute central scotoma in his right eye, while his left field was normal, though there was some temporal pallor of the disc and vision was only $^6/_{10}$. Subsequently there came a relative central scotoma in his

left eye and vision was reduced to counting fingers. In this case the affection of vision in the right eye had been an early symptom.

The article would be more valuable if in more cases the state, both of the discs and of the usual fields, had been watched and recorded through a number of years, and it is information based on observation of this nature that is required to make our prognosis in these cases something better than a mere matter of guesswork. Another point that occurs to the reviewer is that some of these cases may have been mixed cases of multiple sclerosis and toxic amblyopia, for, in his experience, the latter condition is apt to be overlooked when occurring as a complication of some other disease.

The rest of the article is devoted to points of minor interest. The pupils were anomalous only in four out of the 37 cases, in three of them showing an inequality. In one of them the more dilated pupil did not act to light, but acted feebly to convergence—a very rare combination in multiple sclerosis. More commonly there is miosis with the reflexes preserved. In a fourth case there was no inequality, but one pupil acted more readily than the other to light.

The external ocular muscles were affected in 10 out of the 37 cases, the external rectus being the most susceptible muscle, while in isolated instances the internal and superior rectus were affected. In five cases the paralysis was not of muscles but of lateral movements. In no case was paralysis of convergence observed, although this has been recorded by Uhthoff. These observations would be more valuable if we were told whether the pareses observed were of a fugitive nature, as in tabes, or whether they were permanent.

Lastly, nystagmus or nystagmoid movements occurred in 30 out of the 37 cases. In only four cases, however, was it pronounced. In one of these cases it was not present when both eyes were open, but was only manifest when one was shaded or when the eyes were directed so far to one side that the line of sight was outside the limit of the binocular field. With regard to the explanation of nystagmus, Uhthoff believes that the sclerotic process so far interferes with the path of the fibres from the cortex to the nuclei or from the nuclei to the muscles that without being paralysed their action is so far hindered that they are unable completely to hold their own in their struggle with the antagonising muscles.

A. H. T.

HEINRICH FREUND (Reichenberg, Bohemia). **Trellised Opacity of the Cornea.** *Von Graefe's Archiv für Ophthalmologie*, 52, 2.

FEHR (Berlin). **Family Spotted Degeneration of the Cornea.** *Centralblatt für praktische Augenheilkunde*, Jan., 1904.

ATTENTION has recently been drawn, in several publications, to a chronic disease in which there is a gradual diminution of vision from opacity of the cornea. The first description of this rare and characteristic affection was given by Biber in 1890; he reported three cases which he called "trellised keratitis" (gittrige Keratitis). In 1899 Haab described seven and Dimmer three cases.

A very similar corneal affection was described in 1898 by Groenouw as nodular opacity of the cornea (knötchenförmige Hornhauttrübung), and later by Fuchs. Freund in this paper reports 15 cases of trellised corneal opacity, all occurring in two families in which this disease was hereditary. The disease was seen at various stages in the different members of the families, and was traced through four generations.

The disease always begins after puberty. It attacks both eyes, but one is usually more affected than the other. In Freund's cases it was the right eye which was generally most affected.

In the first stage there are usually no subjective symptoms. The diminution of vision is at first so gradual that it is often not noticed. This was shown in many of the cases by the corneal condition being discovered by the physician who had been consulted on account of conjunctivitis. The first disturbance consists usually in troublesome dazzling, which occurs at the formation of the first nodules and is due to irregular refraction. At this stage of the disease are seen at most only a few isolated elevations in or around the middle of the cornea. Corresponding to these are the very smallest light grey opacities which lie immediately under the epithelium. These on magnification appear as fine points and streaks. By reflected light these opacities disappear; the nodules appear transparent with dark margins like a drop of water on a glass plate. In this first stage there is already a fine blue-grey opacity which is most marked at the centre of the cornea. On magnification this opacity is lost in a meshwork of fine grey-blue wrinkled lines which cross irregularly. Besides these opacities from which the disease derives its name there are, in this stage,

numerous lines to be seen, most of which radiate from the periphery towards the centre; they are grey, and appear to lie close under the epithelium. In certain places by focal light they are transparent, like glass threads (Haab). By reflected light they are intensely black, and resemble remains of vessels after inflammation of the cornea. They, as well as the previously described meshwork of fine opacities, are sometimes present when the corneal surface is still quite smooth and free from elevation.

In the second stage of the disease the corneal opacity, usually between the 30th and 40th years, advances rapidly, and there is a correspondingly rapid diminution of vision. The corneal opacity becomes very dense, especially at the centre, and the fine trellised character of the opacity can only with difficulty sometimes be made out on magnification. Towards the periphery of the cornea, on the other hand, the fine trellised design of the opacity is always still recognisable. But the margin of the cornea for one or two millimetres is entirely free from the opacity. The opacities lie in the deep layers of the parenchyma, but extend to the epithelial layer of the cornea. The previously described birch-twig-like lines are still to be found here and there at the periphery; they become lost, however, in the general opacity. Meanwhile the surface of the cornea has become uneven at the centre, where little nodules arranged in rows give to the cornea the appearance of being covered with fine gravel. But most of the epithelium is still smooth and polished; only in special cases is it already raised like a ridge as if pushed up by the underlying opacity. On some of these ridges the epithelium is opaque from calcareous degeneration. By reflected light the cornea appears to be filled in its different layers by detritus-like dense opacity, while on its surface the drop-like opacities are still clearly seen.

In the last stage the disease may run one of two courses. In one group of cases—the mild ones—the opacity and granular condition of the cornea still increase more or less, but finally the condition remains stationary. The trellised design in the opacity of the parenchyma can always be recognised. The vision also remains stationary, corresponding to the cessation of the process. The patients complain of dazzling and desiccation, but gradually get used to their condition.

In another group of cases—and these are the more numerous—very distressing inflammatory symptoms come on and often last for several years. In these cases the epithelium over the

nodules and ridges becomes degenerated, the ridges become chalky white, the opacity reaching to the surface. At the same time parts of the degenerated epithelium rub off and produce the appearance of corneal abscesses with their objective and subjective symptoms. Gradually, certainly often after several years, these inflammatory appearances subside and there remain on the cornea numerous more or less dense scars which at first sight might give the impression of leucomata. Yet at the centre the small punctiform opacity in the parenchyma is often still recognisable as well as the network of opacity at the periphery. The margin of the cornea even in the most advanced cases is entirely free from the opacity. Therefore, in some cases an optical iridectomy can be done with a fairly good result.

The disease is a family one. It is hereditary and presents the type of an hereditary disease. Concerning the histological origin of the disease the writer, from want of histological material, has nothing definite to say. From clinical observation only so much is clear, that the changes first of all lie close under the corneal epithelium, which is free from the disease. Later there are elevations of the epithelium over the opacities, which in places degenerate in course of time. The linear and punctiform opacities appear, on account of absence of inflammatory signs, to be produced not by cell infiltration but by the formation of spaces and by hyaline degeneration.

The etiology of the affection is quite obscure. Most of the patients were robust and without signs of syphilis or any severe constitutional disease.

Fuchs's description of nodular opacity of the cornea shows a similarity to Freund's cases. There is a difference, however, in the size and arrangement of the opacities and in the presence of an arrangement of fine points instead of a trellised opacity as in the present cases.

Briefly, the trellised corneal opacity has the following characteristics:—

1. It is an hereditary disease; it first appears after puberty.
2. It is distinguished by grey, superficially situated points in and around the centre of the cornea, which lie under the epithelium, arching it up in coarse irregularities; and
3. By a diffuse corneal opacity which, on magnification, appears as a trellised network, and besides, especially at the beginning, by radial birch-twig-like linear opacities. The edge of the cornea always remains free from the disease.

The peculiar affection described by Fehr has many points in common with the rare hereditary diseases dealt with in Freund's paper and named trellised keratitis. Yet the characters from which this disease derived its varied names are wanting; neither "trellised" nor "nodular" is a suitable designation for the appearance of the corneal opacities in the present cases.

The writer describes three cases. They are the three younger members of a family of six; there was no eye trouble in any member of the family; the disease showed a striking similarity in all the cases; there was no evidence of hereditary constitutional disease such as syphilis or tuberculosis.

In three members of a family who were otherwise healthy and strong and who appear to have had no hereditary taint there developed, without known origin, one and the same eye affection. This was characterised by a progressive opacity of both cornea with corresponding diminution of vision. It was neither preceded nor accompanied by signs of inflammation as an essential factor in the process. The disease began from the tenth to twelfth year—before or at puberty. It propressed slowly but continuously, and after about 30 years' duration (observed for 22 years) had rendered one patient totally unfit to earn a livelihood and had markedly diminished the work-capacity of the other two. With the exception of disturbance of vision and slight irritability there was no subjective disturbance; dazzling and photophobia were absent.

The cornea presented to the naked eye a diffuse grey opacity with scattered white points and spots of various forms. On examination with a strong lens the diffuse opacity appeared to be composed of the finest shagreen-like points and the punctiform and spotted opacities by the concentration of these. The densest opacities were central, towards the periphery they were less dense and more uniform, the margin of the cornea was little affected, or not at all. The opacity was situated chiefly in the superficial layers of the cornea, but at the corneal margin it was in the deeper layers. There was no vascularisation of the cornea and no evidence of participation of the iris or deeper structures. In each of the six eyes the surface of the cornea was smooth, even, and of normal polish; sensation was normal. The etiology of the affection is quite obscure. No benefit was derived from any form of treatment.

The writer regards his cases as belonging to those of the

trellised and nodular corneal opacity groups. They agree with these in the following respects:—

1. Slow development of the corneal opacity with absence of inflammatory signs as an essential factor.

2. The onset of the disease in early life (10th to 12th year).

3. The very chronic course.

4. The family tendency with absence of demonstrable constitutional disease.

But the cornea itself presents essential differences. Nowhere are there elevations of the corneal surface corresponding to the opacities; there is no unevenness. In each of the six eyes the surface of the cornea was quite smooth and polished. By this the disease is distinguished from trellised as well as nodular corneal opacity, in which there are coarse elevations of the cornea. From the trellised corneal opacity the cases also differ by absence of the trellis-like pattern. An isolated case published by Koerber in 1902 as punctiform and spotted opacity of the cornea is perhaps identical with the present cases. Fehr is undecided whether this case, as its author says, is to be regarded as a connecting link between the trellised and nodular opacity groups. He thinks that there is a greater resemblance between the trellised and nodular corneal opacities than there is between either of these and Koerber's or his own cases; it is much more likely that the nodular corneal opacity forms a connecting link between the trellised corneal opacity and his cases. He would place Koerber's and his own cases alongside of the trellised and nodular forms as a third variety of the same disease, and speak of family spotted corneal degeneration (familiäre fleckige Hornhaut-Entartung), a designation which, on account of its comprehensiveness, may be applied to the whole group.

C. H. U.

---

HEINE. **Clinical and Theoretical Memoranda Regarding Myopia.** *Archiv. für Augenheilkunde*, December, 1903.

THE view that myopia of less than 6 D. is never associated with posterior staphyloma, and is never in danger of developing into the perniciously progressive form, is strongly advocated by Schnabel in Vol. iii. of Norris and Oliver's "System." It is a view which obviously tends to minimise the importance

of the careful treatment of school myopia, and is vigorously contested in this paper by Heine, who here develops the position taken up by him at the Heidelberg Congress of 1901 (vide *Ophthalmic Review* for 1902, p. 221), that there are forms of myopia which can be prejudicially influenced by near work and that the best treatment in most cases is full correction by glasses.

After dismissing the theory that accommodation has anything to do with the increase of myopia, since it can neither increase the intra-ocular pressure nor have any influence in producing a stretching of the membranes in the posterior half of the globe, he expresses the belief that the main factor in causing myopia, even of low degrees, is a relative thinness of the sclera in its posterior half. In this he runs counter to the views of Schnabel and Stilling, but appeals to measurements of eyes preserved in 10 per cent. formol and dehydrated with alcohol in gradually increasing strength. (Unfortunately no reference is given as to where the details of these measurements are published.) Whether this relative thinness of the sclera is in itself sufficient to cause elongation of the globe without any increase of the normal intra-ocular pressure is doubtful, but it is certain that with abnormal pressure such as may be due to the prolonged action of the extra-ocular muscles, this thinning may lead to elongation, and this applies, says Heine, even to very low myopia of one or two dioptres.

Arguing from this standpoint the desirability of full correction by glasses is insisted on on the following grounds:—First: Uncorrected or partially corrected myopes habitually screw up their eyes when looking at distant objects, and the lid pressure so caused is bad. Secondly: Since there is a physiological connection between accommodation and convergence, an uncorrected myope of 4 D., when given a book to read at 25cc. distance, in most cases brings it nearer to his eyes than this distance. One might add that, except for purposes of testing, a myope ought never to be given a book to read with print so small that in order to see it clearly with or without glasses he has to bring it so near his eyes as 10 inches. Thirdly: The frequent alternation between wearing and not wearing glasses, or between a weak and a strong pair tends in young people to produce asthenopic symptoms.

Heine, therefore, advocates what is, we believe, increasingly becoming the practice of most ophthalmic surgeons, namely, full correction for constant wear in any young myope of under

10 D. with good vision. Higher than this it is advisable to begin by ordering 2 D. less than the full myopia at first, with a supplementary glass of −2 to be added for distance. In many cases, after a time, the full correction can be worn constantly by myopes of over 10 D. At the end of the article tables and a diagram, constructed on Mr. Priestley Smith's plan, are given showing the advantage which fully or nearly fully corrected myopes have on the average over those who are undercorrected. The proportion of progressive cases in the latter category appears to be considerably larger. On the other hand, it is probable that many surgeons undercorrect progressive cases because their acuteness of vision is low. More and fuller statistics on these points are desirable.

A. H. T.

---

## CLINICAL NOTES.

Hot Water as a Local Application in Corneal Infiltration.—In the Eye Clinique at Bucharest, Manolesco has employed this simple remedy for a year or more, and he speaks very favourably of it. Cocain is given, the lids are separated by the fingers, and water at a temperature of 70-80°C is dropped into the conjunctival sac. This is continued for four or five minutes twice or more each day. The temperature in the lower cul de sac is thus raised 1°C. Any injection becomes much accentuated, but such hyperæmia passes off in from two to five hours. He is satisfied that the procedure is of considerable value in hastening the absorption of infiltration into substance of the cornea, *e.g.*, in interstitial keratitis. He has never seen any harm come of its use.—*Annales d'Oculistique*, March, 1902.

---

New Test Types.—From the publishing house of Hirschwald (Berlin) we have received some new test types designed by Kern (Berlin) and Scholz (Stettin) more particularly for use in the army. In them the letters are not arranged entirely in horizontal rows, and numbers are employed as well as letters. The descriptive pamphlet accompanying them has not succeeded in commending them to our use in civil affairs, but it is possible that they might prove serviceable to army surgeons.

Bilateral Orbital Meningocele.—De Britto reports a case of this rare affection. The child when seen was five years (? five months) of age, and free from other deformity; it was born at full time. The tumours were present at birth and had increased in size, but had never given rise to symptoms. They were oblong in shape, the long axis being vertical, and occupied the whole of the inner angle of each orbit and the side of the nose, extending down to the alæ nasi. A shallow median furrow marked the division between the two cavities. The skin over the tumours was normal, there was no pulsation to be felt. No reduction in size could be effected by pressure, nor was any pain caused thereby. The cystic nature of the swellings was very evident. No gap in the orbital wall could be felt. The diagnosis presented some difficulty, as two of the usual signs of meningocele were wanting, reducibility and pulsation. Careful puncture of each tumour was performed. A clear limpid fluid was withdrawn in a syringe, and the cysts emptied. About ten minutes later they had resumed their former dimensions. The fluid removed presented the characters of cerebro-spinal fluid, and this, coupled with the rapid refilling of the cavities, rendered the diagnosis of meningocele certain. After emptying the cysts the upper inner wall of each orbit was carefully examined, but no aperture appreciable by the finger could be discovered.—*Archives d'Ophtal.*, March, 1904.

---

Toxic Amblyopia Caused by Methyl Alcohol.—Buller has recently published notes of three cases which had come under his observation during a period of eighteen months. He thinks that this form of toxic amblyopia is not very uncommon, and is of opinion that as wood alcohol is largely used in many trades and manufactures the public should be better informed as to the danger of drinking it or of working with materials containing large quantities of it. He suggests that as methyl alcohol in not very large doses may prove fatal, it might, if labelled "poison," be used for criminal purposes; but that a statement on the label that "This liquid taken internally is likely to cause blindness" would probably have a sufficiently deterrent effect.—*Montreal Medical Journal*, January, 1904.

Bruner describes the case of a man who when "on the spree" drank an unknown quantity of a mixture of wood alcohol, water, lemon, and sugar. This made him very ill and

caused much prostration and vomiting; memory was much confused, and sight became blurred. He thought his sight improving, however, till one morning he remonstrated with a fellow-workman for waking him before daylight, when he learned to his astonishment that the sun was shining brightly. On examination the patient was found to have albumin in his urine, but no sugar; pupils were equal, semi-dilated, and failed to react to light. His vision was reduced to p.l., and even that with difficulty. The only ophthalmoscopic change discovered was that the discs were possibly very slightly hyperæmic; the vessels were quite normal. After treatment for some days with mercury, iodide, and strychnine, and sweating by pilocarpin, he improved so far as to be able to count fingers eccentrically. He had, however, an absolute central scotoma in the right eye. At first, too, the periphery of the field of that eye was not restricted, but later the margins began to creep in, and the final (?) result was $^{2}/_{45}$, eccentric fixation, and a much reduced field. The left eye never showed an absolute central scotoma, and it was able to retain rather better vision, but the field was greatly restricted. A large number of cases of toxic amblyopia from this cause are now on record, chiefly observed in America. The present writer is not aware that the condition has yet been seen in this country, but watch must be kept for them, as it is not unlikely they may be found.—*Ophthalmic Record*, February, 1904.

---

## OPHTHALMIC SOCIETY OF THE UNITED KINGDOM.

*March 10th, 1904.*

The President of the Society in the Chair.

---

### CLINICAL EVENING.

---

Cases and Card Specimens.

*Compression of the Retinal Veins by Thickened Arteries in one Eye only.*—Mr. J. R. Lunn.

Above the macular region and extending upwards from the disc, a large area occupied by extensive retinal hæmorrhages was visible, in the

midst of which were patches of white exudation. The retinal veins in many places were obstructed by their companion arteries where crossed by the latter; the superior macular vein, in particular, appeared quite blocked by the artery crossing it close to the optic disc, giving rise to several hæmorrhages in this neighbourhood. The arteries appeared small and showed the characteristic white streak indicating thickening of the vessel walls. No other changes could be made out in the fundus, and the colour of the discs was normal. The urine did not contain albumen. The loss of sight came on gradually during some five months, and attacks of giddiness had occurred during this time. No history of gout, rheumatism or syphilis could be obtained, nor had there been any injury to the eye. The patient was a smith by trade. The vessels in the other eye also showed some changes.

*Light Reflex of Pupil associated with Movement of the other Globe.*—Mr. H. B. Grimsdale.

The patient, a man aged 24, had suffered from gonorrhœal ophthalmia with the result that the left cornea became opaque after extensive ulceration. It was while tattooing this leukoma that Mr. Grimsdale first observed this peculiar reaction. On covering the right eye the pupil of it dilates, but no other abnormal movement takes place; the left eye, however, descends slowly through a distance of about 2mm. On re-admitting the light to the right its pupil contracts, and after a distinctly appreciable interval the left eye again rises up to the normal horizontal level. Dilatation of the right pupil by means of a mydriatic did not interfere with the reaction.

*Persistent patent Hyaloid Artery.*—Mr. H. L. Eason.

The patient, aged 20, a printer by trade, had suffered from defect of vision in the right eye as long as he could remember. The eye was divergent, with a constant vertical nystagmus. On examining the fundus the disc was seen to be semicircular, with its long axis horizontal, the retinal vessels, all proceeding from its lower border, being abnormally distributed; all run downwards for a short distance, and then some turn back to supply the upper quadrants of the globe. From the lower part of the disc the persistent hyaloid vessels, two in number, run forward in a loose, greyish-white sheath, straight through the vitreous to the anterior part of the eyeball. At the anterior extremity of the vessels the sheath enlarges into a convolvulus-shaped mass which is attached apparently somewhere in the region of the ciliary body below the iris. Part of this enlargement appears greyer and more transparent than the rest, with a patent vessel running upon its surface; to the right two small excrescences give this part the appearance of being

cystic. The vessels in the sheath can be readily traced as far as the enlargement, but disappear round its sides before reaching the extreme end. Some disturbance of the pigment epithelium of the retina is to be seen all over the fundus, but is most marked in the macular region.

*A Case of Albuminuric Retinitis three years after the acute attack, in which a Detachment of the Retina in each eye had spontaneously subsided.*—Mr. H. L. Eason.

The patient, a man aged 29, had been admitted into Guy's Hospital in 1900, suffering from acute tubal nephritis, with urine showing ten parts per 1,000 of albumen, and with granular casts, hæmocytes, and red-blood corpuscles in abundance. The discs and fundi at this time were normal. The patient was in the hospital for nine months with much anasarca, when the amount of albumen at times reached as high as to 28 parts per 1,000. During this time also he had several uræmic convulsions. Two months after the beginning of the attack albuminuric retinitis was noticed, and at the same time great œdema of the conjunctivæ, which protruded from between the lids. The vision was reduced to finger counting at three feet. Two months later both retinæ were found to be detached, the detachments could be seen with a +10 lens, the patient being slightly hypermetropic. When seen again, about 12 months afterwards, both detachments had disappeared, but there were several subhyaloid hæmorrhages. At the present time the discs are blurred, the vessels small in calibre, and a circle of small white patches outside the macula surrounded an olive-green mass about half a disc in diameter, over which ran a vessel apparently unconnected with the outside of the circle. Widespread disturbance of the pigment epithelium of the retina and choroid existed, and the superficial layers of the choroid were atrophic. At the lower part of the fundus numerous transparent striæ looking like cracks in the retina were visible, these being in the region of the retina previously stated to have been detached, and were probably not the "angioid streaks" which have been described, but analogous to "lineæ gravidarum" caused by the stretching of the retina when detached. The general appearance of the fundus in both eyes gave the idea of an advanced stage of retinitis pigmentosa, but the well authenticated albuminuric history put this out of the question. The vision of both eyes was $^{6}/_{36}$ with correcting glass, the field of vision for white practically full, but for colours too small to be mapped out.

*Cases illustrating Congenital Dislocation of the Lenses in five generations.* Mr. Claud Worth.

These were other members of a family showing this peculiarity, some

of whom had been previously shown before the Society, these being younger members of the family.

*Multiple Congenital Anomalies.*—Mr. N. Bishop Harman.

This patient, a girl aged five years, was the fourteenth child in a family of fifteen, of whom others were alive and apparently normal. She showed (1) a small coloboma of each upper lid; (2) the right globe possessed two dermoids; (3) the left eye showed a coloboma of the iris and also of the choroid; (4) the anterior fontanelle was unclosed; (5) on the right side she possessed two ears; (6) on the left side she possessed four ears; (7) the right side of the mouth was incompletely formed; (8) there was a large fovea sacralis (tail); (9) patient was unable to walk; (10) patient also unable to talk.

*An unusual form of Coloboma of the Choroid.*—Mr. A. Hugh Thompson.

The patient, a girl aged ten years, showed in the right fundus a coloboma of the iris directly downwards with a few tags of capsulo-pupillary membrane; the peculiar shape of the pupil had been noticed by the mother soon after birth. Near the periphery of the fundus in the same eye, directly downwards from the macula, an oval white patch could be seen, well defined at its lower margin but changing gradually into normal choroid at its upper. At this spot it looked much more like a patch of choroiditis than a coloboma. Between the lower margin of this patch and the equator a bridge of normal choroid appeared. The vision of the eye when corrected only attained $^{6}/_{18}$.

*Maldevelopment of the Suspensory Ligament and of the Lens in part.*—Mr. R. M. Gunn.

The edge of the lens, which was dislocated upwards and inwards, could be seen with a distinct notch in it; the suspensory ligament opposite the notch appeared to be entirely absent.

Reginald E. Bickerton.

---

# Bibliography.

## Anatomy and Physiology.

Agababow. Nerves of Sclera. *Archiv. fur Mikroskop. Anat.*, 63-4
Dean and Usher. Course of optic fibres. *Brain.* Winter, 1903.
Edridge-Green. Theories of colour vision. *Med. Press and Circular*, 6th April.
Halben. Formation of Descemet's membrane: Buphthalmos. *Archiv. f. Augen.*, March.
Laquenr. Cerebral Representation of the macula. *Virchow's Archiv.*, 175-3.
Parsons. Neurology of vision. *Lancet*, 16th April.
Paterson. Observations on lymph flow through the eyeball in man and certain animals. *Journal of Pathology*, March.
Zietzschmann. The structure of the eyelids of domestic animals. *c. Graefe's Archiv.*, 58, 1.

## Congenital Abnormalities.

Galezowski. Congenital aniridia. *Rev. d'Ophtal.*, March.
Heine. Peculiar congenital malformation of the eye. *v. Graefe's Archiv.*, 58, i.

## Hygiene.

Dauber. Prophylaxis of ophthal. neonat. *Münch. Med. Woch.*, 7, 1904.
Neuburger. The type in schoolbooks. *Woch. f. Ther. u. Hyg. des Auges.*, vii., 26.

## Pathology and Bacteriology.

Evans. Bacterial diseases of conjunctiva *Ophthalmoscope.* April.
Ischreyt. Pathological anatomy of the lachrymal apparatus. *Arch. f. Augen.*, February.
Nakagawa. Experimental inoculation of tubercle in cornea. *Archiv. f. Augen.*, March.

## Instruments and Apparatus.

Castello. Apparatus for detection of malingering. *Ind. Med. Gazette*, March.
Hill and Muller. Apparatus for hot compresses for the eye. *Woch. f. Ther. u. Hyg. des Augs.*, 29.
Hulen. A simple, accurate, and rapid method of localizing foreign bodies in the orbit. *Journ. American Medl. Assoc.*, 2nd April.
Noiszewski. Forceps for pterygium. *Cent. f. Augenheilkd.*, March.
Wolff. Electric skiascopophthalmometer. *Arch. d'Ophtal.*, April.

## Therapeutics.

Darier. Antitoxic serum for ulcer of cornea. *La Clin. Ophtal.*, 6, 1904.
Hosch. Subconjunctival injections. *Archiv. f. Augen.*, March.
Maurizi. Mirmol in recurrent epithelioma of lids. *Bull. dell'Osp. Oft.*, Rome, March.
Peschel. Subconj. injections of alcohol. *Amer. Jl. of Ophthal.*, February.
Sommer. Oily collyria. *Woch. f. Ther. u. Hyg. des Augs.* 28
Stefani. Action of atropin on the pupil after prolonged use. *Arch. ital. de Biol.*, 41-1.

## Operations.

Gelpke. Results of Extraction of lens. *Archiv. f. Augen.*, February.
Schulte. Hotz's operation for entropion. *Ophtal. Klinik.*, 7.
Wood. Preparation of patient for cataract extraction. *Internat. Clinics*, 1904.

## Traumatisms.

## Tumours.

Alt. Unpigmented sarcoma of iris. *Amer. Jl. of Ophtal.*, February.
Maurizi. Epithelioma of eyelids: mirmol. *Bull. dell. Osp. Oft.*, Rome, March.

## Sympathetic Ophthalmia.

Bruner. Sympathetic ophthalmia. *Cleveland Medical Journal*, March.
Raehlmann. Sympathetic ophthalmia. *Deutsche Medizin. Woch.*, 13, 1904.

## Glaucoma.

Valude. Acute glaucoma. *Internat. Clinics*, 1904.

## Amblyopia and Visual Defects.

Pino. Erythropsia. *v. Graefe's Archiv.*, 58, i.

## Refraction and Optical Questions

Donaldson. Utilising the eyelids to improve vision in ametropia. *Ophthal.*, April.
Grimsdale. Continued paralysis of accommodation. *Ophthal.*, April.
Koster. Presbyopia in young persons. *Archiv. f. Augen.*, March.
Le Mehauté. Examination of sight, &c., in daily practice. *Archiv. de Med.: Nervale*, January.
Weinhold. Paradoxical parallactic movements of stereoscopic images. *v. Graefe's Archiv.*, 58, i.
Wolff. Theory of skiascopy. *Archiv. d'Ophtal.*, April.
Wolffiin. The operation for myopia. *Corresp. f. Schweizer Aerzte.*, 1904, 6.

# Regional Affections.

## Eyelids.

Cange and Bentami. Treatment of trichiasis. *Archiv. d'Ophtal.*, April.
Schulte. Hotz's operation for entropion. *Ophthal. Klinik.*, 7.

## Lachrymal Apparatus.

Hosch. Concretion in canaliculus. *Archiv. f. Augen.*, March.
Ischreyt. Pathological anatomy of the lachrymal apparatus. *Archiv. f. Augen.*, February.
Wiener. The modern treatment of dacryo-cystitis. *Medical Record*, April 2, 1904.

### Conjunctiva.

Dauber. Prophylaxis of ophthalmia neonatorum. *Munch. Med. Woch.*, 7, 1904.
Evans. Bacterial diseases of conjunctiva. *Ophthal.*, April.
Jablkowski. Local application of iodine in trachoma. *Wiener Medizin. Presse*, 14.
Kaufmann. Blue coloration of conjunctiva and cornea. *Die Ophtal. Klinik.*, 6, 1904.
Magnani. Actinomycosis of conjunctiva. *Giorn. della R. Accad. di Medicina*, Turin, January.
Shieck. Pathological anatomy of spring catarrh. *v. Graefe's Archiv.*, 58, i.
Ulbrich. Tumours of conjunctiva. *Ophthal. Klinik.*, 7.

### Cornea and Sclerotic.

Darier. Antitoxic serum for ulcer of cornea. *La Clin. Ophtalmol.*, 6, 1904.
Halben. Buphthalmos: formation of Descemet's membrane. *Archiv. f. Augen.*, March.
Stieren. Acquired hydrophthalmos. *American Medicine*, 2nd April.
Ziegler. Corneal ulceration due to nasal infection. *American Medicine*, 9th April.

### Iris and Ciliary Body.

Alt. Unpigmented sarcoma of iris. *Amer. Jl. Ophthal.*, February.
Hilbert. Iritis following sting of bee. *Woch. f. Ther. u. Hyg. des Auges.*, vii., 26.
Hosch. Spontaneous rupture of globe in sarcoma of uvea. *Arch. f. Augen.*, March.

### Lens.

Bordeaux. Partial zonular cataract. *La Clin. Ophtal.*, 6, 1904.

### Choroid and Vitreous.

### Retina.

Elschnig. Retinal diseases in nephritis. *Wien. Medizin. Woch.*, 11.
Hosch. Toleration of foreign bodies by retina. *Arch. f. Augen.*, March.

### Optic Nerve.

Genth. Complete destruction of optic nerve. *Arch. f. Augen.*, February.

### Muscles (and Strabismus).

Altland. Chronic progressive ophthalmoplegia. *Arch. f. Augen.*, February.
Baas. Paralysis of external muscles from atropin poisoning. *Arch. f. Augen.*, February.
Cuperus. Curability of nystagmus. *Archiv. f. Augen.*, February.
Thomson. Three cases of ocular paralysis. *Glasgow Med. Journ.*, April.
Wilson. Eye muscles in organic hemiplegia. *Rev. of Neurology and Psychiatry*, April.

### Orbit.

Heerfordt. Emphysema of orbit. *v. Graefe's Archiv.*, 58, i.
de Lapersonne. Thrombosis of orbital vessels. *Gaz. des Hôpitaux*, 31st March.
Marshall. Hydatid cyst of orbit. *Ophthal.*, April.
Perthes. Rontgen rays in diagnosis and treatment of osteoma of frontal sinuses. *Archiv. fur Klin. Chirurg.*, 72-4.
Purtscher. Purulent tenonitis. *Cent. f. Augen.*, March.
Truc. Tumour of orbit, with symptoms of Graves' disease. *Die Ophthal. Klinik.*, 6, 1904.

### Relations with Medicine.

Bray. Postdiphtheritic paralysis of accommodation. *N. Y. Medical Journal*, 5th March.
Elschnig. Retinal diseases in nephritis. *Wien. Medizin. Woch.*, 11.
Enslin. Eye changes in "sugar-loaf" head. *v. Graefe's Archiv.*, 58-1.
Hirsch. Gonorrhœa of the eyes. *Munch. Med. Woch.*, 11, 1904.
Nance. Dental disease, causing ocular disturbances. *Jl. Amer. Med. Assoc.*, 2nd April.
Nelson. Asthenopia and headache from eye strain. *N. Y. Med. Record*, 19th March.
Neuburger. Syphilis in parent and child. *Cent. f. Augen.*, March.
Spratling. Eye strain and epilepsy. *American Medicine*, 9th April.

### Miscellaneous.

Cantonnet. Variations in volume of normal and glaucomatous eyes, along with alterations in molecular condition of blood. *Arch. d'Ophtal.*, April.
Greeff. Action of radium on the eyes. *Deutsche Medizin. Woch.*, 13, 1904.
Hamburger. Ought one to withhold a bad prognosis in eye disease? *Deutsche Med. Woch.*, 13, 1904.
Hilbert. Yellow vision from santonin. *Die Ophtal. Klinik.*, 6, 1904.
Kiernan. Forensic eye aspects of tabes. *Medical News*, 19th March.
Kuwahara. Action of aniline dyes. *Archiv. f. Augen.*, February.
Mettey. Electric light injuries. *Archiv. d'Ophthal.*, April.
Neuburger. Refutations for manufacture of lenses (Antiquarian), *Janus*, March.
Schaefer. The poet Jung-Stilling and Ophthalmology. *Ophthal. Klinik.*, 7.
Stephenson and Chaldecott. Ethyl chloride as an Anæsthetic. *Ophthal.*, April.

# CASE OF ORBITAL MUCOCELE, OPERATED ON BY KRÖNLEIN'S METHOD.

By H. R. Swanzy, F.R.C.S.I., *Surgeon to the Royal Victoria Eye and Ear Hospital, Dublin.*

Kate Fitzsimonds, æt. 54, was admitted to hospital on the 18th November, 1903. Her right eyeball was protruded forwards and slightly downwards (Fig. 1), its motions were free in all directions. She had no pain, nor had she had any, the ophthalmoscopic appearances were normal, and the vision was $^{6}/_{9}$. She stated she had first noticed the prominence of the eyeball three months previously. On palpation in the orbit below the supra-orbital margin, the presence of a soft elastic tumour could be ascertained. The diagnosis lay, I thought, between a tumour of the sheath of the optic nerve, a cyst, and a mucocele. The age of the patient spoke against the first of these.

For the relief of the condition I proceeded, on the 17th December, 1903, to perform a temporary resection of the outer wall of the orbit, as described by Krönlein, of Zürich. While making, with chisel and mallet, the first bony incision, namely that through the base of the external angular process of the temporal bone, a quantity of turbid mucus welled up into the wound, showing that a mucocele was the condition present. I continued the incision and carried out the other steps of the operation, except the horizontal division of the separated periosteum, which, of course, was not here required. On reflection of the flap of bone and soft parts, a good view into the cavity occupied by the mucocele could be obtained, and it was found to extend into the frontal sinus and into the ethmoidal cells, in the latter of which it had probably originated, although data for a definite opinion on this

point are wanting. The mucous contents of the cavity amounted to about 4oz. The cavity was flushed out with sterilised saline solution, and its walls were in parts dissected away, and elsewhere curetted. A packing of iodoform gauze having been inserted, the flap was restored to its position, and the wound closed in the usual way, except at the outer end of the eyebrow, where an opening for drainage was left. The cavity was washed out daily and dressed with iodoform gauze for twelve weeks. At first there was a considerable sero-mucous discharge, which diminished as the cavity gradually contracted. On the 20th April, 1904, eighteen weeks after the operation, the patient was sent home, the cavity having closed, while the superficial cicatrix was but slightly disfiguring (Fig. 2). The protrusion forwards of the eyeball had quite disappeared, but the displacement downwards remained, and between the eyeball and the supra-orbital margin a rather deep sulcus was present. The vision was $^{6}/_{9}$, and the ophthalmoscopic appearances were normal.

Although Krönlein's operation has been frequently performed on the Continent, yet the only other British cases recorded are one by Dr. Pockley, of Sydney,[1] and one by Mr. Louis Werner, of Dublin.[2]

[1] *Austral. Med. Gazette*, Oct., 1901, p. 11; and *Archives of Ophthalmology*, xxxi., p. 114.

[2] *Trans. Ophthal. Soc., U.K.*, xxiii., p. 77.

---

## ORBITAL SARCOMA: KRÖNLEIN'S OPERATION.

By F. P. Maynard, M.B., F.R.C.S.,
*Major, I.M.S.; Civil Surgeon of Darjeeling.*

A hindu male, aged 22, was admitted to the Mayo Hospital, Calcutta, on June 9th, 1902, suffering from a swelling under the

FIG. I.

FIG. II.

left upper eyelid, causing proptosis. It had been noticed for two years. His general condition was good, but his sight in the left eye was poor. Through the upper lid could be felt a round, soft, elastic tumour, larger than a walnut, uniform in consistence. On raising the upper lid the tumour could be seen through the conjunctiva, distended vessels crossing its surface. It was not movable, and appeared to be fixed to the upper wall of the orbit. The eyeball was displaced downwards and forwards and was compressed by it. It moved laterally, but not vertically. The disc was oval and swollen, the media hazy, and the vision reduced to counting fingers at one foot.

*Operation.* On June 11th, under chloroform, the upper fornix and outer canthus were divided, but as it was found impossible to get at the tumour properly, Krönlein's operation was performed. The incision was carried upwards and downwards, and then curved backwards, forming a semi-circle with the concavity towards the hair, the whole incision being shaped like a pitchfork, and carried down to the bone. The external angular process of the frontal bone was then sawn through with a Hey's saw near its base, the orbital contents with the periosteum being first pushed inwards away from the outer wall, and a spatula inserted to protect them from the saw. The vertical cut posteriorly from the deepest portion of the saw cut towards the spheno-maxillary fissure was then attempted with a chisel. It proved very difficult, and could not be completed. So the third division of bone was proceeded with, and the frontal process of the malar bone was divided by Hey's saw. The square piece of bone thus marked out was then bent outwards, and the orbit well exposed. The periosteum was cut with scissors from before backwards, and the tumour, which was the size and shape of a hen's egg, extending backwards to the apex of the orbit and encapsuled, was then easily removed with but little bleeding. It was not necessary to divide the

external rectus muscle, and the optic nerve was not seen at all. The conjunctival fornix was closed with two catgut sutures, the rest of the wound with silkworm gut, a horse-hair drain being passed to the apex of the orbit and brought out at the posterior end of the lower limb of the wound, *i.e.*, over the zygoma. The eyelids were sewn together by a single median stitch to protect the cornea. The eye was rather injected at the end of the operation, but the pupil was contracted and the globe in its natural position. The tumour had a capsule, and on section seemed pigmented and very vascular. Microscopically, it proved to be fibro-sarcoma.

With the exception of a temperature of 101·4° the evening of the operation, and considerable chemosis and swelling of the lids for a few days, recovery was uneventful, and the wound healed well, leaving a linear scar which was hardly noticeable. A fortnight after the operation the sight was normal, and the disc natural in appearance; the eye was in place, and its movements good. The patient was discharged cured on July 4th, a little more than three weeks after the operation.

*Remarks.* Krönlein performed his first operation in 1886 for the removal of a dermoid cyst, and published a description of it in 1889.[1] Domela-Nieuwenhuis, in 1900, published a very complete monograph on the operation (150 pages) in the same journal, which is one devoted to general surgery:[2] indeed, it is rather remarkable that the operation seems to have found greater favour so far with general than with ophthalmic surgeons, at any rate to have been more often performed by them. Altogether Krönlein's operation appears to have been performed forty-eight times—twice in England (Lawford and Stephenson),[3] once in Ireland (Werner),[4] and twice in the Colonies.[5] Of the forty-eight, in twenty it was done for tumours of

the optic nerve. In the rest it was done for tumours, injuries and foreign bodies, retro-bulbar abscesses, tapping the sheath of the optic nerve, and pulsating exophthalmus. It has been proposed for Graves' disease, posterior sclerotomy, and for diagnosis. Röhmer tried to remove the ciliary ganglion for absolute glaucoma by this method.

Various modifications have been made in the details of the operation. Parinaud and Roche (1901)[6] made the incision concave forwards so as to leave the scar more in the hairy scalp. Pockley[7] also modified the incision and used a circular saw attached to a dental machine for cutting through the bones. Axenfeld[8] has invented special instruments to assist in performing the operation.

The advantages of Krönlein's operation are the excellent view of the parts obtained *in situ*, and the possibility of dissecting out the growth with a minimum amount of injury to surrounding structures. The eye can be more often preserved, and when preserved it is less likely to undergo atrophy from not having been roughly handled during the operation, as it is of necessity in removing a tumour in the ordinary way from in front. As Knapp has remarked, whatever difficulties may arise from the size of the tumour, or from hæmorrhage, would be accentuated in the older method of operating. They are all more easily dealt with by resection of the outer wall of the orbit. If any sight has remained before operation it has usually, as in the present case, improved after it. Infection from the conjunctival sac cannot occur as the sac is not opened. In the present case it was opened because removal through it was at first thought possible. The drawbacks to the operation are few and unimportant compared with the advantages. Death has only once followed, and was then due, not to the operation, but to intra-cranial growth of

the tumour. The scar is linear, and barely visible. If made partly in the hair it is even less apparent. Loss of mobility and a certain degree of exophthalmus may occur, especially where the tumour is large and the external rectus much interfered with. In some cases these drawbacks have diminished with the lapse of time, and in any case they are almost certainly less than after removal from the front with the greater bruising entailed by that method of operation.

The operation only requires to be better known to be more widely adopted. No one, I feel confident, who has had experience in removing orbital tumours in the ordinary way, and then tried Krönlein's operation, will have any doubts about its great superiority.

REFERENCES.

[1] KRÖNLEIN. *Beiträge zur Klin. Chirurg.*, 1889, Bd. iv.
[2] DOMELA-NIEUWENHUIS. *Loc. cit.*, 1900, Bd. ii. and iii. Abstracted in the *Ophthalmic Review*, 1901, Vol. xx., p. 7.
[3] LAWFORD and STEPHENSON. *Trans. Ophth. Soc.*, Vol. xxiii., p. 108.
[4] WERNER. *Loc. cit.*, p. 77.
[5] POCKLEY. *Austral. Med. Gazette*, Oct.., 1901, p. 11; and *Montreal Medical Journal*, Oct., 1900.
[6] PARINAUD and ROCHE. *Annal. d'Oculist*, 1901, cxxiv., p. 175.
[7] POCKLEY. *Loc. cit.*
[8] AXENFELD. *Trans. Heidelberg Ophthal. Soc.*, 1901.

---

## REVIEWS.

GELPKE. **On the Final Results of Removal of the Lens in Myopia.** *Archiv für Augenheilkunde*, February, 1904.

THE author's experience of this operation extends over ten years, during which time he has operated on 169 myopic eyes. As the paper deals only with the final results of the operation, all those cases are excluded from consideration which were lost sight of after the operation, and also all those on whom

the operation was performed within the last two years. In the case of 120 eyes operated on (as both eyes were operated on in 32 cases, the number of patients was 88) Gelpke was able to watch the results for a period varying from two to nine years, and these results are here recorded. Of the 88 patients, 40 were male and 48 female. All ages were represented, the youngest being 6, the eldest 59, but the majority of the patients were between 16 and 25. In the case of more than half of the operations the results were watched for over four years.

Comparing, in the first place, the acuteness of central vision with correcting glasses before and after operation, out of the 120 eyes operated on the vision was destroyed or made worse in nine, and remained the same in four. In the remaining 107 it was improved, the improvement being in many cases twofold and in a few ten or twentyfold. A certain amount of pseudo-accommodation was noted in these cases, and its range, the patient wearing the glasses most suitable for near vision, appeared to vary, first according to age, those younger than 16 being decidedly superior in this respect to those over 40, and secondly, according to intelligence, educated persons having a greater power of interpreting blurred images than uneducated. In most cases the range of pseudo-accommodation compared favourably with the range of physiological accommodation previously existing.

With regard to the field of vision, it remained the same in the majority of cases, but in 35 per cent. an improvement is claimed, while in 5 per cent. a diminution followed on account of the occurrence of high tension or detached retina. No further details are given of the cases in which an improvement is claimed. Would it have been found if the patients had been wearing periscopic glasses when being tested prior to operation?

The alteration in refraction caused by the operation averaged 21 D. In 19 patients who were rendered emmetropic the average previous myopia was 20·5, a figure which is remarkably high. The estimation was by the direct method, and in high myopia it is difficult to believe that this can be so accurate as retinoscopy, which in this country most of us employ. The corneal astigmatism was slightly increased in rather more than half the operated eyes, in the rest it remained the same or was diminished.

The more interesting and important part of the paper deals

with the influence of the operations on fundus changes and the details of those cases in which the eye went wrong. Although 92 of the eyes operated on showed fundus changes more extensive than a mere crescent, in only two of them was any increase of these changes noted after operation. In one case, a boy, whose first eye had gone wrong after operation through infection, had his second eye operated on, and during the second year afterwards this eye suffered from central chorio-retinitis. The author surmises that this inflammation was of a sympathetic nature, for the condition improved after enucleation of the blind eye. In a second case in which there were macular changes before operation, it appeared to give rise to a fresh macular inflammation, which, however, was of only a few weeks' duration and involved no permanent deterioration of sight. In fact, in none of the nine cases in which the sight was lost or made permanently worse was the bad result due to this cause. On the other hand, in many cases the effect of the operation on the condition of the fundus appeared to be decidedly beneficial. In 11 cases there was a definite absorption of peripheral foci of chorio-retinal exudation. In seven cases of old macular affection the vision was improved, and in three cases of *recent* macular affection there was marked improvement both ophthalmoscopically and subjectively.

An interesting point is the effect of the operation on the growth of the long axis of the eye, and here it is somewhat surprising to be told that, tested objectively, there was no increase of the axis in any single case after operation, whereas in 88 non-operated eyes belonging to patients who had been operated on in one eye, no less than 50 showed an increase of refraction varying from 2 to 6 dioptres in the course of a few years.

With regard to complications, those occurring in immediate connection with operation need not be dwelt on. A prolapse of vitreous at the evacuation occurred seven times, but was only serious in one case where irido-cyclitis ensued. A serious complication occurring at a later stage in elderly persons was secondary glaucoma, and this may, says Gelpke, need prompt operative procedure—sclerotomy or iridectomy.

The serious complications which led to the loss or permanent deterioration of the eye in nine cases were as follows:—Primary infection accounts for two cases, and secondary

infection, due to an attack of delirium tremens after operation, accounts for a third. Irido-cyclitis accounts for three more. One of the cases was that of a woman of 57, on whom an extraction with iridectomy was performed. Vitreous escaped, and the iris remained entangled in the wound. A second case was that of a patient who, after a successful operation on his first eye, insisted on returning to work too soon after the operation on the second one.

This leaves only three eyes which were lost through the complication which is perhaps most dreaded by English operators, namely, the detachment of the retina. In truth, it occurred in five cases, three of them in the first year after operation, two in the second, but in two cases the detachment was traumatic, was slight, and was cured by appropriate treatment, leaving vision of $^{8}/_{10}$ and $^{6}/_{10}$ respectively, after being under observation for eight years. One of the three serious cases is attributed to the patient's employment (field work in great heat in a stooping position). The second case was one in which there were choroidal changes at the equator—a more serious condition in the author's opinion than central changes. Loss of vitreous at the operation was followed by cyclitis, high tension, detached retina, enucleation. The third case was one in which some toughish capsule was divided eight weeks after the evacuation. Six months later a detachment occurred.

The period during which the author considers it necessary to watch his cases before he is justified in speaking of a permanent success is two years. In 25 out of 109 eyes, some deterioration took place during this period, counting from the date of the first operation. The cases due to central choroiditis and detached retina have already been spoken of. In two cases the cause was optic atrophy, but in the majority (17 out of 25) it was a secondary cataract demanding a fresh needling.

As will be gathered, the author is a strong advocate of the operation in all suitable cases, and his test of suitability is startlingly inclusive. Whereas surgeons in England seldom operate on cases of myopia lower than 16 D, he has no scruple in operating on cases considerably lower when the myopia is progressive, so that his patients may have to wear plus glasses even for distance after operation. He would operate at any age, though he prefers to operate on children. Macular

changes he regards as an indication in favour of rather than against operating. Detached retina he looks upon not as an unavoidable consequence, but as a result either of a faulty technique or an unwise selection of cases. The most important contra-indication that he admits is an inflammatory chorio-retinitis in the equatorial region. A detached retina in one eye is no contra-indication against operating on the other. Since he believes in the effect of the operation being to improve the nutrition of the eye, if one eye is blind there is all the more reason to operate on the other.

As to the technique of the operations, his ideal is a single discission, leaving nature to do the rest. In children this ideal is occasionally attained, but in the vast majority of cases an evacuation and sometimes a subsequent capsulotomy are necessary. In about one-tenth of his cases more than three operations were performed. In the primary discission he rightly mentions the importance of preserving the posterior capsule intact. He has tried various methods, and at present when operating on adults adopts the plan of making an incision with a lance-knife 4mm. long, 1 to 1½mm. inside the limbus, and removing the anterior capsule with capsule forceps.

Finally, discussing the question of operating on the second eye, he finds that out of 56 patients who had had the monocular operation, only 17 used the non-operated eye for near vision, and many of the remainder complained of troublesome diplopia (!) He therefore approves, as a rule, of operating on the second eye, but only after an interval of two years from the date of the operation on the first. In as many as 20 per cent. of the patients who had had the double operation, binocular vision was obtained.

As will be seen, there is a great deal of controversial matter in this paper. The points on which it seems specially desirable to gather further information are (1) the influence of the operation on fundus changes; (2) its alleged influence in stopping the growth of the long axis of the eye; and (3) the frequency with which detachment of the retina takes place, and also the period after the primary discission when the eye may be considered safe. That this is longer than two years the reviewer has recently had evidence.

A. H. T.

---

E. S. London (St. Petersburg.) **On the Action of Radium Rays in Relation to Vision.** *Archiv für Ophthalmologie,* 1903. Bd. 57. Ht. 2.

When the eyes are covered with a black bandage for five or ten minutes so as to accustom them to the dark, and radium enclosed in a small box is held at a distance of ten to fifteen centimetres in front of one of them, it is found that a sensation of light is experienced by the eye before which the box is held, and that it becomes more intense the nearer the radium is brought to the eye and the greater the amount of radium contained in the box. The same impression is experienced in the other eye, but to a much less marked degree. When only one eye is bandaged it behaves in the same way to the radium rays, but in the uncovered eye there is no reaction.

The box itself and the radium are not visible in these experiments, and generally visual acuteness under the influence of the rays is not in the least increased. Giessel was the first to remark the sensibility of our eyes to the Becquerel rays. He also made out that the radio-active substance enclosed in a thin walled lead pipe called forth a light impression when it was laid on the closed eyelids. Himsted and Nagel have shown that the cornea, lens, vitreous, and retina fluoresce under the influence of radium and have ascribed to it the sensation of light produced by the radium. The source of the light sensation appears to lie in the fluorescence of the retina and probably the rods are the percipient elements.

The lens, when newly removed from the eye and exposed to radium rays, fluoresces. In a case with aphakic eye it was found that when exposed to radium rays the eye without its lens received a stronger light impression than the normal eye. In another case a stronger light impression was received by an eye with ripe senile cataract than by the other normal eye. The explanation of these cases may be that the lens has the faculty of arresting the radium rays, as, moreover, has been proved in connection with the Röntgen rays. The cornea, though quite opaque, does not interfere with the characteristic influence of radium on the eye.

The writer carried out his investigations in the following order:—The individual for examination was put in a totally dark room, and after from three to fifteen minutes, when the eyes were adapted for the dark, a black bandage was placed on

the eyes and a light lit. If the eye has had sufficient time to become adapted to the dark, it thereby perceives no light.

When investigating the effect of radium on the optic centre in the occipital lobe a large amount of radium was used in some cases, usually from 60 to 75 milligrams (for all other cases 30 milligrams were used). In some dozens of cases it was found that when the box containing the radium was brought in contact with a certain spot on either side of the occiput the sensation of a feeble phosphorescent light was experienced; it is characteristic that the light is not located at a certain spot and is not referred to the eye. Most probably there is a central irritability.

In a dark room, or when the eyes are covered by a black bandage, one is unable to see objects exposed to radium rays because the rays partly pass through the object, and are partly absorbed in its substance, and because there is no reflection of the rays from the surface of the object, neither are they refracted.

When the radium is held higher than the eye, chiefly the lower half of the retina is illuminated and the light is judged to come from above; similarly when the radium is moved into another situation, the movement itself is detected, and, with practice, simple figures—triangles, squares, etc.—formed by movement of the radium can be recognised.

In his investigations to determine whether radium might not be employed by producing optical representations to assist those who could not see, it was found that its direct action was not trustworthy, so its indirect action was tried. He used a barium platinocyanide screen which radium rays cause to fluoresce. The fluorescence of the screen is appreciated better at the periphery than at the centre of the field of vision. If in a room which is quite dark a screen is illumined by radium and a strip of black paper is laid on it, then all the necessary conditions are present for bringing out in the best way the perceptive faculty in eyes ordinarily blind. Or the screen may be covered with a sheet of black paper from which a strip has been cut out; in absolute darkness the fluorescent strip is easily distinguished.

Those who are only able to distinguish light from darkness owing to opacity of the media or atrophy of the retina are able to distinguish the black strip on the fluorescent screen or the bright strip on the dark screen. It may happen that the

individual under investigation has never had the use of his visual organs, and is not in a position to comprehend the form of the shadows; in such case one may either name them to him or induce him to indicate the direction of the shadows with his fingers in the air, or objects may be learnt by tactile sensation. In this way a certain class of blind people can be taught to read with their eyes. Owing to individual variation the illumination, the size of the figures on the screen, and the distance between the figures must be adapted for each case. The learner should hold the screen in his hand so that he may place it at the most favourable distance from his eye. It is necessary to hold it near the eye.

The writer was careful in his investigations to keep the radium as far from the eye as possible and to make the sittings short. That the rays may have an injurious effect on the eye tissues is shown by experiments made by him on animals. The radium box was placed for three hours on the closed eye of a rabbit; for three weeks nothing abnormal was observed, but during the fourth week the lids became necrotic and the cornea opaque, and there was also a central retinitis. The right eye of a guinea-pig was exposed to radium rays for two days at a distance of ten centimetres from the radium box. After a month the right eye was completely atrophied.

As regards the effect on the human eye Grumnach found that working with radium caused signs of retinal irritation.

If the radium box is laid directly on the back of the screen, a fluorescent spot appears on the anterior surface. Blind people with perception of light see the spot at a certain distance, and when the spot changes its position they can define the movement accurately and could also reproduce it.

The new method of instruction, which may be termed the "silhouette" method, is suitable for blind persons with perception of light, no matter whether the origin of the blindness is in the nerve mechanism of the retina or in the transparent media of the eye.

A detailed account is given of the teaching of three patients who lost their sight during the first year of life. Two of these had optic atrophy, the result of congenital hydrocephalus, the other had adherent leucomata, the result of ophthalmia neonatorum. The vision in these cases was reduced to perception of hand movements. They first learnt to distinguish letters, then syllables, and finally words. They were also

taught to write by following with the finger the bright spot which was produced by the radium at the back of the screen.

No complication resulting from the investigations was complained of by the author's pupils.

C. H. U.

---

GREEFF (Berlin). **The Effect of Radium Rays upon the Eye.** *Deutsche Medizinische Wochenschrift*, March 13, 1904.

THE first part of this interesting paper does not call for special note, as it deals with the now fairly well-known facts regarding the general behaviour of radium; we pass on to the more definitely ophthalmological section. It appears that a paper by London appeared in a lay Viennese journal, and was entitled "Hope for the Blind." The prospects therein held out of the eventual recovery of sight by means of radium by those in that unfortunate condition had, of course, the effect of stirring up great interest in the matter (sometimes in a very unfortunate manner), and Greeff was requested by the authorities to go thoroughly into the subject with the view of ascertaining what measure of benefit was likely to be obtainable. The primary difficulty was naturally that of procuring the necessary radium, but that having been got over, the next point was to examine the effects of radium upon the normal eye. The first and chief fact about radium is the unprecedented one that it constantly and unceasingly gives out light in the dark, and this without loss of substance. Of this light there are two distinct effects, viz. (a) that radium causes certain substances to become fluorescent, and (b) that radium sends out its own special light rays. London seems not to have sufficiently differentiated between these two. The capacity for imparting fluorescence to other substances, *e.g.*, the barium-platinocyanide screen, may be shown by bringing the radium preparation behind one of those in absolute darkness, when at once one has the impression of a beautiful diffused illumination; it is to be noted carefully that when this is taking place the eye is not seeing any actual rays from the radium. The light rays which are thus given are amenable to the ordinary rules of ordinary light rays. It is the same as if the light were coming from an ordinary lamp, only that the source of light here is the preparation of radium, not a "light" in itself,but for all that capable of producing this effect immediately without need of

replenishment. The actual radium rays may be seen by bringing the radium in a leather pocket to about 10cm. from the eyes, which have been allowed to become adapted for darkness (leather not being capable of frustrating the experiment by itself becoming fluorescent). The eye then suddenly begins to perceive a strange diffuse sea-green light; this becomes more intense the nearer it is brought to the eye, but very curiously one cannot "project" this light, *i.e.*, one is unable to say whether it comes from below or above, &c.; one is merely conscious of the presence of the light. In this matter Greeff contradicts London entirely. It appears also that these light rays penetrate the eye in every direction, and through any of its tissues indifferently. It matters nothing whether the radium is held straight before the eye or resting on the temporal bone. Nor does holding the hand over the radium make any difference, the light passes through all the tissues, through bones just as readily as soft parts. Even a metal plate is not "opaque" to the radium, but is penetrated by its rays; the difference in this matter between radium rays and Röntgen rays is thus manifest. To explain this light perception by the eye it has been suggested that the lens may be made fluorescent by the radium, and the retina being then stimulated by the rays emanating from the lens, light is perceived. Examining fresh pigs' eyes under proper precautions to prevent fluorescence of the coverings of the radium, Greeff was able to detect with certainty a feeble fluorescence. Radium can, however, also act directly upon the retina, as is shown by its action in bleaching visual purple in the dark.

When we turn to the question of the effect or influence of the rays upon the blind, we are at the outset met with the difficulty: What is a blind eye? Taking it in the first instance to mean an eye which has absolutely no perception of light, which cannot see lightning, in London's picturesque if somewhat sensational phrase—upon such an eye, so far as vision is concerned, radium has no influence whatever. In the case, however, of patients whose condition is not so extreme some gain is occasionally to be got. Thus, when an eye, internally healthy, is "blind" from opacity of the cornea, since to the radium rays opacity or transparency makes no difference, the fluorescence is quite discernible; but as these rays are also not refracted, no true images can be formed on the retina. By the interposition of letters of large size, cut out of metal,

behind the fluorescent screen, such an eye may be made to read letters; or crosses, circles, &c., can be recognised. The same result, however, could be attained in these eyes by a similar utilisation of opaque screens and an ordinary light, for the "light" perceived was that of the barium screen, and was not radium rays at all. The hopes, then, which London by his article has raised in the minds of the blind are not based upon any real foundation, in Greeff's opinion, and it would have been well had the matter been more fully considered before London had promulgated his views.

W. G. S.

---

Baudry (S.). **Forensic Questions Involved in Injuries of the Eye.** *(Etude Médico-légale sur les traumatismes de l'œil)*, 3rd Edition. Paris: Vigot Frères.

The first chapter of this book is devoted to the injuries of the superficial parts of the eyes and its appendages, the second to those of the orbit. Points of medico-legal interest and importance are met with on almost every page, as examples of which we may cite the following:—Blows on the lids with a fist or blunt instrument may produce wounds identical in appearance with those caused by cutting weapons—ecchymosis in the eyelids, alarming in extent but harmless in its results, may appear immediately after a blow; a smaller amount of extravasated blood appearing later may be of much more serious import and indicate a deep lesion of the orbit such as a fracture of its roof—the tarso-orbital fascia prevents blood from a superficial wound finding its way into the orbit; an orbital hæmatoma means a lesion of the cavity, probably a fracture, if the violence was imparted by a blow or a fall. We can hardly agree with the conclusion that fractures of the orbital vault are less fatal when the orbital margin is involved than when it escapes, owing to the violence being in part neutralised by the thick orbital rim; a large proportion of the latter class of cases is probably formed by punctured fractures. More stress might have been laid on the importance of early diagnosis of such cases and the urgent necessity of treating them on the best surgical lines without delay. We notice that Baudry deprecates the use of the probe in the investigation of suspicious cases of this class; properly used we hardly think it

can be open to serious objection. It is pointed out that laceration of extra-ocular muscles involves, as a rule, an irremediable interference with functions which materially diminishes a man's capacity as a workman; the resulting diplopia may make it necessary for the injured eye to be kept permanently covered, so that the trade value of the workman is reduced to that of a one-eyed man. Interesting examples of foreign bodies accidentally lodged or deliberately inserted in the orbital cavity are given, some at great length. The question of reflex amblyopia after blows is discussed, and the diagnosis and prognosis of retro-bulbar affections of the optic nerve. In the second part of his book Baudry deals with injuries of the eyeball itself. A good deal of repetition results from discussing the question of retained foreign bodies according to the particular tunic or content of the globe in which they finally lodge. Baudry is not very enthusiastic as to the use of the magnet, and is by no means impressed with the giant magnet. He is quite French in his precision when he states that it is the duty of the expert to make allowance in favour of the employer if a workman whose eye suppurates after a perforating wound is in a bad state to resist infection owing to alcoholism, diabetes, or unfavourable local conditions, but that his bias should lean towards an employé injured by a splinter from a tool which is badly tempered.

Part 3 deals mainly with questions of malingering and simulated amblyopia, and describes fully the many different methods which have been elaborated for their examination and detection. A second chapter of this part is devoted to the allied conditions of hysterical affections and traumatic neuroses.

The last part of the book deals with the methods of examination of patients who have met with accidents—with the provisions of the French workmen's compensation act—by whom an expert opinion may be demanded and the methods of its expression—with medico-legal evidence, and such like questions. All of this is of much interest, but can only serve as a very general guide to surgeons in this country.

We entirely agree with Baudry's conclusion that no formula can be evolved which will enable us to calculate in all cases the amount of professional incapacity which a given diminution of physiological visual acuity involves; it must necessarily vary with every trade, is often modified by

personal qualities, and requires to be carefully estimated in every individual case.

Instances of injuries of all description are freely and judiciously inserted throughout the book—the question of their treatment is naturally only alluded to incidentally. Baudry's medico-legal reports are models of what such documents should be. In this country the expert appears to be given more latitude, owing to his duties being less explicitly defined, the assistance which he will derive from a study of Baudry's useful volume is therefore so much the greater.

J. Herbert Fisher.

---

Hirschberg (J.). **Contributions to the Prognosis of Malignant Tumours of the Choroid.** *(Beiträge zur Prognose der bösartigen Aderhautgeschwülste.) Berliner klinische Wochenschr.*, Nos. 4 and 5, 1904.

The author begins by a review of the statistics of previous writers. These, it is pointed out, show a steady improvement. Fuchs collected 235 cases up to 1882 with only 6 per cent. of permanent recoveries. Amongst these cases there were 13 per cent. of local recurrences, mostly in those cases that had been operated on in the third stage; 18 per cent. showed metastases, and in these the stage at which operation was undertaken seemed a matter of indifference.

Pawel in 89 cases gives 31 per cent. of recoveries. Lawford and Treacher Collins in 85 cases give 31 per cent. of recoveries.

Hirschberg in his own cases had in 13 patients from 1872 to 1882 25 per cent. of recoveries. He now carries his statistics to 1903. In all there were 68 cases. In 63 of these the choroid was affected, in two the iris, and in three the ciliary body. As regards the age incidence the cases show a steady increase from the third to the eighth decade. This result is obtained by comparing the number of sarcoma cases with the average number of individuals in each decade. Enucleation was performed in 66 cases: in two of these the orbit was also exenterated. No death occurred as a result of the operation. In one case local recurrence six years after the enucleation was operated on, and this was followed by death four days later as a result of pulmonary embolism. The author warns against any exploratory puncture, as in two

cases in which this was done local recurrence took place in spite of careful removal of the conjunctiva in the neighbourhood. In both of these, however, removal was successfully undertaken, one patient being alive and well 8 years later and the other two. Sixty per cent. of his operations were performed in the first stage, 20 per cent. in the second, and 10 per cent. in the third, none knowingly in the fourth. Two of the growths were unpigmented, but there is no evidence that the presence or absence of pigment has any bearing on the prognosis. Fourteen cases (22 per cent.) could not be traced. Of the 40 cases that had been observed for a sufficient length of time one died of recurrence, 17 of metastasis, and 22 were alive and well, giving 56 per cent. of recoveries. Deaths from metastasis usually occur within two and a half years of operation, but no definite rule as to this can be laid down. A striking case to illustrate this is reported. The patient had the eye removed for a melanotic growth early in the first stage, while the eye still possessed $^{6}/_{60}$ of vision, and only half the field was lost. Nine years later she died of metastases of the liver, pancreas and myocardium. In one of Hirschberg's cases two and three quarter years after the enucleation a lymphatic gland in the neck became affected and was successfully removed, and the patient was alive and well ten years later. The author comes to the conclusion that in spite of the occasional deaths from early metastasis even in cases operated on in the very earliest stages, surgeons are fully justified in urging early operation.

E. Erskine Henderson.

---

Lorenzo Bardelli (Florence). **Filamentous Keratitis.** *Annali di Ottalmologia.* Vol. xxxiii., pt. 1.

The author described a case, that came under his care, of this rare and interesting affection, which followed upon a burn with lime. Both cornea were burnt by the caustic agent, but only the left, the less damaged one, developed filamentous keratitis. This made its appearance five weeks after the accident. Four days previous to the first eruption of filaments a vesicular formation consisting of thin well-marked blebs appeared in the surface of the left cornea, which, however, resumed its normal aspect by the next day. This transitory vesicular formation has only been described by one previous writer—Hess—who

had two cases in which vesicles preceded the filamentous keratitis, which former development likewise disappeared altogether before the latter condition manifested itself. Bardelli therefore does not think that there is any very strict relationship between these two conditions, though they both point to alteration in the activity and nutrition of the corneal epithelium. From an etiological standpoint filamentous keratitis has been divided into a so-called idiopathic variety and a secondary form in which this formation results from some pre-existing corneal mischief, especially of an irritative nature. Leber, who first described this affection as a clinical entity, says that he has never met with a case of filamentous keratitis in which the cornea at one time or another had not been affected in some way. From a study of the published cases the author bears this statement out, and shows that the intensity of the reaction, the number of filaments, and the direction of this affection are all in strict relationship to the severity and nature of the pre-existing or exciting corneal lesion—of which a list is given.

After reviewing the literature of the subject (of which a full biography is given), the author comes to the following conclusions as regards the growth and structure of the filaments and to the causes that produce their torsion:—

(1) The filaments start from small round globules not unlike small vesicles in appearance, which within 12 to 48 hours, by the formation of a slender pedicle, become developed into filaments.

(2) The small filaments are cellular in their nature, but as they become more developed a central core is formed of epithelial cells which have undergone keratine degeneration, and this is surrounded by a more or less complete envelope of cells which have undergone mucoid degeneration.

(3) The torsion is not the result of unequal growth of the cells composing the filament, but a purely mechanical process resulting from the movements of the eye and eyelids rolling the filament constantly about. The tension that is thus produced is transmitted to the cells forming the base of the filament, which being thus stimulated proliferate and cause the further growth of the filament.

THOMSON HENDERSON.

---

D. DE BERARDINIS (Naples). **Hypopyon Ulcer Caused by Bacillus Coli.** *Annali di Ottalmologia.* Vol. xxxiii.

THE general and diffuse distribution of the bacterium coli, and the increasing importance it is gaining in consequence of the discovery of the important pathological rôle it is able to play in the human frame, lend great interest to Prof. Berardinis' case. The bacterium coli has been met with as the exciting factor in several eye affections. It has been found in the pus of certain cases of dacryocystitis, and described in some cases of ophthalmia neonatorum not caused by the gonococcus, but it has only been met with in one previously published case of corneal ulcer.

The author's case was one where a severe hypopyon ulcer followed an injury caused by the lash of a whip, in consequence of which the eye required enucleation eight days after the accident.

Bacteriological examination showed a bacillus whose form, growth in various culture media, and reaction to the specific agglutination test, proved it to be the bacillus coli. Histological examination showed marked swelling and œdema round the ulcer, with disentegration and breaking up of the corneal stroma, accompanied by infiltration, and fibrinous exudate filling the inter-lamellar spaces. The colon bacillus was most abundant in that part of the cornea least altered, and was especially numerous in the deeper and non-infiltrated part lying immediately in front of Descemet's membrane. This membrane was found unaltered and unbroken throughout its whole extent. The author therefore contends that the hypopyon in cases of septic ulcer of the cornea is not derived, as some authorities would have it, from a posterior abscess bursting into the anterior chamber, but is the result of inflammatory reaction of the iris and ciliary body—which structures show all the signs of inflammation.

A series of experiments was also carried out to determine the virulence, both local and general, of the micro-organism present. The resulting lesion in the rabbits' eye was in every way, clinically as well as histologically, analogous to the primary lesion in the patient's eye.

THOMSON HENDERSON.

## OPHTHALMOLOGICAL SOCIETY OF THE UNITED KINGDOM.

The President, Mr. JOHN TWEEDY, in the Chair.

*Case of Paresis of certain Third-nerve Muscles, with Over-action of others.*—Mr. N. Bishop Harman.

The patient, a lad aged 19 years, on being told to look at an object which is slowly depressed below the horizontal, follows it with his right eye, and the lids co-ordinate normally, the left eye, however, at first remains motionless, but as soon as the object has descended to a point 20° below the horizontal plane of the eyes, the left lid fails to follow and is gradually raised till it reaches its point of maximum elevation, with the whole of the cornea and a band of sclera 5mm. broad exposed. The right lid descending until it almost veils the globe. At the same time the left globe undergoes a movement of adduction. On being told to close his eyes both lids are closed completely, the right having only a small distance to descend, but the left the maximum distance; the power of the orbicularis muscles of both eyes is equal. The left nostril is blocked owing to a deflected septum, resulting from a fall on his nose when a child. The history of this perverted movement only dates back about a year, when one day he had great pain on the left side of his head and was sick. The day afterwards the left eye suddenly closed, and three weeks later complete paralysis of all the muscles of the left third nucleus was present - ptosis, external deviation of the globe, dilated and immobile pupil. Both fundi normal. The exhibitor pointed out that the case illustrated three interesting phenomena :—1. An illustration of abnormal overaction in a partially disabled nucleus. 2. The question of the innervation of the orbicularis palpebrarum muscle. 3. The co-ordinate movements of the lids and the globe. The sudden onset suggested an axial origin, the whole of the second group being affected, then partial recovery of the supply to the internal rectus, and the complete recovery of the supply to the Lev. Palp. Sup., whilst the other parts of the group remained disabled. The phenomena described were due to overaction of the healthy parts of the third nucleus on any impulse being received by it, the disabled parts being unable to respond.

*Peculiar condition of the Lacrymal Sac following injury.*—Mr. R. W. Doyne.

This patient, a boy aged 15 years, when first seen in February, showed a tender swelling in the position of the left lacrymal sac, from which, on firm pressure, liquid blood exuded through the puncta into the conjunctival sac. Later, the blood could only be squeezed through the upper punctum. At the present time pressure on the soft, elastic, tender swelling caused it to disappear like a hernia without any regurgita-

tion of fluid either into the conjunctival sac, or into the nose, and when emptied of its fluid contents there remained a depression in which the tip of the finger could be placed, giving the idea that the lacrymal bone had become absorbed. No changes could be found in the nose. The history of injury which occurred some five weeks ago was simply that when "larking," a girl flapped a haddock into the eye, grazing the root of the nose, but the swelling did not present till a week later.

*Sections of Mr. L. Paton's case of Tubercle of the Choroid.*—Mr. J. H. Parsons.

The case was reported in Vol. xxiii. of the *Transactions*, p. 63. A large white mass had been seen near the disc; this proved to be 4mm. in diameter and to consist of folded retina, showing all the layers including the layer of rods and cones, though in some places the latter were absent. This folded part of the retina lay on a bed of newly-formed fibrous tissue, part of which was hyaline, there was also evidence of considerable proliferation of the retinal epithelium in this inflammatory tissue. No traces of giant cells could be seen, but in some places deposits of granular tissue, probably calcareous, were very evident. The choroid under the mass was quite healthy, with here and there rents in the membrane of Bruch allowing minute hyaline masses surrounded by pigment epithelium to protrude, these masses resembling in every respect "colloid" bodies of the choroid. Passing over the folded retina and stretching across the disc a thin membrane could be seen, which in all probability represented the greyish veil noted clinically in the report of the case.

*A case of Myasthenia Gravis.*—Mr. J. B. Lawford.

The patient, a baker aged 51, showed a very general want of muscular power and extreme tiredness. When admitted to the R.L.O. Hospital the chief points noted were bilateral ptosis which became complete, and well nigh complete loss of the action of all the external ocular muscles, though the internal ocular muscles remained unaffected; great enfeeblement of the facial muscles with loss of the usual folds; distinct difficulty of deglutition with the occasional regurgitation of fluids; a nasal intonation when speaking; and weakness of the abdominal, dorsal, leg, and arm muscles, without any inco-ordination and with good muscular sense. All the reflexes were present, though the conjunctival reflex was very sluggish. The ptosis was so nearly complete that the patient always walked with his head thrown back in order to make use of the slight palpebral fissure remaining to him, but latterly he had been much relieved of this difficulty by wearing a pair of spectacles with a curved wire ridge projecting against the upper lids, and thus artificially raising them and overcoming the ptosis. He had always been

a hard-working healthy man up till 14 years ago, when he first noticed this drooping of the lids which increased greatly after an attack of influenza.

*A case of Myasthenia Gravis.*—Dr. James Taylor.

The patient, a painter by trade, aged 46, had suffered from lead colic and painter's gout, though no definite history of paralysis could be elicited. Some ten years ago he noticed he had ptosis which continued intermittently during the next six years; between the attacks he stated he was quite well. Nine years ago he found he had diplopia, and this and the ptosis have been permanently present during the last four years, so that he has not been able to read for long at a time. At the present time he has double ptosis, that of the right upper lid being greater than that of the left, and paralysis of ocular movements, but the pupils react to light. The arm and leg movements are easily exhausted, mastication difficult, articulation still good, all reflexes and sphincters normal. The myasthenic reaction is present in all the affected muscles, especially the flexors and extensors of the wrists and fingers.

*Retinal changes one week after Contusion of the Eyeball.*—Mr. Reginald E. Bickerton.

The patient, a man aged 19, was struck on the left eye by a football, without any wound of either globe or conjunctiva resulting. Immediately after the blow everything seemed to him blurred, and as this did not clear up he came to the Hospital for advice.

The eyelids and globe presented a normal appearance. The pupil reacted normally, though perhaps slightly more sluggishly than the other, the iris itself slightly tremulous, the lens quite clear, and in its normal position. With the ophthalmoscope, the vitreous appeared quite clear, the disc of a good colour, and with the exception of one spot the retinal vessels everywhere in the fundus were normal. Occupying the upper and outer quadrant of the fundus extending from the disc outwards, including the macula and a short space below it, there was a large patch dotted over with fine pigment and looking white in places. Dots of pigment adhered along the wall of the superior temporal vein, while the accompanying artery disappeared in places in the patch. Above, the patch emerged gradually into the normal fundus, upwards and outwards it extended to the periphery, while below it showed a sharp line of demarcation with an increased amount of pigment; just below this line the retina was œdematous with white vertical streaks on its surface, but no pigment. No rent in the retina could be made out, nor were there any white streaks indicative of rupture of the choroid. The retina appeared to be raised over the patch, but still more so just below it. No hæmorrhages were to be seen at any time. The vision of the right

eye was $^{6}/_{6}$ while that of the left was a bare $^{6}/_{60}$. A very similar case was shown before the Society by Mr. Hutchinson, junior, in 1889, and is recorded in the *Transactions*, Vol. ix., page 116. Another case is mentioned in the *Ophthalmic Hospital Reports* of 1876, under the pathological report of an eye injured by a blow and subsequently removed: patches of retinal pigment were found in the central region. Berlin in describing changes taking place in the retina as the result of blows upon the eyeball, makes no mention of pigment disturbance, only describing fleeting appearances of œdema at or round the macula.

*Hereditary Optic Atrophy in two brothers.*—Mr. Reginald E. Bickerton.

One of the brothers, a Marine (discharged) was aged 35, and stated that his sight had begun to fail when 27 years of age. He had attended a hospital and had been there advised to give up smoking. Taking the medicine ordered and stopping his tobacco absolutely for over six months did not bring about any improvement in his vision. At the present time his vision is just sufficient for him to get about; with the right eye Snellen's large letter can be read at 2ft. distance, with the left at about 2½ft., and with both, letters of Jg. 19. An examination of the fundus showed both discs very pale, and in the macular region of the right eye a dotted appearance, the vessels did not appear to be smaller than usual. Both fields of vision were much contracted, together with a central scotoma for white and all colours. Colours were not recognized with any certainty in any part of the field. The patient had been invalided from the Navy on account of defective vision, he was finally discharged from the Service. His brother and his mother's brother had also suffered from defective vision in much the same manner, the latter having been discharged from the Army while in India from the same cause. The second patient, brother to the last, a carman, aged 32, stated that his sight began to fail when 22 years of age; he noticed first that he was unable to read. He had always been a fairly heavy smoker, but on attending a hospital and being told to give it up he did so absolutely for considerably over six months. In spite of this he found his sight still failing, and it has continued to do so, till at the present time with each eye he can barely read $^{1}/_{60}$ and words of Jg. 19. Both fields of vision for white are much contracted, the field for blue being still smaller, no defined central scotoma can be made out for white or colours. Ophthalmoscopically, both discs are very pale, but the retinal vessels appear normal in size. The urine is normal, and there is no history of syphilis or any other illness except influenza.

*A method of Differential Staining for Retinal and other Nerve Ganglion Cells.*—Mr. Stephen Mayou.

The tissue must be fresh and fixed in alcohol or saturated perchloride

of mercury, embedded, and cut in the usual manner in paraffin. The stain is made up of methyl green, pyrosin, and distilled water; by this method the ganglion cells are picked out by the pyrosin, the granules and nucleoli being stained red, while the nuclei of the neuroglial cells and the nuclear layers of the retina are counter-stained blue.

*Two cases of Congenital Dislocation and Malformotion of the Lenses occurring in a brother and a sister.*—Mr. Leslie Paton.

*Varicose Aneurism (cerebral) with double Optic Neuritis.*—Mr. A. Q. Silcock.

The patient, a girl 1½ years old, had been attending a hospital for some months for "wasting." Two months ago the left eyebrow had been knocked against a chair and since this the left eyelids had always been puffy, and occasionally the eye became bloodshot. Later the left eye became slightly proptosed, with the appearance of a few tortuous veins in the conjunctiva. A month later the eye still being proptosed, slightly marked optic neuritis in both eyes was found, with more swelling in the right than in the left. Even under chloroform no mass could be felt. The retinal veins were congested and tortuous. A loud cerebral bruit could be heard pretty well all over the head.

*A case of Rupture of the Choroid.*—Mr. Charles Blair.

The patient, aged 16 years, had been struck in the right eye by a piece of wood while chopping. Half an hour after, on coming to the hospital, he was found to have an extensive abrasion of the corneal epithelium. Two days later the anterior chamber was found filled with blood, and on this disappearing in due course, the fundus was examined. The examination showed that at a distance of about one disc diameter from the disc, on the outer side, there was a white angular band produced by a laceration of the choroid, still further outwards was a long crescentic white band having its concavity towards the disc with two small irregular white patches still further out from it. The field showed a complete central scotoma.

PAPERS.

*The Retina and Optic Nerves in Anencephaly.*—Mr. Stephen Mayou.

The writer prefaced his paper by stating that the investigations he had carried out led him to the opinion that the axis cylinders of the optic nerve are derived purely from the cerebrum, and not from the brain and the retina as is usually considered to be the case. Out of some 38 recorded cases of anencephaly, beyond the occasional remark that "the optic nerves were found to be mere stumps" no thorough histological examination of the condition of the eyes and optic nerves seems to have undertaken. In recapitulating some points in the development of the retina and optic nerve and its sheath, attention was called to the

fact that, before the cells in the situation of the future optic nerve stalk disappear, and before there are any axis cylinders in the nerve, the mesoblast which surrounds both these cells and the cerebral vesicle becomes differentiated to form both the future nerve sheath and the cranial membranes respectively, and these are continuous one with the other. Thus it is seen that the optic nerve sheath is differentiated before there are any axis cylinders in the nerve at all. The condition described in this paper was that of a fœtus in which an arrest of development of the brain, in the stage when the primary and secondary optic vesicles are normally formed and the nerve sheath already differentiated, but before the formation of any axis cylinders or chiasma. The fœtus was born at full term, and with the exception of the head and nervous system was fully and normally developed. The globes externally appeared normal. Within the head there was no cerebral substance, the brain, medulla and upper part of the spinal cord being absent. The eyes were enucleated, and the optic nerves traced back to the optic foramina where they were lost in the dura mater, no trace of any intra-cranial portion of the nerves, chiasma, or tracts could be made out. Microscopical examination of the optic nerves showed entire absence of the axis cylinders, the outer sheath was thickened and the whole nerve was made up of fibrous trabeculæ surrounding the central artery and vein, which were of large size. At the entrance of the optic nerve into the globe there appeared a very deep and sharply defined cup, probably due to the absence of the nerve-fibre layer. The choroid consisted of large vascular channels. The retina showed the pigment layer, rods and cones, nuclear and granular layers normal, while the ganglion cell layer, though present, showed increase in the nuclei of the neuroglia cells, and fewer ganglion cells. The nerve-fibre layer was completely absent as shown by the vessels lying against the hyaloid membrane of the vitreous, uncovered by any layer of nerve fibres. In this fœtus, therefore, there was a fully developed globe and retina with the single exception of the missing nerve-fibre layer of the retina, the nerve sheath fully formed, but showing an entire absence of the axis cylinders, the reason of their want of development being the failure of development of the cerebral centres anencephaly.

*Trachomatous Pannus and its associated Corneal changes.*—Major H. Herbert.

This paper was based on the very frequent opportunities of observing the commencement of acutely progressive trachomatous pannus, afforded by practice in India. At the very outset there appears a marginal zone of vascular ingrowth all round the cornea, together with ciliary injection; these closely-set vessels passing inwards from enlarged conjunctival

vessels are all superficial to Bowman's membrane, and their terminations are enclosed by fine grey lines of opacity. This vascular zone being usually broader above, but not invariably so, does not stain, and the dull cloudy corneal surface stains but feebly with fluorescine. This ingrowth may be regarded as an advancement of the conjunctival limbus, and is not very uncommon in quite recent conjunctivitis; whether it persists and develops into recognised pannus, or clears up entirely, depends on the continuance or not of the causative conjunctivitis. Should the condition persist, the vascular area broadens, the central part becomes more steamy and opaque, and may eventually ulcerate. These forms of pannus, primarily superficial and of rapid onset, are superficial to Bowman's membrane and correspond to "pannus degenerativus" of blind injured eyes; they contrast strongly with the more common trachomatous cases which have been shown to develop primarily beneath Bowman's membrane.

Lymphoid pannus, these uncommon adenoid formations on or in the cornea, is practically confined to old cases of trachomatous pannus. In some cases of trachoma where there are confluent follicles in the lids and fornices, with little recognisable inflammation, defined semi-translucent nodular elevations, feebly vascular, and rounded in outline sometimes arise from the basis of an old diffuse corneal opacity. Their elevation is only slight and they are flattened by the pressure of the upper lid, the centre of the elevation lies within the corneal margin, but they occasionally overlap the sclera. The larger ones arise from coalescence of the smaller, and they are frequently bounded by an anastomotic loop of vessels on the cornea. These separate nodules sometimes coalesce into a continuous lymphoid thickening found on the upper part of an old pannus. Less distinct lymphatic formations are seen in the upper part of the cornea in cases of long-standing pannus, which are highly vascular, and thick and fleshy (—pannus crassus or carnosus). The permanent results of very mild chronic pannus are frequently seen in Bombay as a slight extension downwards of the normal upper-marginal opacity, representing overlapping of the sclera and conjunctiva, with here and there pitting of the margin of the opacity, and these pits or notches are less opaque than the surrounding cornea, are depressed below the surface, and in dark races are pigmented. Pannus ulceration, (usually marginal, and sometimes mistaken for Mooren's ulcer,) and also ulcers associated with pannus, show a remarkable tendency to leave clear depressions rather than to fill up and leave opacities.

*Optic Atrophy and Primary Amenorrhœa.*—Mr. W. C. Rockliffe.

This patient, a girl aged 18, suffered from gradually increasing defect

of vision; she had never menstruated, and had obstinate constipation, but never headaches, sickness, or paresis. She rapidly improved with glasses, aperients, and iron. Six years later the sight again became worse, and the ophthalmoscope showed deep blue cupping of the discs with mottling at the macula. There was also at this time a history of some kind of epileptic seizure. A thorough examination of the patient brought to light the fact that, although 27 years old she had never menstruated, had an infantile uterus with undeveloped sexual organs, anæmia, constipation and double optic atrophy.

*Optic Neuritis following Concussion of the Eyeball.*—Dr. W. C. Rockliff.

The patient, aged 45, while loading a cart, received a severe blow over the right eye, without however any perforating injury of the globe. The vision became very defective after the accident. When examined with the ophthamoscope, there was seen intense optic neuritis with effusion round the macula, in the centre of which was a hæmorrhage. There was no actual detachment, but the whole retina appeared swollen. Seven months after the injury all traces of optic neuritis had disappeared, but at the central region of the fundus was a large square-shaped patch of choroidal atrophy surrounded by dark pigment, and several dark pigmentary deposits at the macula.

*A peculiar outbreak of Granular Ophthalmia.*—Dr. W. C. Rockliff.

On March 4th the Night Superintendent of the Hospital (Hull) began with an attack of conjunctivitis; the next day there were also ciliary injection, photophobia, and œdema of the ciliary margin; two days later a nurse commenced the same symptoms; a day later a second nurse; two days later a third nurse, also the House Physician and second House Surgeon; two days later a fourth nurse, and 14 days later a student, seven in all, with the right eye affected first; all of these had been in contact with a child suffering from diphtheria who had had tracheotomy performed. In each case the lower lid became granular. The use of perchloride and mitigated stick cut short the attack.

*Trichiasis and the operation for Trichiasis.*—Mr. W. E. Cant.

REGINALD C. BICKERTON.

---

## Bibliography.


### Anatomy and Physiology.

Broca and Sulzer. Functions of retina in regard to time. *Annales d'Oeul*, Feb. to April.
Colombo. Reparative processes in the corneal epithelium. *Annali di Ottal.*, 5, 1904.
Diller. Eye (and other) reflexes in healthy persons. *Amer. Medicine*, April 23.
Gamble. Architecture of cerebral visual apparatus. *Annals of Oph.*, April.
Hilbert. Physiological colour sensations. *Klin. Monats. f. Augen.*, May.
Stuart. Function of hyaloid canal in accommodation for distance. *Jl. of Physiology*, 31, 1.

### Congenital Abnormalities.

Dalén. Bilateral congenital lachrymal fistula. *Mitteil. aus Augen.*, Stockholm, 5, 1904.

## Hygiene.

Allport. Annual examination of eyes of schoolchildren. *Annals of Oph.*, April.
Cohn. School hygiene. *Woch. fur Ther. und Hyg. des Auges.* vii., 30.
Oliver. Inadequacy of colour signals. *Annals of Oph.*, April.
Probsting. Artificial lighting of Schools. *Woch. f. Ther. u. Hyg. des Auges.*, vii., 33.
Uribe-Troncoso. Hygiene of eyes in Mexican Schools. *Ophth. Record*, March.

## Pathology and Bacteriology.

De Berardinis. Ulcer of cornea from streptothrix. *Annali di Ottal.*, 5, 1904.
Harms. Senile affections of macula. *Klin. Monats. f. Augen.*, May.
Puccioni. Bacteriology of pseudo-membranous conjunctivitis. *Bollett. dell'Osped. Oftal.*, May.
Pusey. Experimental production of Cataract. *Archiv. of Ophthal.*, March.
Woods and Johnston. Panophthalmitis after extraction. from pneumococcus infection, *Ophth. Record*, April.
Yamaguchi. Pathological Anatomy of eyes after staphyloma of cornea. *Klin. Monats. f. Augen.*, April.

## Instruments and Apparatus.

Dunn. Colour testing appliance. *Brit. Med. Jl.*, April 16.
Schiele. Alcohol bandage in panophthalmitis. *Woch. f. Ther. u. Hyg. des Auges.*, vii., 33.
Stevenson. Eye speculum. *Ophth. Record*, April.
Stretton. Entropium forceps. *Brit. Med. Jl.*, April 16.

## Therapeutics.

Domec. Massage in myopia. *La Clin. Opht.*, April 25.
Goldzieher. Roentgen rays in treatment of trachoma. *Wiener Med. Woch.*, 19.
Hinshelwood. Dionine. *Brit. Med. Jl.*, April 30.
Manolesco. Heat in cases of ulceration of cornea. *Annals d'Oc.*, March.
Ramoni. Suprarenal extract. *Bull. dell'Osped. Oftal.*, April and May.
Reumaux. Ichthyol and thigenol in blepharitis. *La Clin. Opht.*, May 10.
Sommer. Nizo-lysol. *Woch. fur Ther. u. Hyg. des Auges.*, vii., 33.

## Operations.

De Britto. Haemorrhages after operations. *Arch. d'Ophtal.*, March.
Brown. History of operation for cataract. *Annals of Oph.*, April.
Daléo. Transfixion of iris. *Mitteil. aus. Augen.*, Stockholm, 5, 1904.
Ekehorn. Method of operation for entropion. *Mitteil. aus Augen.*, Stockholm, 5, 1904.
Frohlich. Trephining of sclera in glaucoma. *Klin. Monats. f. Augen.*, May.
Landolt. Operation in affections of measles. *Annales d'Oc.*, May.
Klein. Advancement of muscles. *Wien. Med. Woch.*, 18.
Lindahl. A case of unusually good vision after extraction. *Mitteil. aus Augen.*, Stockholm, 5, 1904.
Manolesco. Operation for secondary cataract. *Annales d'Ocul.*, 1904.
Parinaud. Operation for ptosis. *Ann. d'Ocul.*, March.

## Traumatisms.

Goldzieher. Head injuries and blindness. *Centlblt. f. Augen.*, May.
Lange. Traumatic bi-temporal hemianopsia *Klin. Monat. Augen.*, May.
Santucci. Traumatic prolapse of lachrymal gland. *Centlblt. f. Aug.u.*, May.

## Tumors.

Barrett and Orr. Sarcoma of ciliary body. *Arch. of Ophthal.*, March.
Gonin. Angiofibroma of external rectus. *Arch. of Ophthal.*, March.
Hirschberg. Cancer of the retina. *Centr. f. prakt. Augen.*, April
Kauffmann. Carcinoma of limbus corneae. *Die Ophthal. Klinik.*, May 5.
Key. Eocanthis maligna. *Mitteil. aus Augen.*, Stockholm, 5, 1904.
Key. Sarcoma of choroid. *Mitteil. aus Augen.*, 5, 1904.
Parsons. Diffuse sarcoma of uveal tract. *Archiv. of Ophthal.*, March.
Pascheff. Tumours of the eye. *La Clin. Opht.*, May 10.
Pusey. Unusual sarcoma of choroid. *Arch. of Ophthal.*, March.
Scott. Fibro-myoma of conjunctiva. *Lancet*, April 30.

## Sympathetic Ophthalmia.

## Glaucoma.

Abadie. Forms of glaucoma. *Annales d'Ocul.*, April.
Daléo. Microphthalmos and glaucoma. *Mitteil. aus Augen.*, Stockholm. 5, 1961.
Demaria. Detachment of choroid in glaucoma. *Klin. Monats. f. Augen.*, April.
Frohlich. Trephining of sclera in glaucoma. *Klin. Monats. f. Augen.*, May.
Pooley. Glaucoma following subluxation of Lens. *Amer. Jl. of Ophth.*, March.
Pusey. Glaucoma and Osmotic disturbances. *Arch. f. Ophthal.*, March.
Sala. Rarer forms of glaucoma. *Klin. Monats. f. Augen.*, April.
True. Juvenile glaucoma. *Amer. Jl. of Ophthal.*, March.

## Amblyopia and Visual Defects.

Bocci. Bilateral hysterical amaurosis. *Annali di Ottal.*, April.
Nagel. Anomalous trichromatic system. *Klin. Monats. f. Augen.*, April.
Schiele. Night blindness and sclerosis. *Woch. fur Ther. und Hyg. des Auges*, vii., 32.
Wolffberg. Unilateral transitory amaurosis. *Woch. f. Ther. u. Hyg. des Auges*, vii., 27

## Refraction and Optical Questions

Hess. The act of accommodation. *Klin. Monat. f. Augen.*, April
Jones. Prisms in performance of shadow test. *Ophthal. Record*, April.
Parinaud. Stereoscopy and visual projection. *Annales d'Ocul.*, April.
Pohlman. Astigmatic changes. *American Medicine*, March 19.
Sattler. Basis of the treatment of myopia. *Deutsch. Med. Woch.*, 17, 18.
Swift. Eye defects in students. *Ophthal. Record*, March.
Tscherning. Mechanism of accommodation. *Annales d'Ocul.*, March.

## Regional Affections.

### Eyelids.

De Britto. Removal of chalazion. *Archiv. d'Ophtal.*, March.
Harlan. Associated movements of eyelid and jaw. *Ophthalmoscope*, May.
Parinaud. Operation for ptosis. *Annales d'Ocul.*' March.
Reumaux. Ichthyol and thigenol in blepharitis. *La Clin. Ophtal.*, May 10.
Snydacker. Œdema of eyelid due to syphilis. *Arch. of Ophthal.*, March.
Wolffberg. Blepharospasm from nasal disease. *Woch. f. Ther. und Hyg. des Auge*, vii., 31.
Zeller. Cysts of eyelids. *Klin. Monats. f. Augen.*, May.

## Lachrymal Apparatus.

Dalen. Bilateral, congenital, lachrymal fistula. *Mitteil. aus Augen.*, Stockholm, 5, 1904.
Quackenboss. Ligation of lachrymal canal to prevent infection of extraction wound. *Boston Med. and Surg. Jl.*, March 31.
Santucci. Traumatic prolapse of lachrymal gland. *Centblttt. f. Augen.*, May.
Wiener. Treatment of dacryo-cystitis. *N. Y. Med. Record*, April 2.

## Conjunctiva.

Alger. Epidemic of so-called trachoma. *N. Y. Med. Jl.* April 9.
Capolongo. Cysts of the fornix of conjunctiva. *Annali di Ottal.*, 5, 1904.
Goldzieher. Roentgen rays in treatment of trachoma. *Wiener Med. Woch.*, 19.
Johnston. Vernal catarrh. *Ophth. Record*, April.
Kauffmann. Blue coloration of conjunctiva. *La Clin. Ophtal.*, April 25.
Landstrom. Naevus of conjunctiva. *Mitteil. aus Augen.*, Stockholm, 5, 1904
Marlow. Chancre of conjunctiva, followed by interstitial keratitis. *Ophthal. Record*, March.
Oatman. Epithelial cystoma of conjunctiva. *Arch. of Ophthal.*, March.
Oliver. Gonococcal conjunctivitis. *Therapeutic Review*, January.
Puccioni. Bacteriology of pseudo-membranous conjunctivitis. *Bollett. dell'Osped. oftal.*, May.
Rollett. Chancre of conjunctiva. *Rec. d'Ophtal.*, March.
Scott. Fibromyoma of conjunctiva. *Lancet*, April 30.
Veasey. Spring conjunctivitis. *Amer. Jl. Med. Sci.*, May.

## Cornea and Sclerotic.

Bartels. Neuralgia of V. nerve and recurrent erosion of cornea. *Munch. Med. Woch.*, 17.
De Berardinis. Ulcer of cornea from streptothrix. *Annali di Ottal.*, 5, 1904.
Bock. Foreign body (aniline) in cornea. *Cent. fur Augen.*, April.
De Britto. Epithelioma of cornea. *Archiv. d'Ophtal.*, March.
Clifford. Ulcers of cornea. *Ophthal. Record*, March.
Dodd. Interstitial keratitis in relation to injury. *Ophthal.*, May.
Foster. Infiltration-œdema under Bowman's membrane. *Klin. Monats. f. Augen.*, April.
Hansell. Bullous keratitis. *Ophthal. Record*, March.
Kauffmann. Carcinoma of limbus cornea. *Die Ophthal. Klinik.*, May 5.
Lewis. Keratoconus. *Annals of Oph.*, April.
Lindahl. Hydrophthalmos, with detachment of retina. *Mitteil. aus Augen.*, Stockholm, 5, 1904.
Manolesco. The action of hot water in ulceration of cornea. *Annal. d'Ocul.*, March.
Marlow. Interstitial keratitis following chancre of conjunctiva. *Ophthal. Record*, March.
Schiele. Lead deposit on cornea. *Woch. f. Ther. u. Hyg. des Auges.*, vii., 34.
Vellagen. Primary bandshaped keratitis. *Klin. Monats. f. Augen.*, May.
Yamaguchi. Pathological anatomy of eyes after staphyloma of cornea. *Klin. Monats. f. Augen.*, April.
zur Nedden. Croupous and Diphtheritic corneal affections. *Klin. Monats. f. Augen.*, May.

## Iris and Ciliary Body.

Abadie. Tubercular iritis. *Arch. d'Ophtal.*, March.
Barrett and Orr. Sarcoma of ciliary body. *Archiv. of Ophthal.*, March.

Hirschberg. Slow disappearance of pupillary membrane. *Cent. f. prakt. Augen.*, April.
Parsons. Diffuse Sarcoma of uveal tract. *Arch. f. Ophthal.*, March.
Pooley. Cyst of iris. *Amer. Jl. of Ophthal.*, March.
Romheld. Unilateral immobile pupil. *Medicin. Corresp. Blatt.*, Wurtemberg, April 2.
Shute. Pupil in "pink eye." *Jl. of Eye, Ear, and Throat Diseases*, March.
Wescott. Corectopia and ectopia lentis. *Ophthal. Record*, March.
Wiecherkiewicz. Iridodialysis: can it resolve? *Klin. Monats. f. Augen.*, April.

## Lens.

Calhoun. Cataract and hook-worm disease. *Ophthal. Record*, April.
Dransart. Cataract in Northern France. *L'Echo Medical*, March 13.
Millikin. Hereditemy element in cataract. *Amer. Jl. of Ophth.*, March.
Pooley. Subluxation of lens and glaucoma. *Amer. Jl. of Ophth.*, March.

## Choroid and Vitreous.

De Britto. Recurrent intraocular hemorrhage. *Arch. d'Ophtal.*, March.
Cirinicione. Origin of Vitreous. *Annali di Ottal.*, April.
Demaria. Detachment of choroid in glaucoma. *Klin. Monats. f. Augen.* April.
Dupuy-Dutemps. Glaucomatous forms of tubercle of choroid. *Arch. d'Oph.*, May.
Goldzieher. Prognosis in tumour of choroid. *Centbltt. f. Augen.*, May.
Key. Sarcoma of Choroid. *Mitteil. aus Augen.*, Stockholm, 5, 1904.
Pusey. Unusual sarcoma of choroid. *Archive of Ophthal.*, March.

## Retina.

Asmus. Pressure bandage in detachment of retina. *Munch. Med. Woch.*, 16.
Bossalino. Retinitis circinata. *La Clin. Ocul.*, March.
Cohen. Retinitis proliferans. *Jl. of Eye, Ear, and Throat Dis.*, March.
Brucker. Disease of macula following removal of a splinter of iron from retina. *Die Ophthal. Klinik.*, May 5.
Evans. Neuroretinitis in chlorosis. *Lancet*, May 14.
Opin and Rochon-Duvigneaud. The lesions in Albuminuric retinitis. *Arch. d'Ophtal.*, March.

## Optic Nerve.

Cirincione Concretions in the papilla. *La Klin. Ocul.*, March.
Snyder. Optic atrophy from iodoform. *Ophthal. Record*, March.

## Muscles (and Strabismus).

Batten. Ophthalmoplegia externa with blindness in a child. *Ophthalmoscope*, May.
Beykovsky. Paralysis of III. nerve in aneurysm of carotid. *Wiener Med. Woch.*, 19.
Landolt. Operations in affections of muscles. *Annales d'Ocul.*, May.

## Orbit and Globe.

De Britto. Orbital meningocele. *Arch. d'Ophtal.*, March.
Hansell. Localisation of foreign body in orbit, and its removal. *Amer. Medicine*, April 30.
Moulton. Small-shot injuries to globe. *Ophthal. Record*, March.
Oliver. Pulsating exophthalmos: ligature. *N. Y. Med. Jl.*, April 9.
Roux. Traumatic enophthalmos. *Arch. d'Opht.*, March.
Schiele. Alcohol bandage in panophthalmitis. *Woch. f. Ther. u. Hyg. des Auges.*, viii., 33.
Van Duyse. Pulsating exophthalmos caused by tumour of ethmoid. *Archiv. d'Oph.*, May.

## Relations with Medicine.

Allport. Relationship between Ophthalmology and Dentistry. *Medical News (N. Y.)*, April 16.
Clarke and Hawthorne. Optic neuritis and paralysis in chlorosis. *Lancet*, April 30.
Dufour. Sensorial origin of conjugate deviation of head and eyes with hemianopsia. *Revue Neurologique*, 7, 1904.
Gould. Torticollis and spinal curvature from eye-strain. *American Medicine*, March 26.
Kalish. External diseases of the eye due to Rheumatism. *Medical News (N. Y.)*, April 23
Kilburn. Eye-strain and cause of lateral curvature. *Boston Med. and Surg. Jl.*, March 24.
Liersch. Aggravomania. *Woch. f. Ther. u. Hyg. des Auges.*, vii., 27.
McKennan. Cyst of right occipital lobe. *Jl. Mental and Nervous Diseases*, May.
Opin and Rochon-Duvigneaud. The lesions in retinitis of albuminuria. *Arch. d'Ophtal.*, March.
Trousseau. Headaches of ocular origin. *La Presse Médicale*, April 23.
Tschirjew. Complete recovery from hemianopsia. *Arch. f. Psychiatrie*, 38, 2.
Vail. Eye (and other) complications of acute infectious diseases. *Pediatrics*, March.

## Miscellaneous.

Harman. Aliens, dirt and disease. *Lancet*, May 14.
Millikin. Accident to a glass eye. *Ophthal. Record*, April.
Schmeichler. Simulation of eye diseases. *Wiener. Med. Woch.*, 16, *et seq.*
Notes from Continental Eye Cliniques. *Indian Med. Gazette*, April.

# OPTIC NEURITIS FOLLOWING SMALLPOX.

By A. Freeland Fergus, M.D., Glasgow.

John Conlan, seen 8th January, 1904, a middle-aged man, who was employed as a foreman dock labourer, was recently attacked by smallpox, and was admitted to Belvidere Fever Hospital. He says that the dimness of which he complains was first observed by him on dismissal from the "red room;" he found that it affected his right eye but not his left.

On examination it is ascertained that the visual acuteness of the right eye measured by Snellen's scale is $^{6}/_{12}$ of the standard, a condition of matters which is not improved by glasses; in the left it is $^{6}/_{6}$. Both pupils react well to light and to convergence.

Ophthalmoscopic examination shows the media of the right eye to be perfectly transparent and healthy. The optic disc, however, is distinctly blurred, especially to its outer side. There is a distinct hyperæmia and loss of transparency in the optic papilla, but there is no swelling of the disc; hæmorrhages are not present, and there is little tortuosity of the vessels. The blurring, however, is quite distinct all over the disc, but chiefly at its outer aspect. The fundus of the left eye is, on the contrary, quite normal; the margins of the disc are distinctly differentiated all round; there is no haziness, and in all respects it is normal.

On testing with Bjerrum's light sense types, it was found that when No. III. (the faintest) was used he could see with the left the fourth row of the letters, but with the right only the first row. As the result obtained with the left eye was equivalent to that obtained either for myself

or for my assistants at the same time and under the same illumination, it may be taken as up to the standard. There was thus a marked difference in the two eyes. The fields of vision when tested for white light were both found to be much contracted. At no point did either field extend to a greater angular distance than 30° from the point of fixation. The right was slightly more contracted than the left.

In view of Antonelli's interesting report on optic neuritis following acute infections, the question occurs, Is the optic neuritis in this case due to the attack of smallpox, or must it be attributed to other causes? Strict inquiry was made as to his having been at any time the subject of syphilitic infection, with entirely negative results, nor was there any evidence of his being the subject of any other form of peripheral neuritis.

Knies (English edition) says that in hæmorrhagic smallpox, of which this was not a case, hæmorrhages sometimes occur into the optic nerves, and that to them must be attributed some optic nerve affections with or without stasis and with or without secondary atrophy. Adler described two cases of diffuse neuro-retinitis as the pustules passed off. His cases are quoted by Knies, but unfortunately we have not been able to peruse a copy of his original communication.

---

## REVIEWS.

TH. LEBER (Heidelberg). **The Circulation and Nutrition of the Eyeball.** *Graefe-Saemisch Handbuch der Gesamten Augenheilkunde.* Theil i., Band ii., Kapitel xi.

THIS contribution from the pen of one who has made a lifelong study of the subject, and who by his own work has done so much to extend our knowledge, could not fail to be of interest. Prof. Leber has certainly produced a work worthy of his great

reputation. The monograph extends to 500 pages, and no less than 1,328 literary references are given, carefully grouped according to their subject matter and chronologically arranged. Leber's own work is never brought into undue prominence, and judicial criticism of theories and opinions is a feature of the work.

Dealing first with anatomy, Leber gives a detailed and well illustrated description of the ocular blood-vessels. Comparative anatomy receives much more attention than can be given to it in an ordinary text-book. Lindsay Johnson's work on the retinal blood-vessels in mammals naturally receives special attention. Differences in the vascular arrangements in men and animals, such as might modify the results of experiment, are pointed out. The lymph paths and serous spaces of the eyeball, conjunctiva and optic nerve are briefly described. The existence of an anastomosing system of spaces in the cornea for the circulation of lymph is denied by Leber, who considers that the corneal tissues are nourished solely by diffusion. The second and more important part of the monograph deals with the subject from a physiological standpoint. Stress is laid on the great differences as regards nutritive needs between those parts of the eye the function of which is purely mechanical or optical, and parts functionally so active as the retina or ciliary muscle. The eye is planned so as to get rid of blood-vessels in the optical apparatus and at the same time provide an adequate, if small, supply of nourishment for those tissues in which no vessels exist. In judging of problems of interchange of fluids, Prof. Leber specially warns us that diffusion streams must on no account be confused with actual streams or currents of fluid.

The direct influence of nerves on the circulatory and nutritive changes in the eye is discussed and considered to be small. Thus Leber, as will be seen later, is inclined to ascribe the occurrence of neuro-paralytic keratitis mainly to external agencies—injury, desiccation, etc.

Some interesting facts regarding the temperature of different parts of the eye are given. The corneal temperature is stated to be about 29°C., and that of the conjunctival sac as 35°C. In the deeper parts of the eye the temperature approaches more nearly to that of other tissues.

A short account is given of the regeneration of the eye which has been observed to take place in certain young amphibians

after a large part of the organ has been removed. The formation of a new lens from a localised proliferation of the iris epithelium, as observed by Colucci, is specially noteworthy.

In speaking of the anastomoses between the choroidal and retinal circulations, Leber expresses the opinion that these connections, though numerous, are formed by vessels of almost capillary calibre, and that the central artery of the retina must be looked upon strictly as an end artery. In acute obstruction of this vessel the anastomoses round the lamina cribrosa are quite inadequate to maintain the retinal circulation.

The phenomena of pulsation observed in the retinal vessels under various conditions are fully discussed. Leber differentiates between a true arterial pulse seen in aortic insufficiency, Basedow's disease, etc., and pulsation induced by a difference of pressure in the artery and the resistance encountered by the blood-stream. The arterial pulsation seen in glaucoma or induced by pressure on the eyeball is an example of this form of pressure pulse "Druckpuls."

Obstruction to the retinal circulation from such a cause as embolism is fully discussed. The absence of the signs of a hæmorrhagic infarct as seen in other organs is thought to be due to the intra-ocular tension preventing the backward flow of venous blood into the eyeball. It is only the inner, and perhaps to some extent the central, retinal layers that have their nutritive supply cut off by stoppage of the retinal circulation, and thus the swelling and opacity of the retina are greatest near the disc where the nerve fibre and ganglion cell layers are thickest. At the fovea, where these layers are undeveloped, the retina remains transparent, and this area may therefore appear as a red spot. Experimental results in stoppage of the retinal circulation may be misleading owing to the different arrangement of the vessels in animals. In division of the optic nerve the ciliary arteries are apt to be cut along with the nerve, thereby introducing a fresh complication.

The ascending and descending nerve degenerations which follow section of the optic nerve are carefully described. As regards the former, it is interesting to note that in the retina the atrophic changes remain limited to the nerve fibre and ganglion cell layers. After destruction of the visual centre in the occipital lobe, Leber believes that in the course of years a descending atrophy becomes visible at the disc as a partial

optic nerve atrophy. He quotes a case of Schmidt-Rimpler, in which hemianopsia followed a severe injury to the occipital lobe, and where after five years a partial optic nerve atrophy could be demonstrated. In ascending degeneration the changes in the nerve itself after section take place rapidly, and in course of time, according to Leber, extend right up to the visual centres of the cortex.

The circulation in the uveal tract is next considered. The large number of arteries involved is supposed to favour uniformity of blood supply and lessen the risk of obstruction. Leber does not think that hyperæmia of the iris has much to do with the contraction of the pupil which usually attends evacuation of the aqueous since the same thing happens in the eye after death. Heine has shown that changes in intra-ocular tension do not primarily affect the size of the pupil. A very full and interesting account of the composition of the aqueous and vitreous humours is given. The vitreous is described as a sort of dropsical connective tissue, the fibrils forming a fine meshwork in which lies a fluid practically identical in composition with the aqueous.

The questions relating to the secretion and elimination of the aqueous next come up for discussion. Leber's views on these questions are now taught as established facts by most ophthalmologists. His account of the subject in the present monograph will be found very complete, clearly arranged, instructive and suggestive. A further question raised by the work of Wessely, Römer and others is likely to prove of the greatest importance, viz., Under what conditions do the protective bodies (alexines) of the blood serum appear in the aqueous? Wessely thinks the therapeutical effect of sub-conjunctival injections may be due to their irritant action bringing these bodies into the aqueous. Leber does not think that nerve stimulation can influence the aqueous secretion except indirectly through the blood supply. The question of whether the aqueous secretion of one eye can be in any way modified by injuring or irritating the other has been variously answered. Wessely, however, maintains that no sort of injury or irritation of one eye appreciably modifies the character or amount of the aqueous secretion in the other eye. Leber seems to hold this opinion also, basing his views on experiment.

Leber's view regarding the elimination of fluid from the anterior chamber by the filtration angle are too well known to

require comment. He appears to acquiesce in the view of Nuel and Benoit, that in man the iris aids in the absorption or elimination of fluid. The flow of fluid from the eye by way of Stilling's canal and the optic nerve is judged to be very slight, though present to a small degree.

Intra-ocular tension is next fully discussed. The work of Koster and others on the elasticity of the ocular tunics and on the slight alterations in the shape of the eyeball, and especially of the cornea, accompanying increase of tension is noticed. In the case of the cornea, increase of intra-ocular tension has a tendency to alter the curvature so as to produce astigmatism against the rule. The relation of blood pressure to intra-ocular tension is treated of in detail, and the use of manometers and tonometers for determining intra-ocular tension is described. The intra-ocular tension of the healthy human eye is given as 25mm., or one inch of mercury. The pressures in the anterior chamber and in the vitreous are considered to be identical. Hess and Heine are considered to have proved beyond doubt that contraction of the ciliary muscle does not influence the intra-ocular tension. Contraction of the exterual ocular muscles raises the tension very markedly for the time being. An interesting account is given of changes in the intra-ocular tension due to artificially induced changes in the blood pressure, arterial or venous. A large amount of experimental evidence is cited, all going to show how intimate is the relationship between blood pressure and intra-ocular tension. Thus large losses of blood, by lowering the arterial blood pressure, greatly diminish the intra-ocular tension, while, on the other hand, large injections of salt solution into the blood-vessels increase it. Owing to the very free anastomoses the intra-ocular tensions is not affected by obstructing the venous circulation unless the veins are tied quite close to the eyeball.

In discussing the conflicting evidence regarding the influence of the sympathetic on the intra-ocular tension, Leber does not seem to think that permanent reduction of tension is likely to be often achieved by excision of the superior cervical ganglion. The diminution of pressure which in man follows excision of the ganglion appears to be transitory, and usually disappears before the hyperæmia, which is often very persistent. Leber therefore does not seem to hope for much from Jonnesco's operation in the treatment of glaucoma.

The various questions connected with the permeability of the

cornea for fluids and the protective influence of the corneal endothelium next come up for discussion. Leber considers that the amount of nutritive material required by the cornea must be very small, as it has only a passive function. The idea of a constant stream of lymph moving through a system of anastomosing spaces (Recklinghausen's canals) in the corneal substance is held to be quite erroneous. The appearance of anastomosing spaces obtained by impregnation processes of staining does not, in Leber's opinion, justify the idea that a current of lymph circulates during life through these spaces; the cell protoplasm is thought by him to fill these "spaces" entirely.

In seeking an explanation for the loss of corneal transparency associated with increased tension, Leber accepts as correct the view of v. Fleischl that the opacity is due to the fibres becoming doubly refractive. The fact that the opacity clears up the moment the tension is reduced is in conformity with this explanation.

The vexed question of neuro-paralytic keratitis is fully discussed. Leber does not believe that the fifth nerve has a direct trophic influence on the cornea. He holds that the loss of sensibility and the diminished moistening of the cornea are the essential factors in producing the condition. The observations of Krause on the effect in the eye of destruction of the Gasserian ganglion in man appear to support this view.

The nutrition of the lens is a subject about which our knowledge is still very imperfect in spite of its clinical importance. Priestley Smith's estimate of the rate of growth of the lens all through life is taken as at any rate approximately correct. The lens substance, completely enveloped in a non-porous capsule, can only obtain nourishment from the fluids surrounding it by a process of endosmosis. The interchange does not, however, follow the ordinary rules of diffusion, for the lens during life does not tend to become identical in composition with the fluids surrounding it. The capsule, and more especially the sub-capsular epithelium, probably play an all-important part in regulating the diffusion processes to suit the needs of the organ. The interesting subject of cataract due to diabetes is treated of in detail, and much experimental work is cited. In the frog the absorption of a large quantity of concentrated salt or sugar solution injected under the skin will

produce cataract by so modifying the intra-ocular fluids that water is drawn rapidly from the lens. In diabetes, however, as clinically observed, the percentage of sugar in the aqueous is always very small, 0·5 per cent. being the highest concentration ever noted. A concentration of about 5 per cent. seems to be required to bring about cataract, so the explanation of diabetic cataract has not yet been achieved. With regard to the influence of heat and glare in producing opacities in the lens, it is interesting to note that experimental evidence seems to show that the lens is very resistant indeed to these agencies.

The questions relating to the absorption of diffusible substances from the conjunctiva and sub-conjunctival tissues are of importance in regard to the possible value of certain therapeutic measures. While it can be shown that certain very diffusible salts, *e.g.*, KI, $K_4FeCy_6$, when injected into the sub-conjunctival tissues in fairly strong solution pass readily into the anterior chamber, it has been found impossible to detect any traces of mercurial salts in the aqueous after sub-conjunctival injections of soluble mercurial salts in the concentration in which they are used therapeutically. A direct antiseptic working of these injections is therefore out of the question.

The last part of the monograph is devoted to a study of the orbital circulation and its relation to the intra-cranial circulation. The importance of the very free anastomoses, both arterial and venous, is pointed out, greatly lessening as it does the risks of sudden interference with the vascular supply of the eyeball. The flow of cerebro-spinal fluid into the optic nerve sheath is described. The dilatation of the optic nerve sheath often seen in cases of increased intra-cranial tension must be due to the pressure of lymph forced down the sheath from the sub-arachnoid space. Many experiments have been done to determine whether artificially induced increase of intra-cranial tension would produce permanent changes at the disc, but so far the evidence appears somewhat conflicting. It seems to us very questionable whether any procedure, such as repeated injections of agar or the introduction of tampons into the cranial cavity, really produce conditions comparable to those caused by an intra-cranial tumour. With regard to the possible spread of organisms from one eye to the other by way of the optic nerve sheath, it has to be borne in mind that the flow of cerebro-spinal fluid is towards the eye. The

organisms must therefore pass up the nerve sheath from the first eye against the lymph stream.

Throughout the monograph Leber purposely avoids theorising on such subjects as glaucoma, optic neuritis, sympathetic ophthalmia, etc. He puts before his readers the present state of our knowledge over the wide field covered by his subject, shows how this knowledge has been gained, and points out how much yet remains quite unknown or only vaguely guessed at.

J. V. Paterson.

---

George Dean and C. H. Usher. **Experimental Research on the Course of the Optic Nerve Fibres.** *Brain.* Vol. xxvi. No. 104.

The writers give a very interesting and valuable account of a series of experiments performed on monkeys, with a view to the determination of the position and course of nerve fibres in the optic nerve and in the chiasma. Degeneration was produced either by division of the optic nerve or by a lesion of the retina. The method of procedure was the same in these experiments as in a former series published in the *Transactions of the Ophthalmological Society*, Vol. xvi. In the former series rabbits were used, with one exception. In the present series monkeys were used throughout. For the methods of hardening, staining, etc., readers are referred to the former paper.

The cases dealt with in the present communication are divided into three groups according to the site of the lesion produced:—

1. Division of the optic nerve.
2. Retinal lesions at a distance from the macula.
3. Retinal lesions at the macula.

In Group 1 the optic nerve was divided in the orbit, with as little injury to blood-vessels as possible. Five monkeys were used, all Macacus Rhesus. The object in view in the performance of the experiments was chiefly to determine the difference in character and extent of degeneration in the parts of the nerve above and below the point of section. In three of the cases the degeneration, as indicated by osmic acid, was most marked above the scar. The changes found peripheral to it were regarded as largely due to interference with the vascular supply.

Results obtained in the chiasma:—

(1) The degenerated fibres begin to cross over as soon as they enter the chiasma.

(2) The crossing is first seen to take place at the ventral periphery, when the first junction of the nerves takes place. As the degenerated fibres are followed backwards they are found to occupy more and more of the chiasma from the ventral to the dorsal surface, till ultimately they are distributed over the whole central part.

(3) Only a few, if any, of the crossed fibres appear to approach the lateral periphery of the half of the chiasma corresponding to the unoperated nerve, whereas on the corresponding area of the opposite side the degeneration is dense.

(4) It could not be determined that the crossed fibres at the posterior part of the chiasma were more numerous than the uncrossed.

(5) A very definite tract of crossed fibres lies at the ventral part of the chiasma posteriorly.

In Group 2 are four cases of lesion at a distance from the macula, three in Macacus Rhesus and one (Case 9) in the Bonnet Monkey. In all these the degeneration occupies a position in the sectional area of the nerve corresponding to the site of lesion in the retina.

Results in the chiasma:—

(1) A ventral degeneration in the nerve maintains its ventral position in the chiasma. A very few degenerated fibres cross to the other side.

(2) A lesion at the inner part of the fundus is followed by a degeneration of the inner part of the nerve which in the front part of the chiasma lies on the same side, but ultimately crosses completely to the opposite side.

(3) A very peripheral lesion in the outer part of the fundus is followed by a degeneration in the outer dorsal part of the nerve. In the chiasma the degeneration lies on the same side close to the lateral periphery, ultimately crossing and occupying the ventral periphery of the opposite side. Only a few fibres remain uncrossed at the posterior part of the chiasma. The course of the degeneration throughout the chiasma in this instance was attributed to the fact that a specimen of the Bonnet Monkey was employed, and it was thought probable

that the more primitive type may have obtained in this instance.

It is, however, noted that another observer—Parsons—has found degenerated crossed fibres in the chiasma following upon a temporal lesion of the retina both in the Bonnet Monkey and in Macacus Rhesus.

In Group 3 retinal lesions in the macular region were made by means of a fine thermo-cautery in three monkeys. In a fourth, in which the ophthalmoscopic appearances of the outer parts of the optic discs were those of a restricted atrophy, no experimental lesion was performed. In all four the tissues were subjected to a microscopic examination. In the optic nerve the degeneration was found in all four cases to occupy a position at the outer side in front. Further back in the nerve the degeneration was central, and this position was maintained to the chiasma. In the chiasma the macular fibres occupy a central position at the anterior part on each side, but soon pass towards the dorsum. They occupy a dorsal position before crossing begins, and the first evidence of crossing is seen at the dorsal periphery some distance behind the front of the chiasma. Further back the macular fibres tend to spread from the dorsal position towards the ventral aspect, though they never reach the ventral periphery.

The writers of the paper are unable from their evidence to say definitely whether or not all the macular fibres cross at the chiasma. Vossius and Bunge found that the macular fibres in man occupied a dorsal position in the chiasma, while Henschen believed the position of these fibres to be central throughout the nerve, chiasma, and tract.

This paper is illustrated by excellent plates showing microscopic appearances, with a diagrammatic scheme showing the position of the optic nerve fibres in the chiasma.

A. H. H. Sinclair.

---

J. V. Paterson (Edinburgh). **Some Observations on the Lymph Flow Through the Eyeball in Man and Certain Animals.** *Journal of Pathology and Bacteriology*, March 1904.

With the object of investigating the paths by which the lymph flow in the eye is maintained, the author has experimented upon the eyes of the dog, cat, rabbit and monkey by intra

vitam injections of Chinese ink. Freshly enucleated eyes, considered to be normal, of human subjects, as well as freshly excised eyes from the dog, pig, sheep, rabbit and monkey were also made the subject of investigation. The author corroborates in most essentials the experiments of his predecessors in this field, but has nothing new which is of importance to add. The rapidity of the flow of fluid through the eye was also investigated with a practically similar result.

---

O. Haab (Zurich). **Atlas of External Diseases of the Eye.** Authorised Translation. Edited by G. E. de Schweinitz (Philadelphia). Second Edition. W. B. Saunders and Co., Philadelphia and London, 1903.

In our notice of the original German edition of this work it was pointed out that "no manual written in a foreign language could be expected to take a place here among our own smaller text-books." This edition of the excellent translation edited by De Schweinitz contains some dozen more of the excellent coloured plates which characterise this work. Those illustrating trachoma and staphylomata are especially good. The comments of the American editor, which are given in brackets, include references to the more recent additions that have been made to the ophthalmic surgeon's armamentarium. The book is one that can be most heartily commended to the English-speaking student of medicine, whether he be especially interested in ophthalmic disease or not.

---

E. E. Gibbons (Baltimore). **The Eye, Its Refraction and Diseases.** The Macmillan Company, New York, 1904.

This volume of almost 500 octavo pages appears to be one of a series, since it takes up only the refraction and functional testing of the eye. As regards these subjects, however, it is complete in itself, and compares well with most of the monographs dealing with these topics. The subject of refraction is illustrated by particularly clear and well-arranged diagrams. Algebraic formulas are used rather sparingly, but sufficiently to give a very good basis in physiological optics.

Many of the methods of examination and diagnosis, both recent and of earlier date, which have not found their way into the majority of text-books are briefly and clearly explained.

For example, Young's optometer, ophthalmoscopy by direct sunlight, Friedenberg's test for simulated blindness, the crossed cylinder or astigmatic cylinder for testing astigmatism, Hotz's astigmometer, and Derby's stereoscope, come in for adequate notice.

An innovation of practical value is a chapter upon the fitting of spectacle and nose glass frames to the face, with measuring of lenses. The training of the ophthalmic surgeon in these matters has often been so deficient that he has suffered in reputation from the mistakes of the optician, without being able to discover the trouble or direct the remedy.

The language of this work is good, its style simple and direct, the letterpress and the abundant illustrations are well printed. The only criticism to be offered regarding its mechanical execution is that the length of the lines passes the proper maximum of 4 inches without any apparent sufficient reason.

---

G. F. Suker (Chicago). **Decapsulation of the Kidney with Reference to Ocular Complications of Chronic Nephritis.** *Trans. Section on Ophthalmology, American Medical Association*, 1903.

The operation for decapsulation of the kidney has of late been quite widely done, in the hope of influencing favourably the course of chronic interstitial nephritis. The usual prognosis of Bright's disease after the appearance of albuminuric retinitis is well known. Suker has tried to collect all cases in which albuminuric retinitis was present when the operation of decapsulation was resorted to. He believed that from them some deductions might be made as to the influence of the operation in prolonging life. He was able to bring together 15 cases, which he presents in tabular form. Of these patients all but two were dead at the time his paper was prepared. One of these has died since, and the other gives a very questionable history. Four other cases, heard of since the reading of his paper, have all terminated in death. He concludes:—

The operation of decapsulation does not offer any hope in cases of bilateral chronic nephritis with retinal complicattions. Though there is an improvement in the fundus directly after the operation, it is decidedly temporary, to judge from the present statistics.

The operation may be of service in unilateral nephritis with fundus lesions in the initial stages. These cases, however, are rare, and soon become bilateral.

The mortality rate for albuminuric retinitis in chronic nephritis has not been lessened by the operation. Statistics show that retinal complications are a decided index as to the severity of the kidney involvement. In nearly all the cases of chronic nephritis cardiac involvement is present and is an important factor in prognosis. With the retinal lesions it is usually present.

As yet the medical treatment yields as good results as decapsulation, if not even a trifle better. Statistics of the mortality rate of albuminuric retinitis based on urethral catheterization are needed; to determine whether those who outlive the two years' period might be cases of unilateral nephritis or cases which are late in becoming bilateral.

E. J.

---

J. A. Donovan (Butte, U.S.A.). **Electro-Cautery Treatment of Corneal Wounds and Ulcers.** *Trans. American Academy of Ophthalmology and Oto-Laryngology*, 1903.

Living in a city where mining and treating ores is the principal industry, Donovan has to deal with a large number of corneal injuries. In former years he has employed all the usual methods for the treatment of such wounds and the ulcers that result from them. He followed the common practice of using the cautery as a last resort, and finding the more obstinate ulcers healed so nicely with it, he was led to employ it first. He believes the average simple, non-infected, corneal ulcer or wound will heal just as rapidly if it is simply protected, kept clean and left entirely alone, as it would with the most energetic treatment. If the wound is slight he gives nothing but boric acid and zinc wash, and instructs the patient to return in 24 hours. If there then be any irritation the spot is lightly touched with the cautery at a dull red heat.

For more serious ulcers he uses holocaine, cleans out necrotic tissue with a curette, and employs the electro-cautery in the following manner:—The point is heated to a dull red in most cases, though in some it does not reach even the degree of red heat. In the ordinary cases, the lightest possible

punctures are made all around the edge of the ulcer just in the edge of the healthy cornea, the punctures being about 1½mm. to 3mm. apart, and when necessary any part in its floor that appears unhealthy is touched. With few exceptions this is all the treatment necessary. If after a few days (say two to four) some places appear to have made no progress, these spots should be retouched. In the rare cases in which the ulcer does progress in some direction, the advancing portion should again be touched by puncturing just in the edge of the normal tissue.

This method of using the cautery he ascribes to Dr. Herman Knapp. Donovan believes that whenever a corneal wound or ulcer is severe enough to require treatment the electro-cautery is indicated. With proper appliances, in careful, competent hands its effects are absolutely controlled; and it is perfectly safe for persons of any age. Even for children he no longer uses chloroform.

E. J.

---

Gonin (Lausanne). **Ocular Lesions Caused by Lightning.** *Annales d'Oculistique*, February, 1904. Vol. cxxxi.

In this paper Gonin records a case of lightning injury which is interesting because the accident occurred under circumstances which seem to exclude the indirect action (light and ultra-violet rays), and to limit the effects observed to the direct action of the electric current. It occurred at a rifle shooting competition in a stand which was connected to the targets by electric bell wires. Twenty-six persons on the stand received more or less of a shock, although none of them saw any flash. The wires along which the lightning passed ran immediately above the patient's head. He was unconscious for a quarter of an hour, and on recovering found his left eye blind, while the right eye retained perception of light. Four days later Gonin found R.V. $= {}^{1}/_{10}$, L.V. $= {}^{1}/_{20}$, ciliary congestion, small pupils, and diffuse haze of both cornea closely resembling the appearance usual in acute glaucoma, although tension was normal. The corneæ cleared in a few days and the right disc could be seen to be pale with markedly narrowed arteries, while in the left eye there was a radiating opacity of the posterior cortex of the lens. Injections of strychnine were ordered, and during the following weeks the sight of the right eye improved to ½, that of the left to ⅓. The opacity in the left lens became con-

siderably less marked. Twelve weeks after the accident punctate opacity was observed in the right lens, situated immediately beneath the anterior capsule. When last seen, five months after the mishap, although the appearance of the lenses had not changed the sight of the left eye had fallen to one-tenth, with some contraction of the field. The discs remained pale with contracted arteries, and Gonin attributed the defect of sight to a slowly progressive optic atrophy.

The paper includes a résumé of the recorded cases of lightning injury, some thirty in number. In 22 of these opacities in the lens were found. In this connection the points of practical importance shown by examination of the published cases are:—

1. That lens opacities following on a lightning stroke may long remain stationary, and may even spontaneously disappear (Silfvast and Knies).

2. That fundus changes may interfere with the visual result of operation.

3. That operation may be made difficult owing to the marked relaxation of the suspensory ligament. This condition has been observed clinically, and was noted in the experimental work of Hess and Kiribuchi.

Optic atrophy appears to occur less often than cataract. In nine cases, including Gonin's, it was noted. In only two cases was the nerve affected without changes in the lens. (To these may be added Teacher Collins' case.)

It is of practical importance to remember that optic atrophy may be a late complication, and that therefore prognosis should be guarded.

Conjunctival hyperæmia, photophobia, and temporary haze of the cornea are commonly met with in cases of lightning stroke. Motor paralysis affecting the 3rd, 4th, 5th and 6th pairs, and usually of short duration, have been met with a good many times. Retinal hæmorrhages, rupture of the choroid, and detachment of the retina have been observed in a few instances.

Gonin emphasises the distinction to be drawn between this group and those cases in which eye symptoms follow dazzling by short-circuit flashes, etc. ("electric ophthalmia," so-called). In these only superficial changes are found, and the visual troubles are mainly functional. (See *Ophthalmic Review*, xxii., p. 172.)

Reviewing the various possible modes of action of the electric force, Gonin concludes that the grave pathological changes observed are due to the direct passage of the current through the tissues of the eye, and thinks that, although electrolytic action may play a subordinate part, the main effects are the result of mechanical concussion. For the arguments in favour of this view, as against the "ultra-violet rays" theory of Widmark and Silfvast, and the suggestion of Leber and Silex that the lens changes are due to coagulation of the albumen in the lens, and for a résumé of the experimental results obtained by Hess, Kiribuchi and others, Gonin's paper may be consulted.

As the number of published cases of lightning injury is small I append the references given.

W. W. Sinclair.

References.

Saint Yves. *Nouveau traité des maladies des yeux*, p. 368.
Himly. *Krankheiten und Missbildungen des Auges*, ii., p. 242.
Saemisch. *Klin. Monatsbl. für Augenheilk.*, ii., p. 23.
Downar. *Centralblatt für prakt. Augenheilk*, 1878, p. 69.
Reich. *Klin. Monatsbl. für Augenheilk.*, xvi., p. 361.
Yvert. *Traité des blessures du globe de l'oeil*, p. 211.
Leber. *Graefe's Archiv. für Ophth.*, xxviii., 3, p. 255.
Purtscher. *Graefe's Archiv.*, xxix., 4, p. 195.
Pagenstecher. *Archiv. für Augenheilk.*, xiii., p. 146.
Laker. *Archiv. für Augenheilk.*, xiv., p. 161.
Knies. *Graefe's Archiv.*, xxxii., 3, p. 236.
Meyhofer. *Klin. Monatsbl. für Augenheilk.*, xxiv., p. 375.
Uhle. *Klin. Monatsbl. für Augenheilk.*, xxiv., p. 379.
Vossius. *Berliner Klin. Wochensch.* Nos. 19 and 20.
Silex. *Archiv. für Augenheilk.*, xviii., p. 65.
Terrier. *Archives d'Ophtal.*, viii., p. 1.
Hess. *Seventh Internat. Ophthal. Congress*, Heidelberg, p. 308.
Buller. *Archiv. für Augenheilk.*, xxi., p. 390.
Vossius. *Beiträgs zur Augenheilk*, 1892. Heft 4.
Iwanoff. *Société Francaise d'Ophtal.*, xi., p. 463.
Rivers. *Archives of Ophthal.*, xxiii., p. 54.
Röhmer. *Archives d'Ophtal.*, xv., p. 209.
Kiribuchi. *Graefe's Archiv.*, li., p. 1.
Talko. *Zeitschrift für Augenheilk.*, v., p. 484.
Preindlsberger. *Wiener Klin. Wochenschr.*, 1901, p. 314.

Silfvast. *Zeitschrift für Augenheilk.*, ii., p. 320.
Terrien. *Archives d'Ophtal.*, xxi., p. 625.
To these may be added:—
Yarr. *Trans. Ophthal. Society*, 1901, p. 139.
Collins. *Trans. Ophthal. Society*, 1902, p. 114.

---

Birch-Hirschfeld and Kraft. **Eye Affections in Acanthosis Nigricans.** *Klinische Monatsblätter für Augenheilkunde*, March, 1904.

Acanthosis nigricans is a rare disease, the recorded cases of which have hitherto been confined to dermatological literature. It is characterised by the appearance of a brownish or blackish pigmentation of certain parts of the body, with, usually a little later, hypertrophy of the skin papillæ of the same regions, the degree of which varies from a mere deepening of the natural lines of the skin to the development of distinct small condylomata of 5 or more mm. in height. The neck and face, the middle of the chest and abdomen, the elbow and knee, hands and feet, and genito-anal regions are the districts typically affected. The mucous membranes also of the lips, tongue, gums and palate, of the nose, and occasionally of the larynx, may be the seat of papillary growths, but do not show any pigmentation. The eyelids are frequently attacked, the conjunctivæ seldom or never.

The disease developes sometimes gradually, sometimes almost suddenly; spontaneous regression has occasionally occurred. Most of the patients die of abdominal cancer, but the exact relationship between this and the skin affection is doubtful. Some have suggested that the abdominal disease causes an auto-intoxication which irritates the skin, others that a lesion of the abdominal sympathetic is the connecting link.

The skin growths are certainly not metastatic, for none of them show any trace of malignancy in their histological structure or clinical course; microscopically the chief features are enlargement of the papillæ of the corium, greatly increased thickness of the prickle-cell layer of the epithelium and some addition to the horny layer. Inflammatory appearances are generally absent. They are, in fact, simply warts.

The patient in the present instance was a woman of 68, who

had always had good health. Her account of the onset of the illness was that five months previously, after a bad cold, the skin of the neck became covered with closely-set itching warts; at the same time there was discomfort in the tongue and a sense of dryness in the throat. Some days later the excrescences appeared on the trunk, arms and legs. The affected parts were black at first, afterwards growing paler. Three months later the eyes began to water and itch, and the latter symptom becoming almost unbearable she presented herself for treatment at the eye clinic. About this time difficulty in swallowing solid food and a tendency to regurgitation were noticed. She had lost 34lbs. in the last year, and looked cathectic.

On examination the forehead presented brownish patches and broad-based non-pigmented excrescences, the neck was of a brown colour and shagreen-like aspect from the closely-set growths which covered it. On the sternum and nape of the neck were flat excrescences, the axillæ, the back, the nates and especially the anal folds were the seat of numerous papillæ; the extensor surface of the upper arm, the lower part of the fore-arm and hand, the knee and back of the foot were affected. The lips, palate, gums and tongue were also involved, the latter showing numerous clefts and depressions. A sound passed into the stomach encountered resistance at the cardiac orifice and came back tinged with blood, so that the presence of a malignant growth seemed very probable.

As regards the eyes, the lids were beset with flattened papillæ, mostly in rows, following the skin folds. They were most developed in the region of the lacrimal punctum of each lid, where in form and size they suggested a mulberry. Along the margins of the lids they pushed apart the lashes and gave a broad and serrated appearance to the edge. The conjunctiva was hyperæmic, but not papillomatous; only at the inner end of the right lower lid its surface showed small elevations, but these the author regards as a simple papillary conjunctiva, the result of the mechanical irritation of the tumours on the external surface. When the latter were extirpated the conjunctiva markedly improved. The ocular conjunctiva was quite normal.

Thinking that the papillæ on the lid margins by rubbing on the eye must cause the irritation complained of, the author removed them as completely as possible by scissors and knife. The bleeding was slight, the raw surface rapidly healed over,

leaving no perceptible scars, and the discomfort was much relieved, especially as the conjunctivitis also improved under zinc and protargol. Fresh papillomata had, however, developed in the course of a few weeks. The case seems worth recording for its intrinsic interest as well as its rarity.

W. G. L.

---

Fox (L. Webster.). **Diseases of the Eye.** Appleton, London and New York, 1904.

The author is Professor of Ophthalmology in Philadelphia, and the book which he puts forth is based upon his lectures to his students. His system of arrangement of subjects is a little unusual, for the structures are considered in the order in which they are encountered, proceeding from the front backwards. The subjects of refraction and ametropia come in, therefore, at the end of the book instead of in their familiar place near the beginning. Great pains have quite evidently been taken by the author both in the writing and in the illustrating of his book, but not with uniform success all through. For though some of the illustrations leave little to be desired, others teach just as little, and really are rather a blemish. As an example, the photograph of "Hutchinson's teeth" does not show either the characteristic shape or the still more characteristic notch. In his fidelity to truth, Fox has supplied a photograph where a diagram would have been much better. Figs. 76, 77, and 99 (keratitis of various types, corneal opacities, and sarcoma of choroid) are particularly poor. Fig. 97 is labelled "Normal Fundus," but it is very far indeed from typical, if not actually pathological. In regard to the letterpress, we do not thing highly of his account either of detachment of retina or of sarcoma of the choroid; indeed, these are notable examples of what seem to us to be perhaps the chief failing in an otherwise good text-book, a lack of definiteness, of emphasis on the really important diseases and on the most vital points to be noted in connection with them, and a tendency to quite needless diffuseness on subjects of no special moment. Between his account of detachment of the retina on the one hand, and of anæsthesia and anæmia of that membrane on the other, there is a disproportion almost absurd, when one considers their relative importance. If we say that these are the chief blemishes it will be seen that they are by no means fatal, and

are entirely corrigible in a new edition which we do not doubt will be called for ere long.

Several of Miss Washington's diagrams of ophthalmoscopic changes are excellent, and their reproduction has been skilful. A glossary of terms completes the book, but many of the terms are absolutely obsolete, have probably been so for a couple of centuries, and a few of them are not correctly interpreted. Emmetropia, for example, is *not* "normal or perfect vision," for an eye which is totally blind may yet be perfectly emmetropic; nor is Anopsia "upward strabismus." Fox has given particular attention to describing a great variety of operations for any given pathological condition, and when one has read through all the other methods one generally finds that the author, like his four-legged name-sake, has another "dodge" left still. The book needs considerable pruning and revision of its arrangement, which is especially faulty in dealing with the cornea, but with these improvements it will find a place for itself.

---

GRIMSDALE. **Errors of Refraction and Their Correction.** The Medical Times, Limited, London, 1904.

REGARDING this guide to the examination of errors of refraction there is little to be said either in favour or in blame. It goes over the familiar ground in the familiar way; it is simple, easily comprehensible, does not attempt too much. Mr. Grimsdale believes that it is necessary in all cases, unless where danger exists, to give a mydriatic before testing the refraction, and at the same time with charming simplicity gives an account of several cases in which he himself has demonstrated, even to his own satisfaction, the needlessness of so doing, and, in at least two cases, the error into which that procedure led him. He is surprised sometimes how little difference in the refraction is produced by atropin, but a little more consideration would have shown him that this is in reality only what might be expected. To suppose that every hypermetrope is *constantly* making efforts to correct his error is a delusion. The print, the few diagrams, and the paper are all, we regret to say, unattractive.

---

GOULD. **Biographic Clinics.** Vol. ii. Rebman, London, 1904. NOT discouraged by the somewhat cold reception of his first volume, but all the more determined to preach the gospel of eye strain in season and out of season, if need be, Dr. Gould issues a second series of studies in biography. Nine persons figure in it, including George Eliot and Mrs. Carlyle, Wagner and Whittier. The style of the volume, the purpose, and the conclusions, are of course the same as in the first. The author complains of the hostility and—worse still—of the indifference of his critics; but, indeed, he has nothing to which to point worse than he says repeatedly of his professional brethren himself. Thus, speaking of Wagner, he says: "Were he living to-day he would in all probability not find any oculist or physician in Germany that would help him or care to help him in the one possible and effective way." Such expressions are frequent, contemptuous references to those who do not see their way to hold his extreme views occur all through the book. Now, if a man has a new gospel to deliver, if he really believes, as we frankly grant Dr. Gould believes honestly, that he has it as his mission in life to drive some message home, he ought at least to be so purified by this sacred trust that he has no room in his mind for vulgar abuse.

The main body of the book is not very interesting, nor, indeed, very convincing. One knows the conclusion at which Dr. Gould is bound to arrive, and, be he right or wrong, the knowing it beforehand spoils the reading. The parts most interesting are the last chapter on Eye-strain and Civilisation, and the appendix giving Sixty-eight Reasons why "Glasses did not give Relief." And these are the parts which the author would have done well, we think, to leave out, for should any man of well-balanced mind have been, from the clinical studies, almost persuaded of Dr. Gould's correctness, he would probably be frightened away again by the egotistical and dogmatic absurdities of the appendix and last chapter. "A third of a diopter of asymmetric astigmatism is a hundred times worse for the general system than high defects. The high defects produce criminals, or ruin the eye itself; the low defects, unrecognised by bunglers, produce the thousand morbid reflexes" (332). "I answered that I had never seen a pair of eyes with no ametropia" (334). This last seems to us to some extent to tell against Gould's own conclusions, for if it be true, then how does it come about that a condition which is constant

can produce pathological results? "No discovery of modern medicine, except vaccination and the germ theory of disease, is of so great importance as this of eye strain" (337). "Everyone of a hundred different lethal and organic diseases which finds foothold through the vague but awfully real fact called denutrition, may, and frequently does, find that foothold through the eye strain . . ." (339). "Eye strain is one of the greatest of all causes of domestic infelicity" (340).

Among the sixty-eight reasons referred to are: (6) The oculist may not be morally right-minded in carrying on his work and in the conception of his function in life; (9) he has not devoted himself exclusively to refraction; (13) he relies upon objective, instead of, when possible, upon subjective methods of diagnosing ametropia; (14) he does not use a cycloplegic; (15) his cycloplegic may not be of the right kind; (16) it may not be of good quality; (17) the cycloplegic must be rightly instilled. Under 24 we learn that the case of test lenses in common use is hardly less ridiculous than the trial frame, and that good refraction requires handles to the lenses about three-fourths of an inch long. Nine-tenths of all glasses, it seems from 62, are set too far from the eye, and the correct position is not to be obtained in the majority of cases except by partial clipping of the upper central eyelashes, which must be repeated once a month. If Dr. Gould has a sound and sane desire to encourage precision in examination of refraction and a strong opinion that on errors of refraction depends much of the world's unhappiness, he does his own cause grievous harm by the publication of such puerilities as the samples which we have given. We do not suppose for a moment that Dr. Gould will condescend to pay attention to protests from a country which in his book is here and there referred to with a sort of acid pity, but his writings for all that would be better received here were he not to take such liberties as he does with a language which, after all, was ours to start with. What are "physicly," to "refract" (in the sense of to ascertain the refraction), "dispiritment," "malfunction," "improcreance?"

---

JUL. PFISTER (Lucerne). **Current Views on the Nutrition of the Lens and the Formation of Cataract.** *Correspondenz-Blatt für Schweizer Aerzte*, January, 1904.

"How does grey cataract originate? Can it be prevented?

Is it possible to stop the progress of the change once it has commenced? To these questions answers are repeatedly demanded, not only of the specialist, but also of the general practitioner." The author proceeds to set forth the data bearing upon these points. He brings no new evidence, but carefully weighs the work of others.

The tendency of the crystalline lens to the changes which are known as cataract, arises from the peculiarity of its nutrition. The lens is pre-eminently the example of the disability under which a non-vascular structure lies, in the second-hand source of its nutrition. The disability is present in early fœtal life when the capsule is enveloped in a vascular tunic with a particular arterial supply; it is accentuated when, with the development of the fœtus this supply is lost.

Changes in the osmotic pressure of the fluids circulating about the lens, and particularly in those secreted by the ciliary body, whether due to the general toxic causes or to local disease of the iris and ciliary body, are factors in the production of cataract. But the initial factor, the author believes with Kiribuchy, lies in the loss of activity or the death of the lens epithelium. To this is credited the utility of the operation of massage for the artificial ripening of cataract; the epithelium is disorganised by the massage, the check which the active epithelium exerts upon the osmosis between the lens substance and the surrounding fluids is lost. On the influence of local hyperæmia, he cites the researches of v. Geuns and v. Reuss, and particularly the case reported by the latter (*Centralb. f. prakt. Augenh.*, February, 1900, p. 34), where, with a repetition of an iritis, the cataract was rapidly absorbed and vision was restored. These opinions are supported by the experimental production of cataract by the administration of naphthaline, and by the heavy incidence (82 per cent.) of the initial changes in the equator of the lens.

Similarly in diabetic cataract, he holds that the work of Deutschmann shows that the degeneration of the lens is not solely due to the presence of sugar changing the osmotic pressures, though this factor is present. In a case of diabetes in a girl Deutschmann found 0·5 per cent. of sugar in the aqueous humour, 0·366 per cent. in the vitreous humour, and as much as 8 per cent. constantly present in the urine, yet there was no cataract. Whilst in a dead eye the injection of

a 5 per cent. sugar solution into the anterior chamber caused the lens to become opaque in 14 hours. Again Deutschmann found that the experimental injection of 10 per cent. solution of common salt into the aqueous of dogs caused disintegration of both the lens epithelium and that of Descemet's membrane.

Reverting to his three questions, the first he finds answered in the consideration of the nutrition of the lens. To the second—Can cataract be prevented? He answers, No. Save perhaps when toxic causes are at work. To the third—Can its progress be hindered?—the reply is also negative.

In conclusion he discusses the hypothesis of Schön, that long continued and irregular action of the accommodation, such as is entailed by uncorrected astigmatism, has a damaging effect on the lens and so favours the origin of cataract. He allows the possibility of the connection, and accordingly emphasises the necessity of correcting such errors and also presbyopia.

N. Bishop Harman.

---

S. Bernheimer (Innsbruck). **The Cerebral Connections of Ocular Movement.** *v. Graefe's Archiv für Ophthalmologie*, 57, 2.

That there are certain essential connections between the angular gyrus and the nuclei of the eye muscles is quite admitted; on stimulation of that region regular bilateral movements of the eyes towards the same side always follow. This is particularly true of the middle third of both limbs of the gyrus, by careful stimulation of which in the monkey movements upwards, downwards, to right and to left, can be elicited. Provided the stimulus applied be mild, the eye movements are uncomplicated; otherwise the face and head participate in the movements, and if the stimulus be more severe still, other and more distant parts of the brain are implicated also. A number of writers have on account of similar conditions laid it down as a rule that eye movements may result from stimulation in many situations in the cerebrum. In particular there is one bundle of fibres running from the large ganglion cells of the cortex of the visual area to end in the nuclei of the motor nerves of the eye; these bring the visual and the motor regions into close relation, but the

number of fibres is so small that the bundle is regarded as merely an accessory reflex path. This is to some extent borne out by the fact that on cortical stimulation the resulting eye movements are uncertain, and it is only when a strong current is employed that bilateral movements actually occur. Although it is the case, then, according to the author, that the angular gyrus is the place of origin of concerted and harmonious movements, the paths by which these impulses travel are still uncertain. It has been usual to consider that in the anterior corpora quadrigemina was a reflex centre in which the fibres from the angular gyrus ended. Bernheimer has already cast doubt upon this supposed function of the anterior corpora; he has been able with great difficulty to remove the whole corpora quadrigemina in certain apes and yet keep the animal alive for a time. In them he found that the eye movements set up by the stimulation of the angular gyrus took place as readily and as correctly as when the corpora were present. In no particular was there any change in the movements. In another series of monkeys he cut through the tissue under the aqueduct of Sylvius, keeping precisely in the middle line, in such manner that the section reached as far as, and even through, the nuclei of the third and fourth nerves. This was done in some instances along with, in others without, destruction of the cortex of the corpora, but in no animal was the same strength of current as had formerly sufficed able to bring about those eye movements. On direct stimulation of the nuclei movements of course took place, but these were not synergic; they were irregular, and affected now one eye, now the other. Similar unregulated movements occurred on somewhat stronger stimuli being applied to the body or extremities of such animals (provided they were capable of response). These experiments go, then, to show that the paths for ocular movements set up in the angular gyrus do not pass through the corpora quadrigemina in order to reach the nuclei of the muscles, but must take a course under the aqueduct. If the author is correct, the corpora quadrigemina cannot be regarded even as a reflex centre for ocular movements, for such cortical impulses do not pass through them.

Bernheimer next describes the method by which he was able to remove the entire left angular gyrus in three monkeys, two at least of which remained bright and lively thereafter. He found that they could turn their heads freely to the right;

left movement of the head was also readily executed, but if the head was kept fixed the eyes could not be moved to the right, and when the animal was allowed freedom, objects to the right were fixed only when the head, or even the whole body, was turned round. There was at the same time no conjugate deviation to the left. In two of the animals on which the operation was performed (the third sustained some injury in its cage and ceased to be available) the symptoms appeared to pass off in little more than a week, but, of course, precise observation of a matter so difficult is not to be expected; it is sufficient that the incapacity was present for a time and gradually passed away again. The whole connection between the volitional centres and the muscular apparatus must then not have been completely severed; impulses must have travelled by some other route, a fact which is in entire accord with our knowledge of the subject otherwise gained. Sections were made of the hardened brain in such a manner as seemed best calculated to display the connecting fibres between the gyrus and the thalamus and corpora quadrigemina. Towards the cortex these fibres diverge rapidly, but as they proceed they become gathered into a somewhat flattened bundle, as may be seen by proper staining, and they again spread out as they are distributed in the substance of the thalamus. Thereafter appearances differ a little according to the precise level of the section. As the degenerated bundle passes on to reach the regions of the nuclei of the ocular muscles under the aqueduct, it is most massive where the pulvinar and the anterior corpus meet. In sections which show the aqueduct one can see, under it and laterally placed with reference to the nuclei there, a conspicuous number of degenerated fibres in transverse section; both sides are thus affected, but that opposite to the wounded hemisphere much more so than the other. Not all of the fibres of such a bundle are cut in cross section, some lie obliquely, and some almost longitudinally. From these facts it is plain then that the corpora quadrigemina do not lie in the path of these degenerated fibres. It was not found possible in the sections as made to discover the precise crossing place of some of the fibres taking origin from one gyrus angularis.

W. G. S.

---

C. A. Wood (Chicago) and T. A. Woodruff (Chicago). **The Commoner Diseases of the Eye. How to Detect and How to Treat Them; for Students of Medicine.** C. P. Engelhard and Co., Chicago, 1904.

Surely of the making of books there is no end, and most especially does this apply to the smaller works, mainly introductory in character, which are offered to the student of medicine, when he first approaches the various subjects of his curriculum. With the vast mass of material which has accumulated in the various departments of the practice of medicine the necessity of these so-called "compends" has become apparent.

In order to produce a book of this nature, at once clear and yet not too condensed, a very careful judgment and a thorough knowledge of the subject matter are necessary. Drs. Wood and Woodruff are certainly to be congratulated on the success which has crowned their efforts in this direction. This little work in a very succinct manner puts before the reader the salient points of ophthalmology, and only in a few particulars is clearness sacrificed to brevity, *e.g.*, in the article on colour blindness, where the tests might have been a little more elaborated.

The latest advances in diagnosis, treatment, and bacteriology are touched on and very clearly put; the illustrations are numerous, and many are very useful, but why should a full page be wasted on a catalogue illustration of a case of test lenses? No book has ever yet appeared which has not had its faults, but of this one we may fairly say that it really fulfils the modest claims of its authors.

## CLINICAL NOTES.

Subconjunctival Injections.—Hosch speaks in favour of injecting cyanide of mercury solution in cases of post-operative irido-cyclitis, and to those who employ copious injections of salt solution utters a warning that this procedure may have some effect in promoting the formation of cortical cataract. In a note on *Metallic Foreign Bodies in the Retina,* the same author throws doubt on the idea that they can ever remain permanently harmless. In one case an eye became inflamed after five months of apparent immunity, and in another after more than a year.—*Archiv für Augenheilkunde,* March 1904.

Astigmatic Accommodation.—Koster (Gzn.) watched the effect of eserin at various periods after its instillation in the eye of a young man who had less than the normal amount of accommodation. After 50 minutes he found that astigmatism to the extent of 2·5 D had been produced, which at a later period disappeared. This astigmatism must have been lenticular and must have been produced by an irregular contraction of the ciliary muscle, and from this he argues that in cases of ordinary corneal astigmatism there is nothing in the structure either of the ciliary muscle or of the lens to prevent compensatory astigmatic accommodation from taking place.—*Archiv für Augenheilkunde*, March, 1904.

Mirmol is a fluid whose principal constituent is formaldehyde. It was brought out in 1899 by Ranelletti, and has been employed chiefly by Italian surgeons in cases of inoperable cancer. Maurizi (Rome) speaks highly of its value. He has recently employed it in a case which, according to the clinical history, presented every feature of recurring epithelioma, and he has by its means obtained a cure. The actual part affected in this case was at the inner canthus, and the substance was employed two or three times a day diluted at first 1 in 9, but later in greater concentration, by means of gauze wetted in it, after a few drops of cocain had been applied. There was little or no pain, and almost immediately the ulcer began to "clean," and in a few weeks the patient was discharged without a trace of his malady, and with only a very slight dimpling to mark the spot.—*Bollettino dell' Ospedale Oftalmico*, Rome, March 3, 1904.

Iritis Following Bee-sting.—That general symptoms may follow upon the receipt of a bee-sting is well known, but iritis is a very unusual symptom. Hilbert (Sensburg) relates the case of a woman of 63, who on the day following receipt of a bee-sting consulted him. She had been stung on the left upper lid, and during the night had applied wet clay with but little relief to the pain, while the swelling had greatly increased. Both lids of the left eye, and the cheek, were greatly swollen and of a bluish red colour. The actual point at which the sting had entered was close to the inner canthus, and thence Hilbert removed it, for it was still *in situ*. On separating the lids—a very painful and difficult process—conjunctivitis and marked ciliary injection were found to be present, and there

was even a little hypopyon. The patient complained of considerable weakness, her skin was cool and moist, the pulse was slow (52) and thready, the breathing also slow and shallow. Under treatment by atropin the condition improved at once, but it was at least four weeks before the eye could be pronounced free of trouble.—*Wochenschr. für Therapie und Hygiene des Auges*, March 26, 1904.

---

TENTH INTERNATIONAL OPHTHALMOLOGICAL CONGRESS.

We have been requested by the Committee in charge of the arrangements to draw attention to the fact that the first portion of the report of the Congress is about to be issued, but that this will be sent only to those who send in their names in time to Prof. Mellinger, Basel.

The Committee would also remind intending members of the Congress of the very convenient system of tickets issued by the Swiss railways entitling the purchaser to travel where he pleases over their rail and steamship lines during 15 or 30 days. These cost 70 or 100 francs for the first-class and 50 or 75 francs second-class respectively; the photograph of the purchaser must be attached to the ticket. These are also issued in Paris and in London (Victoria and London Bridge) with corresponding increase in the length of time during which they are valid.

---

# Bibliography.

## Anatomy and Physiology.

Meltzer and Auer. Paradoxical pupil dilatation. *American Jl. of Physiology*, April, 1904.

## Congenital Abnormalities.

Nicodemi. Colobomata of the fundus. *Ann. di Ott.*, 33, 6.
Oeller. Coloboma of upper lids of both eyes. *Arch. f. Augenhk.*, 50. i.
Polte. Congenital tubule formation in vitreous and malformation of papilla. *Zeitschft f. Augen.*, June.
Stephenson. Two cases of microphthalmos. *Brit. Jl. of Children's Diseases*, June.

## Hygiene.

Truc and Chavernac. Ocular hygiene in the communal schools at Montpellier. *Rev. gén. d'Ophtd.*, 31st May.

## Pathology and Bacteriology.

Addario. Acute trachoma. *Ann. di Ott.*, 33. i.
Leber. Remarks on the inflammatory action of certain micro-organisms on the eye and other parts of the body, with special reference to the cause of sympathetic ophthalmia. *v. Graefe's Archiv*, 58. 2.
Romer and Stein. Site and nature of paresis of accommodation in bacterial intoxication, i. *v. Graefe's Archiv.*, 58. 2.
Streiff. Serous cysts of the iris. *Arch. f. Augenh.*, 50. i.
Ulbrich. Action of saprophytic bacteria introduced into the eye. *v. Graefe's Archiv.*, 58. 2.

## Instruments and Apparatus.

## Therapeutics.

Alexander. Subconjunctival injection of salt solution. *Arch. f. Augen.*, 49, 4.
Culbertson. Rubber-dam dressing. *Amer. Jl. of Ophth.*, April.
Elschnig. Subcutaneous injections of saline in amblyopia following hæmorrhage. *La Clin. Opht.*, 25th May.
Heath. Injection of air into anterior chamber. *Ophth. Record*, May.
Hinshelwood. Newer remedies. *Glasgow Med. Jl.*, June.
Moriez. Climate of the maritime Alps. *La Clin. Opht.*, 25th May.
Schanz. Use of Yellow Ointment. *Zeitschrift f. Augen.*, June.
Terson. Permanganate and dionine compresses. *La Clin. Opht.*, 10th June.

## Operations.

Manolesco. Iritomy. *Ann. d'Oc.*, May.
Mazet. Keratectomy. *Rev. d'Opht.*, May.
Suell. Removal of Lens in high myopia. *Amer. Jl. of Ophth.*, April.
Suker. A modified advaucement. *Amer. Jl. of Ophth.*, May.
Sureau. Blepharoplasty. *La Clin. Opht.*, 10th June.
Terson. Operation for trichiasis. *La Clin. Opht.*, 10th June.
Villard. Tarso-marginoplasty in trichiasis of the upper lid. *Rev. d'Opht.*, May.

## Traumatisms.

Ewing. An experience with the sideroscope. *Amer. Jl. of Ophth.*, May.
Ferron. Lesion of cranial nerves from gunshot injuries. *Ann. d'Ocul.*, May.
Haass. Case of indirect rupture of choroid. *Zeitschrift f. Augen.*, June.
Krauss. Double perforation of globe by piece of steel. with view of ciliary processes. *Zeitschrift f. Augen.* June.
Risley. Danger of large magnet. *Amer. Jl. of Ophth.*, May.

## Tumours.

Johnston. Dermo-lipoma of conjunctiva. *Ophth. Record*, May.
Johnston. Papilloma of conjunctiva. *Ophth. Record*, May.
Reis. Differential diagnosis of sarcoma combined with phthisis bulbi. *Arch. f. Augen.* 50. i.

## Sympathetic Ophthalmia.

Leber. Remarks on the inflammatory action of certain micro-organisms on the eye and other parts of the body. *v. Graefe's Archiv.*, 58, 2.

## Glaucoma.

Hale. Iridectomy for glaucoma. *Ophth. Record*, May.
Searles. Malignant glaucoma. *Amer. Jl. of Ophth.*, May.

## Amblyopia and Visual Defects.

Feilchenfeld. Are anomalous trichromats admissible for railway service? *Arch. f. Augen.*, 50. i.
Wilder. Methyl. alcohol amblyopia. *Ophth. Record*, May.

## Refraction and Optical Questions.

Brandes. Astigmatic accommodation on unilateral application of homatropin and eserin. *Arch. f. Augen.*, 49, 4.
Kothe. Disparation in length and over-plasticity of near objects. *Arch. f. Augen.*, 49, 4.
Parinaud. Stereoscopy and visual projection. *Ann. d'Ocul.*, May.
Spengler. Curvature of the field of vision. *v. Graefe's Archiv.*, 58, 2.
Vallet. A case of correction of astigmatism in an anisometrope. *Record d'Opht.*, May.

## Regional Affections.

### Eyelids.

Birch-Hirschfeld. Histology of xanthelasma. *v. Graefe's Archiv.*, 58, 2.
Erdmann. Distichiasis congenita. *Zeitsch. f. Augen.*, May.
Fejer. Diseases of the tarsus, esp. Chalazion. *Arch. f. Augen.*, 50, i.

## Lachrymal Apparatus.

Alexejeff. Concretions in the lachrymal ducts. *Arch. f. Augen.*, 49, 4.
Cause. Metastatic dacryoadenitis in gonorrhœa. *Zeitsch. f. Augen.*, May.

## Conjunctiva.

Johnston. Dermo-lipoma. *Ophth. Record*, May.
Johnston. Papilloma. *Ophth. Record*, May.
Salva. Parinaud's conjunctivitis. *Dauphiné Médical*, March.

## Cornea and Sclerotic.

Charles. Dendritic keratitis. *Amer. Jl. of Opht.*, April.
Lauber. Scleral cysts. *v. Graefe's Archiv.*, 58, 2.
Rollett. Hereditary syphilitic keratitis. *Amer. Jl. of Opht.*, April.
Schreiber. Vital indigo-carmin staining of the cornea. *v. Graefe's Archiv.*, 58, 2.
Stasinski. Keratitis neuroparalytica due to periostitis of the superior maxilla. *Zeitsch. f. Augen.*, May.

## Iris and Ciliary Body.

Bartels. Investigation of the pupils by gas light. *Zeitsch. f. Augen.*, May.
Heath. Tubercular iritis. *Ophth. Record*, May.
Streiff. Serous cysts of the iris. *Arch. f. Augen.*, 50, i.
Vídeky. Irido-cyclitis, retrobulbar abscess, and cerebral abscess. *Zeitsch. f. Augen.*, May.

## Lens.

Lingsch. Traumatic cataract after lightning. *Wiener. Med. Woch.*, 4th June.
Zur Nedden. Origin and course of traumatic posterior cortical cataract. *Zeitsch. f. Augen.*, May.

## Choroid and Vitreous.

Haass. Case of indirect rupture of choroid. *Zeitschft f. Augen.*, June.
Reis. Differential diagnosis of sarcoma combined with phthisis bulbi. *Arch. f. Augen.*, 50, i.

## Retina.

Ammann. Detachment of the retina. *Zeitsch. f. Augen.*, May.
Lenders. An atypical glioma. *v. Graefe's Archiv.*, 58, 2.
Shoemaker. Obstruction of the central retinal artery. *Amer. Jl. of Med. Sc.*, April.
Yamaguchi. Albuminuric retino-chorolditis. *Zeitsch. f. Augen.*, May.

## Optic Nerve.

Cramer. Juvenile forms of non-toxic chronic retrobulbar neuritis. *Zeitschft f. Augen.*, June.
Oliver. Ophthalmic conditions in a case of cerebellar neoplasm in a subject with renal disease. *Amer. Jl. of Med. Sc.*, June.

## Muscles (and Strabismus).

Bartels. Vicarious contraction of the frontalis in congenital ptosis. *Zeitsch. f. Augen.*, May.
v. Bechterew. Paralysis of the M. orbicularis oculi in cortical and sub-cortical facial paralysis. *Centr. f. Nervenheilk. u. Psychiatrie.*, 15th May.
Bielchowsky. Paralysis of the M. obliquus inferior. *v. Graefe's Archiv.*, 58, 2.
Oppenheimer. Unilateral Nystagmus. *Deutsch. Med. Woch.*, 2nd June.
Theobald. Over-correction of convergent squint without operation. *Amer. Jl. of Ophth.*, April.
Wilkinson. Rare nervous lesions. *Ophthal. Record*, May.

## Orbit and Globe.

Veasey. Orbital hæmorrhage followed by metastatic choroiditis. *Ophth. Record*, May.

## Relations with Medicine.

Ascher. Symptoms of lesions of corpus striatum. *Zeitschft f. Augen.*, June.
v. Bechterew. Implication of the orbicularis oculi in cortical and sub-cortical facial paralysis. *Centr. f. Nervenheilk. u. Psych.*, 15th May.
Joffroy. Ocular symptoms in general paralysis. *Arch. de Neurol.*, May.
Posey and Swindells. Unilateral exophthalmos in exophthalmic goitre. *Ophth. Record*, May.
Sachs. A case of amaurotic family idiocy. *Bull. of Johns Hopkins Hosp.*, March.
Terson. Ocular lesions in varicella. *La Clin. Opht.*, 10th June.
Vincent. Unilateral constriction of the pupil in phlegmonous angina. *Bull. et. Mém. de la Soc. Méd. des Hôpitaux de Paris*, 26th May.

## Miscellaneous.

Galezowski. On the importance of diagnosis in ocular affections. *Rec. d'Opht.*, May.
Ruata. Tropical Diseases of the eye. *Ann. di. Ott.*, 33, 6.
Schmeichler. Simulation of eye diseases. *Wiener Med. Woch.*, April, May, and June.

# BILATERAL AMAUROSIS FOLLOWING SEVERE HÆMORRHAGE AFTER EXTRACTION OF A TOOTH—PARTIAL RECOVERY.

By J. W. Stirling, M.B. (Edin.), etc., *Lecturer in Ophthalmology, McGill University; Assistant Ophthalmologist, Montreal General Hospital; Consulting Oculist, Montreal Dispensary, Foundling Hospital.*

The comparative rarity of optic nerve atrophy following severe hæmorrhage has suggested to me the advisability of publishing the following case, more especially as I am unable to find among the recorded cases one in which the hæmorrhage was due to extraction of a tooth.

One case has been reported in which excessive hæmorrhage, after the extraction of some teeth, was followed by the development of cataract, but the maxillary hæmorrhage was immediately followed by a profuse menstrual hæmorrhage. A lamellar cataract had been present and rapidly ripened after the hæmorrhage, likely from the disturbed nutrition due to the hæmorrhage. (Pihl, *Centralb. für Augen.*, 1900.) A most elaborate resumé of this subject, and of the recorded cases, written by Groenouw, of Breslau, appears in the Graefe-Saemish Hand-book at present being published in Leipzig. I shall have occasion to refer to this work after appending the notes of my own case.

V. M., an anæmic-looking boy of $5\frac{3}{4}$ years, was brought to me at my clinic in the Montreal General Hospital in October, 1903. The mother wished to know if anything could be done to restore the child's vision, which was very poor.

The history I obtained was as follows:—Twenty-three months ago a tooth was extracted, which was followed by uncontrollable hæmorrhage which lasted three to four days. The child became almost pulseless and unconscious. On recovery of consciousness the vision was found to be entirely lost, but in the course of two weeks vision returned to a slight degree, since which there has been very little or no improvement of it. The mother also gave me a history of excessive bleeding about a year or more previously from a slight wound above the left orbit. The child is evidently a bleeder.

The vision at present amounts to the perception of fingers at six inches distance with each eye, there is no appreciation of colour, the field is concentrically contracted to within 15 to 20° of the fixation point, the pupils are 5 millimeters in diameter, and are immobile or barely oscillate to light.

Examination of the fundi show both discs chalk white, with edges lacking in sharpness, and with a filled-up appearance, rather than the shrunken appearance due to primary atrophy. Some faint white streaks extend along the retinal arteries a short distance from the disc. There are no signs of old retinal hæmorrhages. The vessels are only slightly diminished in size, this diminution being mainly in the arteries, the veins appearing of nearly normal size. No improvement of vision can be obtained. The appearances are those of partial optic atrophy secondary to an optic neuritis.

The cases so far reported have been mostly due to severe intestinal hæmorrhage, then next in frequency are uterine hæmorrhages and leeching or bleeding, and finally a very few due to nasal hæmorrhages, bleeding from wounds, hæmoptysis and urethral hæmorrhages. The

severe visual symptoms would seem to occur in individuals already in a depressed state of health. Rarely is only one eye affected. Several hæmorrhages may occur without causing the loss of vision or the blindness may appear after the first and clear up, to recur with each succeeding hæmorrhage, and finally in some cases becomes permanent, or again the blindness may be permanent from the very first. The blindness in the majority of cases does not set in until three to six days after the hæmorrhage, in about a quarter of the cases immediately after the hæmorrhage, and in a few as late as the eighteenth day. The visual disturbance may last from a quarter of an hour up to several days in the few cases which do recover, but in the large majority of those which do improve, this improvement does not set in sooner than some weeks or months. Fully one-third remain totally blind in both eyes, one-fifth have betterment of vision in one eye, and a fairly good visual acuteness has been observed in only 8 per cent. of the total number of cases. The fundus of the eye in most of the cases shows a pale indistinct disc with narrow arteries and some venous hæmorrhages. The fields of vision are contracted in varying degrees and forms, this, with the degree of diminution of the colour and light sense, depending on the severity of the pathological changes giving rise to them. As to the exact pathology, we are rather in the dark. The seat of the changes may be in the brain, the optic nerve or the retina, but the existence of monocular cases favours the possibility of the latter two being the affected area in, at any rate, many cases, and still further in the cases which have been examined ophthalmoscopically within the first day or two after the hæmorrhages, marked changes have been found in the nerve and retina.

The following have been held to be among the main causes of the ocular condition, viz.:—Hæmorrhage into the optic nerve sheaths, optic neuritis with ensuing atrophy, a cerebral anæmia with outpouring of lymph, which lymph on the refilling of cerebral vessels is forced into the intervaginal space of the optic nerve causing an œdema of the nerve sheaths. Complete blindness with retained pupillary reaction would point to an œdema of the cerebral visual centres. Those cases in which blindness occurs immediately after the hæmorrhage are held to be due to anæmia of the brain or also of the peripheral part of the visual apparatus. Theobald mentions thrombosis of central artery of retina as a cause.

Holden, of New York, in 1899 conducted a series of experiments on dogs and rabbits, and his deductions are that an œdema and degeneration of the ganglion cells of the retina occur first, and later a similar process in the nerve fibres. These are the theories which have been so far advanced.

These notes have been drawn from Fries' and Groenouw's articles. The former managed to collect one hundred and six cases, which have been reported, during the past 235 years—a truly exhaustive work. There remains but little for me to add in regard to my own case; there has been no change in the eye condition during the four months he has been under observation.

Holden's hypothesis seem to be the most simple explanation of the pathological changes in many of the cases, the slight swelling and later indistinctness of the nerve head tallying with the idea of an œdema. The sudden blindness in some cases is due no doubt to profound anæmia, the intraocular pressure exerted on the greatly lessened resistance of the vessel's walls, especially where

they dip over the disc in turning backwards, being capable of accentuating the existing intraocular anæmia. Venous hæmorrhages occur through the degenerated venous walls. Œdema and degeneration set in forthwith in the ganglion layer, and it simply depends on the rapidity of the recovery of the circulation as to how far this degeneration may go on, or how permanent it may be.

---

## AN ELEVATOR-FORCEPS.

By Adolph Gad, M.D., Copenhagen.

The instrument consists of two tiny hand-specula, joined together in the form of a common pair of forceps, and bearing on the top of the curvature the forceps-claws. It is used in the following way: the patient looks downwards, the upper lid is lifted and the instrument introduced with its branches closed as a common speculum; the lid is then drawn upwards and by letting the branches open you catch hold of a fold of the conjunctiva alone or together with the tendon of the rectus superior. In this way the fixation of lid and globe is sufficient for a series of smaller

operations, as sub-conjunctival injections, removal of foreign bodies, etc.; for larger operations a finger or a hand-speculum must draw the nether lid downwards. I believe that in very many cases this instrument can supplant advantageously the sometimes troublesome stop-speculum.

Dr. O. Bull, from Christiania, will exhibit the instrument at the approaching meeting of the British Medical Association.

It is made by C. Nyrop, surgical instrument maker, Copenhagen.

---

## REVIEWS.

C. Hess (Würzburg). **Observations on the Accommodation.** *Klinische Monatsblätter für Augenheilkunde.* Vol. xlii., p. 309.

These new experiments of Professor Hess may be of interest in connection with the recent articles in this *Review.* They have been brought forward as a reply to a recent paper of Tscherning's.[1] The experiments are all simple and may be easily repeated.

1. Tscherning declared that the Helmholtz theory must be given up since the form of the lens in accommodation does not correspond with its form in equilibrium. For this latter he measured the radii of curvature of the anterior surface of the lens in an eye opened so that the whole anterior surface of the lens was exposed to air. Professor Hess had earlier denied the assumption that the above lens would have the same form as when totally surrounded by fluid, since a lens in air presses on its support with a weight of 174mg., while in water with only the weight of 11mg., a difference of 163mg. This is sufficient with such a soft body as the lens to cause a change of shape. He now devised the following experiment. The lens obtained from the eye of a monkey immediately after its death is so placed on a horizontal tray that its equatorial diameter is vertical. This is immersed in a glass dish with parallel sides, filled with normal salt solution. When completely surrounded by fluid the lens only touches the plate at a point, but on removing the solution by a pipette until there is more or less of the lens exposed to air, the periphery of the lens flattens so that more or less of its circumference is in contact with the horizontal tray. There is a distinct change of shape perfectly visible to the naked eye. The same result was obtained with the human lens from an infant and an adolescent of 19 years of age.

2. Tscherning stated that he could cause increased curvature of the central part of the anterior surfaces of lenses from oxen and dogs by pulling on the zonular fibres. But it is not necessary, therefore, that accommodation should be caused by tension of the zonula. For this one must prove that such increased curvature can be caused by tension only and not also by relaxation of the zonula. In the eyes of monkeys the ciliary body and choroid are loosely connected with the sclerotic. After removal of the cornea and iris and pulling on the ciliary body with fine forceps at two or four points, Professor Hess observed that the image of a dimmed incandescent lamp reflected from near the central pole of the anterior surface of the lens became larger, while on relaxing the tension the image became smaller. The same experiment with the eye of a new-born infant gave the same result. This proves that the curvature of the central part of the anterior surface of the lens diminishes with slightly increased tension, and increases on the diminution of the same.

3. Tscherning has supposed that the descent of the lens towards the end of the accommodation, discovered by Professor Hess and proved by him to be due to gravity, was merely a displacement of the "crystalline substance" "by reason of the relaxation of the posterior capsule,"[2] since the image obtained from the anterior surface of the lens is not displaced at all or only very little. But it is not justifiable to argue that the anterior surface does not move because the reflection image from the anterior surface moves slightly or not at all. A movement of the image of a stationary light always indicates a movement of the lens, but on the other hand a movement of the lens does not always express itself as a movement of the image. As Professor Hess pointed out, if one holds an ordinary convex lens so that he sees distinctly the anterior and posterior images of a light and then moves the lens slightly, movements can be made which cause both images to move equally or one to move and the other be left stationary. This happens when the movement corresponds to a curved surface, the centre of which is at the focus of one of the reflecting faces, the image belonging to which face appears not to move, or very slightly. Since then trustworthy evidence cannot be obtained from reflection images. Professor Hess has always laid more value on opacities of the lens. Thus he used cases of anterior polar cataract or complete cataract to show the trembling of the lens at the height of accommodation. He now mentions a case where several

pigmented spots on the anterior capsule of the lens are the only abnormality and are the remains of the pupillary membrane. These spots share in the trembling. For the descent of the lens he employed a case where almost the whole iris had been removed by repeated iridectomies. For these cases it was impossible to conclude that only the lens mass moved, and not the anterior capsule. A further proof, in the descent of the epithelium under the anterior capsule of the lens, Professor Hess has adduced, although it was almost unnecessary. On examining the reflex from the anterior surface by a magnification of 30 to 60 diameters there is seen a slight stippling of the otherwise uniform white spot. He employed a Czapski's microscope. For various reasons, chief of which its absence from the posterior capsule, he believes it is due to the epithelium. During accommodation this stippling sank. Finally, as regards Tscherning's new assumption that the central parts of the vitreous become fluid at the height of accommodation, it is not necessary to discuss the presence of Cloquet's canal, which Cirincione has recently denied in the adult. Even if it should be present the insufficiency of Tscherning's new hypothesis follows so easily from the above and Professor Hess' earlier experiments from the physiological and physical standpoint, that it requires no further discussion.

W. B. Inglis Pollock.

[1] "Il meccanismo dell'accommodazione," *La Clinica Oculistica*, November, 1903.

[2] *Ophthalmic Review*, Vol. xxiii., p. 102.

---

Sophus Ruge (Greifswald). **Investigation of the Pathological Anatomy of Sympathetic Ophthalmia and Its Relations to Other Traumatic and Non-Traumatic Uveitis.** *Von Graefe's Archiv für Ophthalmologie*, lvii, 3, 1904.

This investigation was undertaken by the author in order to find out whether the structural changes in sympathetic uveitis are different from those in traumatic uveitis not associated with sympathetic inflammation, and in chronic uveitis due to constitutional causes.

The first series of cases examined consisted of 26 exciting eyes which had set up sympathetic ophthalmia and two sympathising eyes. The histological changes were carefully examined in all cases, and in a few the absence of tubercle bacilli was demonstrated by the results of special staining processes and the inoculation of rabbits. In all these cases there was a more or less severe inflammation of the whole uvea. In eyes enucleated early there were signs of recent though chronic inflammation, indicated by round cell infiltration and the formation of recent granulation tissue on the part of the iris and ciliary body. This infiltration with uninucleated round cells was sometimes diffuse and at other times the cells were arranged in circumscribed roundish areas which often showed a blood-vessel in the centre. This sign of chronic uveitis was present even in cases of suppurative panophthalmitis and was regarded by the author as the only cause of sympathetic inflammation.

The iris and ciliary body were infiltrated with round cells and were covered by a richly cellular exudation which was separated from the infiltration in the stroma by a fringe of degenerated pigment cells. In the later stages this granulation tissue was transformed into fine connective tissue; but even in the most advanced cases there were some round cells visible—a sign that the inflammation was still active. The extent to which these parts of the uvea were affected varied greatly, and the constituent structures of one body were variously affected, *e.g.*, the folds of the ciliary body were infiltrated whilst the muscle was free. The choroid was similarly infiltrated with round cells which were generally confined to the outer two layers, though in some degrees of inflammations the capillary layer was attacked and even destroyed—this latter generally only in cases of acute purulent inflammation. The anterior and posterior parts of the choroid were sometimes affected, whilst the equator was left free. The choroid showed no exudation on its surface like the iris and the ciliary body. The blood-vessels of the iris were often thickened owing to a deposit of round cells in the walls or by connective tissue formation. Sometimes they showed proliferation of the endothelium and diminution of their lumen. In more advanced cases—possibly owing to defective nutrition—the nuclei were diminished and their outlines were ill-defined, so that the picture of hyaline degeneration was presented. The author

does not regard this as characteristic of sympathetic inflammation, as a similar appearance has been noted in other forms of iritis. He, however, thinks it may have something to do with giant cell formation, though no definite connection between the two has been established. Occasionally the ciliary body and choroid were detached by cicatrisation of the cyclitic exudation.

Those parts of the globe physiologically associated with the uvea were involved in the inflammation. The episclera was thickened and infiltrated with diffuse or circumscribed collections of round cells. The optic nerve and its coverings were also often involved, though not severely. When the round cell infiltration was marked, it occurred in the region of the lamina cribrosa and diminished towards the brain. Some cases showed infiltration as far as the chiasma, but chiasmal infiltration was regarded by the author as being probably due to other disease of the brain and membranes. The infiltration into the nerve and sheaths was ascribed by the author to toxins produced in the posterior part of the globe and which were more concentrated near the lamina cribrosa.

The vitreous, when present, showed fine fibrillation and was free from cells. The retina was generally detached and secondarily atrophied. The detachment was generally due to shrinking of the vitreous. The anterior part of the retina was frequently involved in the granulation tissue derived from the iris and ciliary body. Inflammation of the retina was rare, and only occurred as a perivasculitis which was most marked near the optic disc. The papilla was at times swollen and showed severe infiltration of its connective tissue. The cornea—apart from changes due to injury and shrinking—showed little change beyond some increase of nuclei. The sclera often showed perivascular lymphangitis at the points of entrance of the anterior and posterior ciliary vessels. The sclera was at times nearly completely perforated by granulation tissue. The ciliary nerves were generally normal, though some cases showed some perineuritis, but no neuritis proper. This pathological picture of chronic inflammation of the uvea was the same in the sympathising as in the exciting eye.

The author gives special attention to 14 of these eyes in which giant cells were found. The giant cells were always associated with epithelioid cells. They were found in all parts of the eye, but were more common in the iris ciliary body and

choroid. They were also observed in newly-formed granulation tissue whether the latter was in the uvea or had extended beyond that region. Their position in the granulation tissue was variable, being sometimes in the centre and at other times at the periphery. The giant cells were sometimes solitary and sometimes very numerous—as many as 100 being visible on one slide. The characteristic order seen in tuberculosis was not seen in any of them. Epithelioid cells were often seen without giant cells. The size and shape of the giant cells were very variable, as was also the number of nuclei; of these there might be from 4 or 5 up to 15 or even more. Cells resembling the type of Langhans were seen in nearly every case, but they were not predominant. Giant cells were found in exciting and sympathising eyes, and even in a case of panophthalmitis which had caused sympathetic ophthalmia. In reference to the duration of inflammation required to produce giant cells, the earliest observed was five weeks after injury, but they were very numerous in cases examined two or three months after injury, and they were also found in a case of three years' duration. They occur as frequently in children as in adults. There was apparently no difference in the course and prognosis of sympathetic ophthalmia due to exciting uveitis with giant cells and those set up by an uveitis without them; in some of the cases the eyes were lost whilst in others good vision was retained.

As the result of examinations of 34 eyes removed for injury or ulcer with perforation, the author distinguishes two clinical groups:—

1. Associated with acute inflammation and in which enucleation was necessary in a few weeks.

2. Associated with chronic inflammation remaining the same for weeks, then getting less or subsiding, but recurring after months or years.

These correspond to the pathological groups:—

1. Purulent inflammation.

2. Fibrinoplastic inflammation.

In (2) all parts of the globe were not affected to the same degree. Inflammation starting from a corneal wound was generally localised in the anterior part, being limited by the diaphragm consisting of the lens, iris, ciliary body, and

zonula,—and possibly because the lymph channels are directed forwards and away from the deeper structures of the globe. The posterior part of the globe generally remained free from inflammation, though slight retinal perivasculitis was observed by Peters. The prognosis as regards retention of the globe is good in these, and for practical purposes it should be remembered that excision should be delayed as long as possible, as in most cases the inflammation subsides and excision becomes unnecessary. When the diaphragm mentioned has been destroyed, or the posterior part of the globe has been directly infected, the inflammation at once becomes general and a panophthalmitis or a vitreous abscess is the result.

The histological changes in the *purulent cases* were characterised by a rich infiltration of the tissues by multinucleated cells, which were very closely packed together in the vitreous. The choroid was diseased, generally in the outer layers. The choriocapillaris was sometimes affected, but to a less extent than the intermediate and large blood-vessel layers. When the capillary layer was seriously involved, it had become swollen and homogeneous in appearance owing to the disappearance of the lumen of the vessels and the loss of staining power of the cells and nuclei. The retina in the neighbourhood of an abscess was thickened and infiltrated with round cells. The iris and ciliary body were infiltrated by pus corpuscles and showed a tendency to exudation in and on their tissue and loss of definition of the pigmentary and other cells. The anterior chamber when preserved often contained fibrin containing red blood corpuscles and leucocytes. The cornea and sclera showed no change beyond slight diffuse proliferation of nuclei. Occasionally the cornea was spontaneously perforated owing to purulent disintegration starting on the inner surface. The episclera was covered and infiltrated with round and purulent cells. The optic nerve was only rarely infiltrated with pus cells and generally only showed proliferation of nuclei. The ciliary nerves and vessels were generally normal. Even these cases occasionally contained giant cells, but whether as the result of foreign bodies or of some other and indefinite origin it was difficult to decide. Some had developed within eight days.

The changes observed in the *chronic fibrinoplastic inflammation* were loosening and infiltration with round cells of the episcleral tissue. The cornea was normal apart from

deposits of uninucleated round cells on its posterior surface. The anterior chamber was generally partly filled with fibrino-cellular deposit adherent to the anterior surface of the iris, and which generally filled the pupil and coloboma (when present). In older cases this had become transformed into dense connective tissue. The iris showed accumulation of round cells under the pigment epithelium or under the endothelium on the anterior surface. The vessel walls were often thickened and homogeneous. The ciliary body was similarly infiltrated by diffuse or circumscribed collections of round cells, and was covered by richly cellular exudation which on becoming organised had in many cases detached the ciliary body and choroid. The choroid was generally but slightly affected by diffuse and circumscribed round cell infiltrations which were confined to the outer layers, whilst the chorio-capillaris was not affected. The retina was not involved beyond a moderate perivasculitis near the disc, which was sometimes covered with an exudation rich in nuclei. The optic nerve showed some proliferation of nuclei of the supporting tissue; it was very rarely infiltrated with round cells. The intervaginal space was normal except for some proliferation of the endothelium. The ciliary vessels and nerves were generally normal, but in exceptional cases they were surrounded by round cell infiltration. The vitreous was finely fibrillar in the centre and coarsely so at the periphery. Sometimes there was slight infiltration with round cells in the region of the ciliary body.

Whether this chronic uveitis has a separate origin from the panophthalmitis is doubtful. Schirmer is of opinion that the panophthalmitis is caused by the cocci of acute suppuration, whilst the chronic uveitis (the sole cause of sympathetic ophthalmia) is due to the hypothetical cause of sympathetic ophthalmia. He thus assumes a mixed infection. But it is known that pus organisms may cause chronic non-purulent inflammation when their virulence is diminished, and this may be the explanation of the production of the chronic uveitis in these cases.

The cases of *spontaneous* (non-traumatic) *uveitis* which were examined were characterised by accumulations of round or giant cells on the posterior surface of the cornea. These cells were produced by the iris and ciliary body equally; Descemet's membrane was only passively concerned. The iris and ciliary body were infiltrated with round cells, and to a less extent the

choroid was generally infiltrated in the same way. The retina and the optic nerve were generally normal.

*Tuberculosis* of the iris, ciliary body, and choroid showed several marked appearances. The round cell infiltration was arranged in nodules which had no blood-vessels. The small peripheral cells were very closely packed. The epithelioid cells had considerably larger and paler nuclei. The giant cells were of the Langhans type and contained amorphous matter. In a few atypical cases giant cells and caseation were not to be found, but epihelioid cells were never absent. In doubtful cases the nature of the nodule could only be decided by inoculations and special staining for tubercle bacilli. Two forms of tuberculosis are recognised in the eye, viz.: (1) Diffuse and (2) circumscribed. The first finally affects all the tissues of the eye and leads to caseation. In the second form solitary tubercle may appear in the iris, ciliary body or choroid. The process may remain restricted to its original site and become cured, or it may spread by contiguity and eventually set up a general infection. Spontaneous perforation of the globe, generally at the corneo-scleral junction, is liable to result.

Miliary tubercle seems to be localised exclusively in the choroid in man, and does not show the development of large tubercle nodules, probably because of the early death of the patient.

*Syphilitic inflammation* was sometimes limited to the anterior or posterior part of the globe. In most cases both parts were affected. Apart from gummatous changes the appearances presented consisted of partly diffuse and partly nodular collections of round and epithelioid cells, and the formation of young and old connective tissue. Syphilitic iritis showed peri- and end-arteritis and nodules consisting of radially and centrally placed larger cells surrounded by a ring of round cells. These nodules were formed around the changed vessels and were considered fairly characteristic of syphilis, but not sufficiently so, without the history, clinical and other pathological observations, to be conclusive. Similar changes were observed in the choroid vessels, and these were inclined to spread into neighbouring tissues, and especially to the retina. Some of these areas resembled psammomata.

In reviewing the pathological changes which are observed after perforation of the eye, the author recognises three types

of inflammation, viz., purulent, fibrinoplastic and serous. There is no pathological record of a case of serous inflammation.

In the purulent form the vitreous and the uvea are frequently pretty equally affected. The vitreous is partly or completely permeated by pus corpuscles and the uvea and the exudation from it are impregnated by pus corpuscles. In panophthalmitis the tissue undergoes necrosis. In the fibrinoplastic form the uvea is permeated more or less by uninucleated round cells and the iris and ciliary body produce a fibrinous exudation containing uni-nucleated round cells which tend to become organised into fibrous tissue. There is never any necrosis of the tissue.

The subacute inflammation partakes of the character of these two types and forms a connecting link between them. The chronic changes may be due to the attenuated effects of the two organisms or may be independent of them. The type of inflammation which sets up sympathetic ophthalmia is always fibrinoplastic. Even in those cases in which sympathetic ophthalmia has followed an apparently purulent inflammation, it will be found that a fibrinoplastic uveitis was the real cause. This fibrinoplastic uveitis cannot, however, be histologically distinguished from traumatic fibrinoplastic inflammation which has not set up sympathetic ophthalmia. Taken relatively, the inflammatory appearances in simple traumatic uveitis are generally less extensive than in exciting eyes. Further, the choroid is often much less affected than the iris and ciliary body of the same eye; and the choroid is less extensively affected than that of an exciting eye. The exudation in exciting eyes is greater in amount, especially over the ciliary processes. It is rare to find round cell infiltration in the optic nerve in non-exciting uveitis. Finally, there is a distinct difference in the number of giant cells in the two cases. Giant cells were found in half the cases of sympathetic ophthalmia and only in one-fifth of the non-exciting eyes. The giant cells are much less numerous—generally solitarily—in non-exciting eyes, and they were never found in the choroid by the author. In sympathetic uveitis they were found often in groups, though sometimes solitarily, in the uveal tissue and in the newly-formed iridocyclitic organised tissue. It is possible that giant cells should be regarded as belonging to a typical picture of sympathetic ophthalmia, but definite proof of this is

wanting. That these giant cells are not due to tubercle bacilli is shown by the following facts:—

1. The nodules in exciting eyes are not all non-vascular, but often have a blood-vessel in the centre.

2. The nodules often consist of round cells only and never, even in the most marked cases, show any caseous degeneration.

3. The typical picture of a tubercle nodule is often not found—the cells being arranged irregularly.

4. Experimental inoculations give negative results.

5. Attempts to demonstrate the presence of tubercle bacilli have been unsuccessful.

Giant cells have been found in:—

1. Sympathising and exciting eyes.

2. Subacute traumatic uveitis.

3. Chronic fibrinoplastic traumatic uveitis (not followed by sympathetic ophthalmia).

4. Spontaneous iridocyclitis of unknown ætiology.

5. Tuberculosis.

6. Syphilis.

7. Cases of foreign bodies in the eye—*e.g.*, hairs of plants and caterpillars, stones, cysticercus, bits of lens or capsule cholesterin crystils, and even pus corpuscles.

J. Jameson Evans.

---

C. Pino (Dutch Navy). **Erythropsia and Waning Coloured After-images.** *Von Graefe's Archiv für Ophthalmologie*, lviii., 1.

Several explanations have been offered for the origin of erythropsia. Fuchs, who made a close study of this phenomenon, both induced artificially and in the clinical form seen after extraction of cataract, believed it arose from the entoptic perception of the visual purple as it was being regenerated; but this view has been objected to on several grounds. Rivers has suggested that red vision is due to the entoptic vision of the blood within the eyeball. Pino will not accept this, but offers another explanation: he believes that it is the result of bleaching of the visual purple; in other words, that when white light has bleached the visual purple it is really perceived as yellowish-green light, and erythropsia is the complementary after-image of this green light.

White light, he says, is normally changed into a yellow-green colour in its passage through the meshwork of retinal vessels to the sentient layer, but it is normally neutralised by the visual purple, and therefore not perceived; when, however, the latter is removed by bleaching, the yellow-green light is perceived as such, and can then give rise to its own coloured after-image. Rivers, on the other hand, holds that the colour which blood in the retinal vessels might give to light is red.

Pino also maintains that the visual purple itself may be perceived: when the eye is in a condition of dark adaptation and part of the retina is exposed to a bright white light, the visual purple is in excess of what is required for the neutralisation of light that is turned into yellow-green, and this excess is momentarily perceived by the red tint of the field.

Two other phenomena are considered by Pino to be closely allied to erythropsia, and like it due to the bleaching of the visual purple: these are the so-called "coloured waning of the after-images," and the coloured changes described by Fechner. This coloured waning has been referred by others to differences in persistence or to the colour adaptation of the retina. He points out that under the long-continued action of very bright light this phenomenon finally merges into pure erythropsia.

The changes seen on fixing a well-illuminated white surface for a long time (Fechner's experiment), according to Pino, are due to the slow bleaching of the visual purple, the different colours being positive and negative after-images.

Pino thought at first that through his experiments on this subject he had discovered the true function of the visual purple, viz., the neutralisation of the yellow-green rays produced by the retinal vessels; but an examination into the relation between these vessels and the visual purple in the lower animals seems so far to offer difficulties to the general acceptation of this hypothesis.

——— THOMAS SNOWBALL.

A. SCHIELE (Kursk). **Night Blindness and Xerosis.** *Wochenschrift für Therapie und Hygiene des Auges*, 1904, 32.

THE author points out the prevalence of night blindness in Kursk, and also the fact that the greater number of patients appear about the end of the Lenten fast. He quotes the statistics published by Protapopow in 1902, which embrace a period of six years (1893—1898), and a case incidence of

36,000. From these it appears that night blindness is endemic in Kursk, and in the spring becomes almost an epidemic. The years 1893, 1896, and 1898 were immediately preceded by years of low incidence. There appears to be no connection between the case incidence of night blindness and that of malaria, typhoid, and other diseases due to disturbance of nutrition. Fifty per cent. of the cases occurred in patients between the ages of 25 and 60, and 20 per cent. between the ages of 15 and 25. Males were more often affected than females in the proportion of 64 to 35. When a table of case incidence is arranged according to the months, it is at once seen that night blindness reaches its greatest intensity in February, March, and April—the period in which the longest fasts occur; the numbers rapidly decrease thereafter, but again rise in the month of June, the time of another fast. The case incidence varies according to this official report between 4·1 and 28·3 per 1,000 of all other diseases.

Xerosis of the conjunctiva is apparently a common accompaniment of night blindness; exceptionally the xerosis organisms also invade the cornea. Schiele has observed that night blindness commences in many cases with some irritation of the eyes and increased lachrymation. Later the lachrymation ceases and a dryness of the conjunctiva results, and white glistening placques are seen on either side of the cornea. Severe cases of xerosis accompanying night blindness are seldom seen in adults.

At the sixth Russian Medical Congress in 1896, Ewmeniew referred to the influence of famine during 1891–1892 on eye diseases among the people of the Ostrogar province, and reported on the frequency of night blindness accompanied by a severe form of keratitis with xerosis of the conjunctiva.

The author then describes some cases of his own where night blindness was associated with xerosis of the conjunctiva and cornea. In one patient who was much emaciated xerotic patches were seen on the mucous membrane of the mouth and on the vocal cords. The bulbar conjunctiva were dry and without folds. Xerotic plaques, triangular in shape with the base towards the limbus and of a cloudy gray colour, occupied both corneal. Patient saw everything through a fog, and at night could not see at all. Complete recovery resulted in two weeks after putting the patient on a nourishing diet and cod liver oil.

Schiele then discusses the pathology of the condition. He considers that insufficient nutrition with the exclusion of fat from the food exercises such a pernicious influence on the function of the liver that an alteration of the blood must ensue which on its part by its influence on the tissues causes a disturbance in the function of the retina (night blindness) and an increase in the xerosis bacilli with possible deleterious effects on the cornea. He is firmly convinced that for successful treatment of these conditions cod liver oil is essential. As iodine, however, is present in small quantities in cod liver oil (about ·04 per cent.) he experimented by injecting subcutaneously solutions of iodide of sodium without result. In the local treatment of the xerotic patches, however, the application of a solution of 5 per cent. solution of iodide of potassium followed immediately by a 5 per cent. solution of iodine was found to be beneficial. Three varieties of corneal lesions, due apparently to xerosis bacilli, are described: (1) a superficial triangular patch resembling the disease when it occurs on the conjunctiva; (2) circumscribed small foci occurring deep in the substance of the cornea; and (3) a corneal ulcer with hypopyon. Necrotic foci in the deeper portions of the conjunctiva can also occur, and this Leber and Wazenmann have confirmed in a case of xerosis. Schimmelpfennig in an analogous case has described not only the occurrence of necrosis of the cornea but also of necrotic patches in the conjunctiva. The author points out the probability that streptococci as well as the xerosis bacilli may have been present in these more severe cases. The results of an operation are then described where an optical iridectomy was performed on a patient suffering from trachoma which was followed by kerato-irido-cyclitis with slight hypopyon.

Dr. Schiele's article is interesting, especially with regard to night blindness, but is unconvincing as regards the xerosis conditions, as apparently no bacteriological examination was made in any of the cases.

E. W. Brewerton.

---

De Schweinitz, Wilder, Ball, and Weeks. **The Relation of the Cervical Sympathetic to the Eye.** *American Medical Association.*

Under the above title one finds a collection of papers, read

before the Section on Ophthalmology of the American Medical Association at New Orleans in May, 1903, constituting an important contribution to a subject of extreme interest to all ophthalmic surgeons. Dr. de Schweinitz gives a full résumé of the physiology of the sympathetic in relation to the eye, and his conclusions—summed up in 20 paragraphs—appear to be well-founded. Dr. James Moores Ball's paper is on the influence of resection of the cervical sympathetic in optic nerve atrophy, hydrophthalmos and exophthalmic goître. Dr. J. E. Weeks writes on the pathology of the cervical sympathetic. The paper, however, in which ophthalmologists will be most keenly interested is that by Dr. W. H. Wilder on the influence of resection of the cervical sympathetic ganglia in glaucoma.

A full history of 68 cases is given. Of these 26 were "improved," 25 "unimproved," 7 "stationary," and 10 "temporarily." In addition to these 68 cases, a résumé of 94 cases of Rohmer's and Bichet's is given, by which out of 114 operations, 79 were followed by "improvement," the results of 29 cases were "negative"; 6 were "worse."

There cannot be any doubt as to the great value of this book as affording one a capital exposition of the physiology, etc., of the action of the sympathetic nerve on the eye; as regards the value of the actual operative resection of the ganglia in cases of glaucoma, Dr. William H. Wilder exactly expresses the views of the reviewer when he says: "I feel that positive conclusions are not yet to be reached, and will not be till more carefully selected cases can be studied for longer periods of time."

---

JULER (H.). **Ophthalmic Science and Practice.** Third Edition. London: Smith, Elder and Co.

IT is pleasant to note that while the market is being flooded with new text-books on ophthalmology our older friends reappear in fresh editions, and are not altogether jostled out of the way. There are not many of the manuals which deserve a reputation better than that of Mr. Juler; it treats of the subject in hand in a very plain, straightforward and simple manner, concise, not too wordy, and easily comprehended. One point of value in the book, which is often absent from others, is the presence of little historical sketches of the development of our knowledge of a disease, or of the remedies proposed: these

impart to the rest of the subject matter an additional zest. The new edition is, however, we fear, open to the criticism that some of the information is not quite up-to-date. We may take as examples of this that in the treatment of dendritic ulcer absolute alcohol finds no place, that poisoning by methylic alcohol (wood spirit) is not mentioned, and to Krönlein's operation there is no reference. It is not in every subject that there is this lack of recent information, it is only in some. Many are well brought up to date.

In regard to concomitant squint the information is in one point, if not exactly misleading, so imperfectly expressed as to be very capable of giving rise to a false impression. The author appears to divide his cases into "alternating" and "fixed." Now it is certain on the one hand that many squints never have passed through the alternating stage, but are always one-sided, and equally certain that they may never become fixed. If there were no occasional or periodic cases—a state of affairs not distinctly spoken of in Juler's book—we should have but few cures to record. We demur to statement (p. 578) that "all infants are congenitally amblyopic." In a sense that is true, but it would be equally true and equally misleading to say that all infants were congenitally ataxic, and had congenital paresis of the extensor muscles.

We consider the book to be on the whole a very reliable sensible guide; it cannot claim to be very "deep," scientific (although its title implies this), or exhaustive (*e.g.*, on the subject of diplopia, which is skimmed over very lightly), but it is safe, handy, and useful.

---

J. Herbert Fisher. **Ophthalmological Anatomy, with Some Illustrative Cases.** London: Hodder and Stoughton, 1904.

The complexity of the anatomy of the visual apparatus is no doubt often a stumbling-block in the way of an exact diagnosis. A mere enumeration of the chief subjects treated in this volume, viz., the visual pathways and centres, the motor, sensory and sympathetic nerve supply of the eye and its neighbourhood, the ocular movements and muscles, the eyelids and the lacrimal apparatus, the vascular supply of the eyeball with the intra-cranial venous sinuses, the orbital walls and surrounding air-

cells—indicates how desirable is a trustworthy and readily-accessible guide to its intricacies. For the production of such a guide Mr. Fisher was well qualified as an ophthalmic surgeon, as a former teacher of anatomy, and, not least, as the possessor of a clear and readable literary style.

It has been said that the difficulty in learning anatomy is that there are no pegs to hang the facts on, and this lack Mr. Fisher has endeavoured to supply by giving in the second half of the volume a number of interesting cases from his note-books illustrating the anatomical facts and their bearing on diagnosis. Indeed, what the practitioner will appreciate about the book is that it is obviously written by one who looks at the facts as a surgeon as well as an anatomist, and he will gather many practical hints from its pages. Among these we may note the suggestion for treating septic thrombosis of the cavernous sinus directly through the eviscerated orbit, and that of tying the internal instead of the common carotid for arterio-venous aneurism. Well worth attention, too, for their bearing on the treatment of squint are his views on the functions of the superior and inferior recti muscles and the oblique as accessory adductors and abductors; while his remarks on the capsule of Tenon are thoroughly practical and must be admitted to dispose entirely of the theory of its function as a ball and socket joint, though we may confess to a slight pang of regret at parting with so old a friend.

One or two minor points have suggested themselves for criticism. In describing the third nerve nucleus, after mentioning the cell-groups for the ciliary muscle and for the sphincter pupillæ the author continues:—"Further differentiation of the nucleus into parts concerned with individual extra-ocular muscles cannot be said to be proved," and no doubt the statement is accurate, but we think the results which were worked out by Hensen and Voelcker, in the dog might have been given, as at least suggestive pending more complete clinical evidence in man. And after a clear description of the symptoms produced by paralysis of the recti muscles and the method of examining for them, it seems a little unkind to leave us to struggle with the difficulties of the oblique muscles and tilted images with the remark that "the exposition would only render the subject more complicated and the deductions are not always reliable." But it is only because of the high standard which the book attains that we are inclined to suggest small

improvements; and finally we should like to thank Mr. Fisher for the care he has bestowed on the choice of type and paper, and for the addition of an excellent index.

---

MARTINDALE and WESTCOTT. **Extra Pharmacopœia.** Eleventh edition. London: H. K. Lewis.

THIS most valuable work has now reached its eleventh edition. The new issue, though containing 150 more leaves than the former one of three years ago, is lighter and less bulky, without any sacrifice having been made of clearness of type. An important new feature is a section on radiology, including Röntgen rays, high frequency current, Finsen lamp, etc. The mineral waters are also grouped together for ready reference. All the information is, as a matter of course,—for the standard has ever since the first edition been the very highest,—thoroughly up-to-date and absolutely precise.

---

## CORRECTION.

IN our issue of March last a review of Hansell and Sweet's Text-book appeared in which, through error, a firm other than that of Messrs. Rebman was credited with being the publishers. We take this opportunity of correcting that mistake, which has just been brought to our notice.—ED.

---

## OPHTHALMOLOGICAL SOCIETY OF THE UNITED KINGDOM.

The President, Mr. JOHN TWEEDY, in the Chair.

*Meeting held June 2nd, 1904.*

### CARD SPECIMENS AND CASES.

*Dermo-lipoma of the Conjunctiva.*—Dr. Louis Werner.

The patient, a girl aged 16, had suffered from irritation of the left eye, caused by a few hairs which had made their appearance at the outer canthus of the eye, some six months previously, and which, on being removed, grew again. Subsequent examination showed them growing from a small lump underneath the eyelids. The conjunctiva over the growth was smooth and freely movable except at the spot

where the hairs emerged. On examination, after removal, the growth was found to consist of fat chiefly, which was continuous with the orbital fat, not bounded by a membrane of any sort. A few sebaceous glands and hair follicles with one small nerve bundle completed the mass. It was pointed out that the dermo-lipomata can be distinguished from the true lipoma by the fact that in the former the conjunctiva is usually adherent to the tumour, whereas in the latter it is freely moveable over it. The appearance of large hairs which grew about the time of puberty is of interest in face of the statement of Lagrange "that hairs visible to the naked eye are rarely to be seen in dermo-lipomata."

*Epibulbar Melanotic Sarcoma: enucleation; no recurrence for six years.*—Dr. Louis Werner.

The patient, a woman aged 55, belonging to the agricultural class, had noticed a small brown spot on the white part of the right eye at the outer side of the cornea, which had increased in size in 12 months and had been removed. It however had soon recurred and developed into a large tumour which protruded from between the lids, and was firmly attached to the sclero-corneal margin which it overlapped on to the cornea. It was solid to the touch, showed a slight tendency to bleed when so touched, but was not painful. It measured 18mm. vertically, by 12mm. horizontally, and extended from 2mm. above the cornea to 6mm. below it, projecting some 6mm. above the level of the sclerotic. The eyeball with the tumour *in situ* was enucleated, and this year—six years after the enucleation had been performed—the patient is still alive and in the best of health. Microscopically the tumour was found to be composed of large flat endothelioid cells closely packed together, mostly round or polygonal in shape. No intercellular stroma was seen except towards the surface, where columns and alveoli were seen bounded by blood-vessels, also narrow bands of fibrous tissue, or spindle-shaped cells, many of which were pigmented. A large amount of pigment was present all over the growth. In the very centre of the growth a patch of hyaline degeneration was found, but no necrotic areas. Reviewing the various opinions as to what operative treatment should be carried out, the writer considered that in all cases where any recurrence had taken place after abscission of the growth in its early stages, enucleation was the safest course, and also that in any case where surrounding part such as the lids or lymphatic glands were involved, immediate enucleation was the wisest course to adopt.

*Flat Sarcoma of the Choroid.*—Mr. E. Erskine Henderson.

The patient, a man 25 years of age, some five years previously had

had several attacks of inflammation in his left eye, after one of which the sight suddenly failed without any previous injury, and he had been told that he had a detachment of the retina. During some of the attacks the eye had been proptosed. On admission to hospital the eye was acutely inflamed and very tense, and was enucleated; a week later the orbit was exenterated. An examination of the bisected globe showed a flat growth moderately pigmented, surrounding the optic nerve entrance, with one small nodule, also in the region of the posterior ciliary vessels (extraocular); part of the sclerotic was infiltrated. Microscopically the growth consisted of round and spindle cells with a few larger cells, endothelial in type, and much necrotic tissue, but no attempt at any alveolar structure.

*Usual form of Anterior Staphyloma.*—Mr. E. Erskine Henderson.

The patient was an infant 15 months old, and the staphyloma had resulted from Ophthalmia Neonatorum. After removal by transfixion it was found to be 6mm. thick, consisting of fibrous tissue with vessels of new formation, and to be lined by greatly thinned iris tissue. The surface of it was horny, under which lay regular stratified epithelium.

*Pseudo-glioma.*—Mr. E. Erskine Henderson.

The patient, aged 28, had received a punctured wound of the right eye, with a prolapse of the iris which had been removed, but on the eye subsequently developing symptoms of septic infection it was exised a fortnight after the injury. On being bisected a localized exudation into the vitreous most marked in the neighbourhood of the wound of the iris was seen; this also extended back to the optic disc.

*A case of Ophthalmoplegia Externa.*—Mr. G. W. Roll.

The patient, a lad aged 16, awoke one morning with diplopia and drooping of both upper eyelids. Seven days after this he noticed some weakness of the limbs. On admission to hospital there was double ptosis, more marked on the left side than the right, together with ophthalmoplegia externa. The only muscular movements of the eyes remaining were (much diminished) upward and downward movement, and the reaction of the pupils to light. The vision of each eye was $^{6}/_{6}$ and Jg. 1. There appeared to be some diminution of the power of the hands to grasp. The ptosis later on diminished in the left side and increased on the right. Two months later the movements returned, gradually at first, until all had re-appeared. There had been some difficulty in mastication, and some weakness of the extremities.

*Tumour of the Ciliary Body.*—Mr. E. W. Brewerton.

The patient, a woman aged 56, had noticed something growing down from above and obscuring the sight of the left eye for some four months, with occasional flashes of light, but no pain. Examination of the right eye showed the presence of a small tumour about the size of a pea situated immediately behind the lens and above. Its surface appeared nodular and covered with brownish pigment. It was growing from the ciliary body and extended backwards beyond the ora serrata, with a detachment of the retina behind and below. Some vitreous opacities were present, but otherwise the fundus, as far as could be seen, was normal. Treatment with potassium iodide and sub-conjunctival injections of cyanide of mercury did not appear to affect the growth.

*Persistent deposit on posterior surface of the Cornea, strongly resembling a foreign body on the cornea.*—Mr. Rayner S. Batten.

This was a small, darkly-pigmented spot, apparently on the back of the cornea or deeply in its substance, with no symptoms of irritation or of keratitis punctata.

PAPERS.

*Optic Atrophy in a youth (file-cutter) from lead.*—Mr. Simeon Snell.

The patient, a young man aged 16, attended the Sheffield Royal Infirmary on account of failure of sight in both eyes. The sight had commenced to fail a year before, but he had been able to continue his work—that of a file-cutter up till six months ago, when the vision became so bad that he was compelled to give up his employment; during the last three months the sight had steadily and rapidly become much worse. His discs were white and atrophic, but showed no signs of a preceding neuritis. In addition to his work as a file-cutter it was his duty to break up and melt the old lead beds upon which the files are placed for cutting, and he always partook of his dinner in the shop, working from 8 a.m. till 6 p.m. At the time of his first attendance there was a blue line over the left upper incisor tooth, and he had suffered from abdominal pains which doubled him up, but there was no wrist drop or obstinate constipation. The writer pointed out that primary optic atrophy had been recognised by other observers—as mentioned by De Schweinitz in "Toxic Amblyopias"—as being brought on by chronic lead poisoning, and he himself had had one such case some years ago. The occupation of file-cutting has long been recognised as one very prone to occasion lead-poisoning, since the files rest on a lead bed which gives off minute particles of lead dust as the file is being chiselled to make the lines on it; thus the atmosphere of the workshop becomes charged with lead, which is inhaled.

*A case of double Optic Atrophy, after Uterine Hæmorrhage.*—Mr. Simeon Snell.

The patient, aged 28, after her confinement at full term, developed puerperal mania within 9 days, which lasted some four months, then gradually recovered. The labour had been a short one with rupture of the perinæum, but an hour after there had been very considerable hæmorrhage with hardly perceptible pulse, due to retained placenta. After this no further hæmorrhage had taken place. It had been suspected for some time during the mania that the vision was very defective, but this had been attributed to the mania, which at times had been very acute. The nurse had for three months noticed the widely dilated pupils. The urine was and had been free from albumen. The writer considered this optic atrophy to be due to the hæmorrhage, and the exhaustion consequent upon the latter to be a feature in occasioning the mania. Another similar case was mentioned which had occurred under the writer's care, and a resumé of the recorded cases was given. Amongst the latter, in five cases, there had been traces of neuritis and in one of papillary strangulation the vessels were usually filiform in size, in three cases only were there traces of retinal hæmorrhages.

*Glioma in each eye: enucleation: recovery.*—Mr. Simeon Snell.

The patient, a little girl, aged 1 year and 10 months, had been found to have glioma of the retina in the left eye, with subsequent enucleation of the eye, and no recurrence of the growth had taken place in this orbit. Two years later, however, the same child was found to have glioma in the other eye and enucleation was performed. In each case the tumour partly filled the vitreous cavity, but was entirely confined to the globe. No return of the glioma had occurred. In the second eye the glioma was found microscopically to extend to the lamina cribrosa but not through it. In this case twenty months elapsed between enucleation of the first eye and the disease being noticed in the other eye, with a period of two years between the removal of the two eyes. Mr. Treacher Collins regarded three years as the period within which recurrence of glioma—if not cured by removal—will take place. Since the enucleation of the second eye no recurrence of the growth had taken place.

*Glioma: two cases in one family, one in each eye.*—Mr. Simeon Snell.

The first case was that of a baby aged 4½ months, who suffered from glioma of the right eye, which was at once enucleated, and the tumour was found partly to fill the vitreous chamber, growing inwards from the retina. This had been noticed only six weeks. No recurrence had

taken place. A brother of this child had previously suffered from glioma in both eyes, of which the history was as follows. When he was about a year old the parents, as they stated, "could see the inside of the eye," and on the child being taken to an ophthalmic surgeon they were told that both the child's eyes were affected and ought to be removed, and unless this were done the child would die. The parents would not consent, and a year later the child was again taken to the same surgeon, who then advised that the disease was too far advanced for anything to be done. Each eye became much worse and protruded from the orbit, then two large masses of fungus hæmatodes protruded, extending down the face and reaching the month, so that the child could only get a cup to its mouth by throwing its head far back. Each mass bled freely. The child died a few months later. Hence, out of three children the first died from glioma of both eyes, the second was alive and healthy, and the third has had one eye enucleated for glioma. A resumé of the recorded cases—comparatively few in number—of glioma occurring in more than one member of the same family was given, which, as the writer pointed out, rather tends to disprove the assertion that glioma never occurs in two members of the same family.

*Microphthalmos.*—Mr. Stephen Mayon.

The histological description of three eyes formed the substance of this paper, all illustrating arrested or imperfect development of the eyeballs at three different stages of fœtal life.

The first showed defective formation and involution of the primary optic vesicle; the second, the defective closure of the posterior end of the cleft in the primary optic vesicle; the third, atypical development of the vitreous which has gone on to the formation of adipose tissue.

The first two specimens were derived from a child born at the seventh month, who had lived 24 hours, and who also presented numerous other deformities, chiefly of the hands and feet. Externally, the lids had become separated and were in a condition of entropion. The conjunctival sacs were small and ill developed, and the only indication of the presence of any globes was in the right orbit, in which a nodule could be felt behind the conjunctiva. Microscopically, the condition represented a failure on the part of the secondary optic vesicle or lens to meet the primary outgrowth from the fore brain, with the result that the lens lay below the primary vesicle, the two layers of which, never having come into contact, formed the wall of a distended cyst. The right optic nerve showed traces of axis cylinders, but no vessels, these lying below it. The nerve sheath was perfect excepting where it joined the rudimentary sclerotic. The choroid was only partially present, as was also the pig-

ment layer of the retina. The retina itself was situated below the cleft, and all the layers could be made out. The lens was present, with its vascular capsule, but the posterior capsule was replaced by connective tissue, and where this joined the anterior capsule the latter was thrown into folds. The lens itself was much vacuolated, but contained no nuclei. The large cyst due to the distension of the anterior part of the primary vesicle overlapped the lens, and was lined by cells resembling the nuclear layer of the retina. There appeared to be no attempt at formation of a cornea or anterior chamber. The external muscles combined with the levator palpebræ, took origin from around the optic foramen and passed forwards as a single thick band dividing at its anterior end into two, an upper and a lower; the upper band passed into the lid as did part of the lower, but from this latter, bands passed back to be inserted into the rudimentary sclerotic. The lacrymal glands and glands of Krause were present.

The left eye of this same fœtus showed failure in the closure of the cleft in the primary optic vesicle at the posterior pole of the globe just below the nerve, with distension forming a multilocular cyst containing folds of retina. The vitreous was represented by a mass of fibro-vascular tissue situated at the disc. The iris was completely adherent to the posterior surface of the cornea, there being no angle.

The third specimen was the right eye of a girl aged 20, whose other eye was normal, but in the eye in question the vitreous had atypically developed into true adipose tissue. The conjunctival sac in this case was small and ill developed but deep and conical in shape. At the apex of the cone a small eye was present. The anterior chamber was shallow and the iris showed a coloboma downwards and slightly inwards. The lens was calcareous and too hard to cut with the iris adherent to it. The choroid was extensively degenerated, and contained calcareous and bony material; the retina was much folded. The vitreous close to the disc consisted of fibrous tissue, but further forwards was composed of typical areolar tissue with well developed fat globules; at the back of the lens again it became fibrous. This fatty tissue might have been formed by degeneration, but the writer was of the opinion that the tissue was too well formed to be due to this and must have been arisen from atypical development.

Reginald E. Bickerton.

---

# Bibliography.


## Anatomy and Physiology.

Cirincione. Development of the Vitreous. *La Clin. Ocul.*, April.
Reymond. Reid's demonstrations of Anatomy of Cornea. *Giorn. d. Accad. di Med.*

## Congenital Abnormalities.

Clark. Cryptophthalmos. *Brit. Med. Jl.*, 9 July.
Gesang. Persistent pupillary membrane adhering to cornea. *Beitrage fur Aug.*, 60.
Knape. Congenital bilateral aniridia in father and son. *Woch. f. Ther. u. Hyg. des Auges*, 35.
Lewis. Hereditary ectopia lentis. *Archiv. of Oph.*, May.
Marlow. Unusual condition of iris and retina in two sisters. *Ophthalmoscope*, June.
Nicodemi. Etiology of colobomata in the fundus. *Annali di Ott.*, 289.
Osterroht. High hypermetropia with microphthalmos. *Beitrage fur Aug.*, 60.
Scalinci. Bilateral aniridia with ectopia lentis. *Annali di Ott.*, 7, 8, 9.
Thomas. Congenital defect of adduction, &c. *Ophthalmoscope*, June.

## Hygiene.

Oliver. Suitable colours for signalling. *Ophthalmoscope*, July.
Sayer. Deterioration of vision during school life. *Brit. Med. Jl.*, 18 June.
— Ophthalmia neonatorum. *Woch. f. Ther. Hyg. des Auges*, 35.

## Pathology and Bacteriology.

Bruns. Phlyctenules produced experimentally by dead cultures of tubercle bacilli. *Graefe's Archiv.*, 383.
Schattelius. Bacteriology of Conjunctivitis of Measles. *Klin. Mon. f. Augen.*, June.

## Instruments and Apparatus.

Coburn. Oculists' reflex shield. *N. Y. Med. News*, 28 May.
Hirschberg. A new large magnet. *Cent. f. Augen.*, June.
Hirschberg. Instruments of the Arabic surgeons. *Cent. f. Augen.*, June.
Holth. A new method of determining the refraction. *Ann. d'Ocul.*, June.
Murdoch. An eye bandage. *Ophthal. Record*, June.
Qurin. A medicated probe. *Klin. Monats. f. Augen.*, June.
Remy. Diploscope. *Rev. d'Oph.*, April.
Vallet. Astigmatism: Remy's diploscope. *Rev. d'Oph.*, May.

## Therapeutics.

Claiborne and Coburn. Yohimbin. *N. Y. Med. News*, 9 July.
Daconto. Acoin. *Woch. f. Ther. und Hyg. des Auges*, 41.
Darier. Four years experience of dionine. *Die Oph. Klinik.*, 5 July.
Grandclement. Glaucoma and adrenalin. *La Clin. Oph.*, 25 June.
Guttmann. New method of local anæsthesia of eyeball. *Arch. of Oph.*, May.
de Lapersonne. Stovain, a new local anæsthetic. *Woch. f. Ther. und Hyg. des Auges*, 36.
de Wecker. Jequiritol. *Annales d'Oc.*, June.
Williams. Radium in some diseases of the eye. *Boston Med. and Surg. Jl.*, 26 May.

## Operations.

Bruns. Method of advancing tendons of muscles. *Oph. Record*, June.
Butler. Premature expulsion of lens during extraction. *Ophthalmoscope*, July.
Fage. Value of iridectomy in opacities of cornea. *Recueil d'Oph.*, June.
Hale. A new method of blepharoraphy. *Klin. Monats. f. Augen*, June.
Mazet. Keratectomy. *Recueil d'Oph.*, May.
Pechin. Benefit of iridectomy in extraction. *Arch. d'Oph.*, June
Snyder. Operation to correct badly placed canalicular cuts. *Oph. Record*, June.
Villard. Operation for trichiasis. *Recueil d'Oph.*, May.
de Wecker and Landolt. Surgical treatment of paralytic strabismus. *Arch. d'Oph.*, July.
Wolf. Operation for ptosis. *Wien. Med. Woch.*, 28, 49.

## Traumatisms.

Buchanan. Severe concussion injury to eye. *Glasgow Med. Jl.*, July.
Franck. Mercurial treatment of perforating injuries. *Beit. zur Augen.*, 60.
Marple. Removal of foreign bodies from the eye. *N. Y. Med. Record*, 25 June.
Villard. Sulphuric acid burns of the eye. *Arch. d'Oph.*, June.

## Tumours.

Baillart. Metastatic cancer of choroid. *Rev. d'Oph.*, June.
Doyne. Sarcoma of conjunctiva. *Ophthalmoscope*, July.
Moissonnier. Cylindroma of Orbit. *Arch. d'Oph.*, June.
Verhoeff. Sarcoma of choroid with destructive hæmorrhage. *Archiv. of Oph.*, May.

## Sympathetic Ophthalmia.

Sourdille. Morbid predisposition in one eye caused by injury to the other. *Arch. d'Oph.*, June.

## Glaucoma.

Grandclément. Glaucoma and adrenalin. *La Clin. Oph.*, 25 June.
de Lapersonne. Glaucoma and cataract. *Arch. d'Oph.*, June.
Schmidt-Rimpler. The glaucoma cupping of the disc. *Graefe's Archiv.*, 58-3.
Sommer. Prophylaxis of acute glaucoma. *Woch. f. Ther. u. Hyg. des Augrs*, 37.

## Amblyopia and Visual Defects.

Fraenkel. Unilateral amaurosis after hæmorrhage. *Berl. Medizin. Woche*, 225.
Jamieson. Transient monocular blindness. *Oph. Record*, June.

## Refraction and Optical Questions.

Benson. Operative treatment of myopia. *Med. Press*, 1 June.
Herrick. Colour vision. *Jl. Compar. Neurol. and Psychol.*, June.
Holth. A new method of determining the refraction. *Annales d'Oc.*, June.
Parinaud. Stenoscopy and projection. *Annales d'Ocul.*, June.
Schild. Determination of heterophoria. *Ophthalmic Record*, June.
Stilling. The myopia question. *Klin. Monats. f. Augen*, June.
Vallet Astigmatism: Remy's diploscope. *Recueil d'Oph.*, May.
Wiesner. Asthenopia. *N. Y. Medical News*, 14 May.

## Regional Affections.

### Eyelids.

Patrizi and Bellentani. The reflex wink. *Arch. Ital. de Biol.*, 41-2.
Rognao. New procedure to correct epicanthus. *Ann. d'Ocul.*, June.
Terson. Palpebral dermatolysis. *Arch. d'Oph.*, June.
Villard. Treatment of trichiasis by operation. *Ann. d'Ocul.*, June.
Wolf. Operation for ptosis. *Wien. Med. Woch.*, 28, 29.

### Lachrymal Apparatus.

Basso. Extirpation of lachrymal sac and canals. *Annali di Ott.*, 7, 8, 9.
Bérard. Abuse of catheterism in simple dacryocystitis. *La Clin. Oph.*, 10 July.
Natanson. Changes in lachrymal glands after destruction of the passages. *Klin. Monats. f. Augen*, June.

### Conjunctiva.

Doyne. Sarcoma of conjunctiva. *Ophthalmoscope*, July.
Foster. Naevus of conjunctiva. *Klin. Monats. f. Augen.*, June.
Jocqs. Parinaud's conjunctivitis. *Die Oph. Klinik*, 6 June.
Kreibich. Effect of sunlight on conjunctiva. *Wien. Klin. Woch.*, 24.
Schottelius. Bacteriology of conjunctivitis of measles. *Klin. Monats. f. Augen.*, June.
Terrien. Subconjunctival cysticercus. *Arch. d'Oph.*, July.

### Cornea and Sclerotic.

Bodenstein. Amyloid deposits in Cornea. *Beiträge fur Aug.*, 60.
Bruos. Phlyctenules experimentally produced by dead cultures of tubercle bacilli. *Graefe's Archiv.*, 58-3.
Callan. Regeneration of cornea after ulcus serpens *Amer. Med.*, 9 July.
Dor. Conical cornea cured by opotherapy. *Rev. Gen. d'Oph.*, 30 June.
Dorais. Phlyctenular keratitis. *Pacific Med. Jl.*, June, 1902.
Elschnig. Keratoconus. *Woch. f. Ther. und Hyg. des Augrs*, 36.
Fage. Value of iridectomy in opacities of cornea. *Recueil d'Oph.*, June.
Fehr. Lattice-work keratitis. *Cent. f. Augen*, June.
Oatman. Corneal cysts. *Arch. of Oph.*, May.

## Iris and Ciliary Body.

Bertolotti. Argyll Robertson pupil in syphilitic meningitis. *Revist. Crit. di Clin. Med.*, 23.
Frank. Hysterical iridoplegia. *Arch. of Oph.*, May.
Moissonnier. Tubercular iridocyclitis. *Arch. d'Oph.*, July.
Oliver. Uveitis in congenital syphilitis. *Amer. Jl. Med. Sci.*, July.

## Lens.

Gatti. Naphthalin cataract. *Annali di Ott.*, 7, 8, 9.
Grilli. Cryoscopy and senile cataract. *Recueil d'Oph.*, June.
de Lapersonne. Glaucoma and cataract. *Arch. d'Oph.*, June.
Lewis. Hereditary ectopia lentis. *Arch. of Oph.*, May.
Lingsch. Cataract from lightning stroke. *Wien. Med. Woch.*, 23.
Rollett. Eventual results of operation for senile cataract. *Rev. Gen. d'Oph.*, 30 June.

## Choroid and Vitreous.

Bailliart. Metastatic cancer of choroid. *Rev. d'Oph.*, June.
Baquis. Angio-sarcoma of choroid. *Annali. di Ott.*, 7, 8, 9.
Fuchs. Anatomical changes in choroiditis. *Graefe's Archiv.*, 58-3.
Verhoeff. Sarcoma of choroid with destructive hæmorrhage. *Archives of Oph.*, May.

## Retina.

Fish. Detachment of retina cured by treatment. *Oph. Record*, June.
Fox. Albuminuric retinitis. *N. Y. Med. Jl.*, 25 June.
Tschemolossow. Retinal hæmorrhages and tape worm. *Die Oph. Klinik.*, 10.

## Optic Nerve.

Barrett and Orr. A series of cases of optic neuritis. *Intercol. Med. Jl. of Australasia*, 20 May.
Kampherstein. Pathogenesis of Choked disc *Klin. Mon. f. Augen.*, June.
Scalinci. Toxic optic neuritis. *Annali di Ott.*, 7, 8, 9.
Schmidt-Rimpler. The glaucoma cup. *Graefe's Archiv.*, 58-3.

## Muscles (and Strabismus).

Gradle. Paralysis of lateral movements. *Arch. of Oph.*, May.
Papadaki. Paralysis of III. nerve in tabes. *Rev. Neurol.*, June.
de Wecker and Landolt. Surgical treatment of paralytic strabismus. *Arch. d'Oph.*, July.
Wells. Worth's opinion on muscle training. *Oph. Record*, June.

## Orbit and Globe.

Dor. Ocular complications of sphenoidal sinusitis. *Lyon Médical*, 17 July.
Miller. Cyst of Orbit. *Brit. Med. Jl.*, 2 July.
Moissonnier. Cylindroma of Orbit. *Arch. d'Oph.*, June.
Swasey. Exophthalmos of obscure origin. *Oph. Record*, June.
Whitehead. Empyema of frontal sinus, &c. *Arch. of Oph.*, May.

## Relations with Medicine.

Bertolotti. Argyll Robertson phenomenon in syphilitic meningitis. *Ricist. Crit. di Clin. Med.*, 23.
Brissaud and Péchin. Ocular hemiplegia. *Arch. d'Oph.*, July.
Gould. Torticollis and curvature of spine due to eye strain. *American Medicine*, 21 May.
Jessop. Ocular manifestations of syphilis. *Practitioner*, July.
Klien. Incoordination of eye movements in a superficial brain lesion. *Deutsch. Zeit. f. Nerven.*, 26, 4.
Montyel. Reflex ocular troubles in general paralysis. *Rev. de Psych.*, 5.
Orlandini. Diseases of nerve and retina in relation to circulatory and urinary diseases. *Annali di Ott.*, 7, 8, 9.
Papadaki. Paralysis of III. nerve in tabes. *Rev. Neur.*, June.
Posey. Paralysis of extraocular muscles in exoph. goitre. *Amer. Jl. Med. Sci.*, July.
Suker. Surgical treatment of Bright's disease from ophthalmic standpoint, *N. Y. Med. Jl.*, 4 June.

## Miscellaneous.

Birch-Hirschfeld. Action of ultraviolet rays upon the eye. *Graefe's Archiv.*, 58-3.
Bistis. Ocular complications of lactation. *Arch d'Oph.*, July.
Cockburn. Hæmorrhages in the eye present at birth. *Arch. of Oph.*, May.
Cosmettatos. Action of nicotine on superior cervical ganglion. *Arch d'Oph.*, July.
Deschamps. Partial temporary disablement from injuries to the eye. *La Clin. Oph.* 10 July.
Galezowski. Diagnosis in diseases of the eye. *Rec. d'Oph.*, May.
Gasparrini. Changes following extirpation of superior cervical ganglion. *Annali di Ott.*, 7, 8, 9.
Hess. A peculiar optical phenomenon. *Graefe's Archiv.*, 58-3.
Hirschberg. The avoidance of parasitic diseases. *Berlin Klin. Woch.*, 25.
Luthmer. Care of the blind in eye clinics. *Woch. f. Ther. Hyg. des Auges.*, 39.
Fergens. The manufacture of spectacles. *Klin. Mon. f. Augen*, June.
Schanz. How persons blind from birth learn to see after operation. *Woch. f. Ther. u. Hyg. des Auges.*, 37.
Teillais. Ocular traumatic hysteria. *Rec. d'Oph.*, June.

# THE EFFECT OF ACCIDENTALLY DIMINISHED ACUTENESS OF VISION ON ITS EFFICIENCY.

By George A. Berry, M.B.

The subject for general discussion at the forthcoming International Ophthalmological Congress is the relation between efficiency and acuteness of sight. In 1893 I discussed this question in a paper to the Ophthalmological Society of Great Britain. The more general interest which it has since aroused, and the greater importance which it has assumed in view of the Employers' Liability Act, have induced me to reconsider the conclusions at which I then arrived.

I am still of the same opinion that it is impossible to postulate any relationship which can be applicable to all cases. My original formula connecting acuteness of vision $V$, with efficiency $E$, was only proposed as a guide. It attempted to give some estimate of the relative loss in efficiency caused by visual defects distributed in varying degrees over the two eyes. The efficiency values to be deduced from it made no pretence to anything but relative applicability.

The principles upon which the formula was founded still appear to me to be sound. I do not think it is because I had formulated them independently of anything previously written on the subject that I am still inclined to adhere to them after studying much of the subsequent work that has been done. I have in the interval tried many different ways of attacking the problem, but have found all of them less satisfactory in principle. Some of the German formulæ are, as it seems to me, unnecessarily complicated. They do not lend themselves readily to the construction of

tables, as there are too many variables, and some of the factors introduced cannot be said to be of sufficient importance. Besides, such formulæ aim at a degree of precision which is surely, under the circumstances, altogether undesirable, not to say ridiculous. Yet I think some formula with tables deduced from it is useful. I do not altogether agree with those who assume that the question does not admit, in part at least, of a mathematical solution.

I would suggest that a useful working formula should be simple and be based upon reasonable principles introducing only factors of importance. It should also be sufficiently elastic, so that an arbitrary change in the value of one or more of the factors should be capable of affecting the value in a manner consistent with any special requirements. It may, for instance, be advisable to gauge the visual efficiency value in the same case, presenting always the same visual acuteness, differently for the first six months or one year after an accident from subsequently when the individual has become accustomed to the new conditions.

There are no doubt—this has indeed been shown to be the case—individual differences. These have therefore to be considered. Equal efficiency may be attained in certain occupations by individuals having different, sometimes widely different, degrees of visual acuteness. Thus the same defect in acuteness will be found to impair the efficiency in one case more than in another. But there must be a limit to this—a point at which it can be reasonably inferred that the extent of loss of efficiency often claimed to exist is more imaginary or assumed than real.

Again, there is a difference in age and consequently in the seriousness to the individual of the result of an accident which impairs the sight. The position of an old man, whose

accidentally lowered acuteness of vision still leaves him with just enough sight to pursue his habitual employment with the same degree of efficiency as before, is different from that of a young man who, similarly situated as regards the loss sustained, may have had otherwise good reason to look forward to obtaining work which would entail a higher efficiency.

These and many others that might be adduced are reasons for introducing into a formulated relationship between visual acuteness and visual efficiency a factor, the value given to which admits of an arbitrary change. The introduction of this element of elasticity is the only important change which I should purpose to make in my former solution.

To make this clear I may shortly restate the argument which led to the formula previously adopted. The starting point is the case of complete loss of one eye with full vision in the other. The extent of loss in this case from an efficiency point of view will depend upon the nature of the work done, the age of the individual and the disfigurement, amongst other less evident factors. It is therefore a mistake to take any definite fractional value as always representative of the case. Yet it must always represent some fraction of full efficiency though not necessarily always the same fraction.

If we denote this fraction as $\frac{m}{m+1}$ it will take any value according to the value given to $m$. Thus for $m=3$ it is $\frac{3}{4}$, for $m=2\frac{1}{2}$ or $3\frac{1}{2}$ it is $^5/_7$ or $^7/_9$.

What then is the expression which will have the value *unity* for full vision in both eyes and the value $\frac{m}{m+1}$ for full vision in one eye and blindness of the other? We

must have *efficiency* $=1$ for $V=V''=1$, *i.e.*, $V+V''=2$, putting $V$ for the visual acuteness of the one eye and $V''$ for that of the other, and *efficiency* $=\frac{m}{m+1}$ for $V=1$, $V''=0$.

This relationship is given by the formula

$$e=\frac{m(V+V'')}{(m-1)(V+V'')+2} \quad . \quad . \quad . \quad . \quad (1).$$

where $e$ stands for efficiency.

The next point to be considered is whether the same formula also gives a suitable efficiency value when $V''=0$ and $V$ has different values varying from 1 to 0. In this case we should have

$$e=\frac{mV}{(m-1)V+2}$$

Here $e$, as no doubt it should, diminishes less rapidly than $V$. A still slower fall at first with the diminution of $V$ than this gives suggests itself, however, as a more appropriate relation. This can be got by adding to $e$ some proportion of $1-e$, which, though making $e$ vary with $V$ when $V$ is less than 1, does not alter $e$, for $V=1$.

A formula to comply with these requirements would take the form:

$$e^1=e+\phi(V)\times(1-V)(1-e)$$

Here when $V=1$, $e^1=e$, whereas for any value of $V<1$, $e^1>e$, if $\phi(V)$ is always taken positive.

After some trials I have selected as the most suitable function of $V$ its square, and write

$$e^1=e+V^2(1-V)(1-e)$$

Now if we alter (1) in the same way and write $S$ for $V+V''$ we get

$$e^1=e+S^2(1-S)(1-e) \quad . \quad . \quad . \quad . \quad . \quad (2).$$

From (2) it is clear that: $e^1$ is greater than $e$ for any value of $S$ less than unity, while for values of $S$ between 1 and 2, $e^1$ is less than $e$. For $S=1$ or $S=2$ again, $e^1=e$.

Efficiency is, however, obviously always greater when the two eyes contribute to the total visual sharpness. Take, for instance, $V=V'=\cdot 5$. The efficiency in this case is certainly greater than with $V=1$, $V'=0$. And, in general, $V+V'=x$ represents a higher efficiency than $V=x$.

To begin with the case of $V=V'$, which may be looked upon as the one giving the greatest efficiency except perhaps for very low values of $V+V'$ or $S$, some proportion of the difference between $e^1$ and unity must be added to $e^1$ to represent the efficiency in this case. The proportion must also vary with the total value of $S$. Putting $\eta$ for the value of efficiency in general where $V=V'$ we may write:

$$\eta=e^1+\frac{S}{2}(1-e^1) \quad . \quad . \quad . \quad . \quad . \quad (3).$$

All other values of $V+V'$ may be taken to be somewhere between those given by $\eta$ and $e^1$ in equations (3) and (2). As I have previously suggested they may be appropriately taken to vary in the proportion of the difference between $V$ and $V'$ to the sum of $V$ and $V'$, or putting $V-V'=D$ and $V+V'=S$ as $\frac{D}{S}$

We can now get an expression for efficiency in general which we may denote by $E$. It will be:

$$E=\eta-\frac{D}{S}(\eta-e^1) \quad . \quad . \quad . \quad . \quad . \quad (4).$$

When $D=0$, *i.e.*, when $V=V'$, $E=\eta$. When $\frac{D}{S}=1$, *i.e.*, when $V'=0$, $E=e^1$. Now we have only to substitute in (4) the value of $e$, $e^1$ and $\eta$ from (1) (2) and (3), and simplify

to get the general efficiency equation in terms of $V$ and $V'$. It becomes:

$$E=(1-V')\frac{mS+S^2(1-S)(2-S)}{(m-1)S+2}+V'.$$

In this expression the value of $E$ besides depending upon that of $V$ and $V'$ will also depend upon what value is ascribed to $m$. The guide to this again is, as we have seen, the point from which it seems one must start, viz., the efficiency which must be assumed in the case of complete loss in one eye with full vision remaining in the other.

Of course, to make the formula of any use as a guide some value must be given to $m$, even should it be the case, as it no doubt sometimes is, that the loss of one eye entails no reduction of efficiency.

I have calculated the table which the formula for $E$ gives for different combinations of $V$ and $V'$ taken as varying by tenths when $m=3$. This I give merely as an illustration. It represents, however, a table of average applicability.

In this method of looking upon the question of efficiency I have not taken into consideration anything but the acuteness of central vision. Such points as defects in the field of vision, loss of binocular vision with diplopia, etc., do not, as it appears to me, admit of being treated in the same manner. As regards losses of the field of vision, the only ones of a stationary nature that are likely to be caused by accident are those of the homonymous hemianopia type. The effect produced by these will vary according to their completeness and their extent, according to the side for which the blindness exists, and according as there are or are not complications of the nature of alexia, etc. As further, the effect must vary greatly according to the

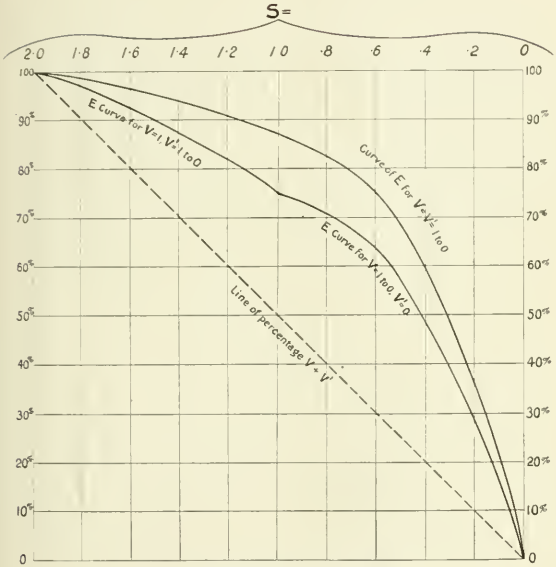


EFFICIENCY CURVES.

All values of $E$ are included between the curves when $m=3$ in formula.

$$E=(1-V')\frac{mS+S^2(1-S)(2-S)}{(m-1)S+2}+V'$$

Loss.

| V= | 1·0 | ·9 | ·8 | ·7 | ·6 | 5 | ·4 | ·3 | ·2 | ·1 | 0 | | | V' |
|---|---|---|---|---|---|---|---|---|---|---|---|---|---|---|
| 0 | 75 | 73s | 71 | 67s | 64 | 56s | 48s | 39 | 27s | 21 | 0 | | 0 | 1·0 |
| ·1 | 78s | 77s | 76 | 74 | 70s | 68 | 60s | 53s | 45 | 35 | | 1 | 1 | 9 |
| ·2 | 81 | 81 | 80 | 79 | 77 | 74 | 72 | 65 | 59 | | 4 | 3s | 2s | 8 |
| ·3 | 84 | 83s | 83 | 82s | 81s | 79s | 77 | 75 | | 7 | 6s | 5s | 5 | ·7 |
| ·4 | 86s | 86 | 86 | 85s | 85 | 84 | 82s | | 9s | 9 | 9 | 8s | 7 | 6 |
| ·5 | 89s | 89 | 88s | 88s | 88 | 87s | | 12s | 12 | 11s | 11s | 11 | 10s | ·5 |
| ·6 | 93 | 91s | 91 | 91 | 90s | | 17s | 16 | 15 | 14s | 14 | 14 | 13s | ·4 |
| ·7 | 95 | 94s | 93s | 93 | | 25 | 23 | 20s | 18s | 17s | 17 | 17 | 16 | ·3 |
| ·8 | 97s | 96s | 96 | | 41 | 35 | 28 | 26 | 23 | 21 | 20 | 19 | 19 | ·2 |
| ·9 | 99 | 99 | | 65 | 55 | 46s | 39s | 32 | 29s | 26 | 24 | 22s | 21s | ·1 |
| 1·0 | 100 | | 100 | 79 | 72s | 61 | 51s | 43s | 36 | 32s | 29 | 26s | 25 | 0 |
| V'= | | | 0 | 1 | 2 | ·3 | 4 | 5 | 6 | 7 | 8 | ·9 | 1·0 | =V |

Efficiency.

Table for $m=3$ in formula for efficiency.

$$E=(1-V')\frac{mS+S^2(1-S)(2-S)}{(m-1)S+2}+V' \quad \Big\| \quad (S=V+V')$$

occupation of the individual, each case would always require to be considered on its own merits.

In conclusion I must emphasise the point with which I started, that *any* formula can only serve as a guide to the estimation of the relative loss of efficiency caused by loss to sight according as it is distributed over the two eyes. Even in the indeterminate form which has been given to the above expression there must be circumstances in which it would not be available. Put in a hard and fast form, without any element which admitted of arbitrary variation, this defect would be much more apparent.

The curves show in a graphic way the manner in which $E$ diminishes with $V$, for $m=3$.

---

## REVIEWS.

F. Schieck (Göttingen). **Pathological Anatomy of Vernal Catarrh.** *v. Graefe's Archiv. für Ophthalmologie*, 58, 1.

There have been almost as many theories of the nature of this disease as there have been papers upon it. The chief difference of opinion has been as to whether the changes in the epithelium or in the stroma of the conjunctiva were the primary; whether it might be cancroid or adenoid. In the majority of reported cases the epithelial growths are larger. The author has examined four cases of spring catarrh and has drawn from them a new theory of the disease. His first case was a typical one of three years' duration. The tarsal conjunctiva of the upper lid in both eyes was converted into flat-topped papules of a hard consistency and milky appearance. At the limbus there was in both eyes a small thickening at the outer part. The tarsus with the conjunctiva over it was excised on both sides. Horizontal sections perpendicular to the plane of the tarsus and running its whole breadth showed the following. A section through the most advanced region

has nine or ten papillæ sitting on the central portion of the tarsus. They are polypoid growths, and the furrows separating them reach down to the tarsus. Tubules and solid epithelial processes branch off from the furrows. At the bottom of the deepest ones there is no epithelium on the tarsus. On both the temporal and nasal side of this central region there is a smaller zone in which the papillæ are not so well formed and are separated by shallow grooves which do not reach down to the tarsus. At the margins of the tarsus the conjunctiva is greatly thickened, but there are no grooves, in fact the epithelium is little changed. The three zones pass gradually into one another, and the lateral are the youngest.

The central papillæ show a connective tissue framework which has a firm root on the tarsus, intermingling with its fibres so that there is no distinct boundary. This framework branches until it becomes a number of fibrils streaming from the centre in all directions. These fibres stain with elastic fibre stains and are continuous with the elastic fibre network of the tarsus. Between the fibres and the epithelium there is a peculiar glancing layer with few nuclei. There is a degenerated area. The fibres have become swollen and agglutinated together, forming highly refractive homogeneous bands, for which the author was unable to find any stain characteristic of the usual connective tissue degenerations. Lying among the finer fibres underneath the degenerated area there are collections of oval cells, descendants of the fixed tissue cells. Leucocytes are also present, but they are aggregated round the bottoms of the furrows, between the individual papillæ. They lie just under the epithelium. Mast cells and epithelial cell nests are scattered about. The epithelium is thickened, and on the flat summits sends a few solid processes into the papillæ, but on their sides it sends a number of solid and cystic processes into the stroma. It is squamous on the free surface and cylinder-celled with many goblet-cells in the grooves. The papules in the second zone show all the above changes but in less intensity. In the third zone the thickening of the epithelium and its processes are absent. The degenerated layer is absent. The spindle and oval cells, descendants of the fixed tissue cells, lie immediately under the epithelium, while only a few leucocytes are present. The branching framework, characteristic of the central papillæ, can be seen in all stages of development. The elastic fibres of the tarsus lose their

normal horizontal direction, and turning vertically, are directed towards the free surface of the conjunctiva. As they approach the sub-epithelial infiltrated region they give up their staining properties, indicative of commencing degeneration. Although the conjunctiva is greatly thickened, the epithelium takes almost no part in it.

The author's second case had only a small growth at the limbus of the cornea of seven months' duration. It consisted chiefly of collections of oval and round cells which were neither lymph follicles nor trachoma bodies, but descendants of the fixed tissue cells. Numerous elastic fibres were intermingled among the cells, and towards the surface underwent a similar glassy degeneration as already described, forming a narrow sub-epithelial layer with few cells. Opposite several of these cell collections there were short epithelial processes running into the stroma, as if the bulging caused by the former had induced the epithelium to attempt to surround them. These changes are very similar to those found at the margin of the tarsus in the first case, and are apparently the early stage of the process. The other two cases confirmed the above results.

The author points out that in all the cases there is an increase of the connective tissue cells and a great hypertrophy of the elastic fibres, while the changes in the epithelium vary from nothing to cancroid growths. Although Schieck has not had a case with a tumour-like growth at the limbus, two such reported have the same structure as the papillæ in his first case. If one compares a normal section it is found that the tarsus is sharply differentiated from the conjunctiva, which is very thin, whereas in the early stages in the first case it is thickened and the boundary between the tarsus and the conjunctiva is lost. Prokopenko discovered a 5mm. broad elastic girdle lying on the sclera at the limbus. The tarsus and this part are the only portions of the conjunctiva having an elastic bed under them. The earliest changes are cellular and elastic fibre increase. These degenerate with disappearance of the fixed tissue cells, changes which have been observed in endarteritis and pleuritic membranes. The elastic fibres are probably produced directly by the cells. The leucocytes represent an inflammatory reaction from absorption in the depth of the furrows. One of the chief causes of previous opinions has been incomplete removal. No one has apparently examined for elastic fibres. The changes in the epithelium are

the result of chronic irritation, the bulging forwards and the movements of the lids. The author could not find any bacteria. As to etiology, he suggests some chemical irritation, but acknowledges ignorance. He advises that the subconjunctival matrix of elastic fibres should be removed as far as possible along with the growth.

W. B. Inglis Pollock.

---

Th. v. Ewetzky (Jurjew). **Syphiloma of the Ciliary Body.** (Mittheilungen aus der Augenklinik in Jurjew. Heft 1). Berlin: S. Karger, 1904.

In this work of 110 pages the author endeavours to give a complete account, both clinical and anatomical, of syphilitic affections of the ciliary body. Diseases of the iris due to this cause have been fully described by v. Schroeder, Widder and Krückman, but previous to this no connected account of syphiloma of the ciliary body had appeared. The first thing which strikes one, says Ewetzky, on perusing the literature of the subject, is the uncertainty of the differential diagnosis, more especially with regard to superficial syphilitic tumours of the conjunctiva or sclera. A still more difficult question is the determination of the particular stage of syphilis to which the tumour should be assigned. The work opens with a description of four new cases in two of which a microscopical examination was made; then follows a table of 64 recorded cases. With this material in hand the author has elaborated a very complete and interesting treatise, which is well worthy of a careful study, especially from a clinical point of view.

The disease begins generally with symptoms of severe iridocyclitis, accompanied by slight hyperæmia and œdema of the upper lid, and often by chemosis of the conjunctiva. The condition of the cornea varies from slight haziness to an intense parenchymatous, vascular opacity, the changes being naturally most marked in the neighbourhood of the tumour, which soon forms in the ciliary region. There is often keratitis punctata and not infrequently hypopyon (in 28 per cent. as compared with 4 per cent. in syphilitic iritis). The anterior chamber is shallow or unequal in depth in different places; in two cases only was it deeper than normal. The intra-ocular tension is generally lowered, but may be raised. The tumour begins as

a round, smooth, firm nodule, of variable colour, which gradually extends round the corneal margin and in rare cases surrounds it completely. Its margin is steep near the cornea, but flattens off at the opposite side. It increases in size for a variable period, and then undergoes a retrogression, followed by a more or less flattened scar, or else (in 40 per cent.) it ruptures at the most prominent point and discharges a yellowish fluid or caseous substance under the conjunctiva and leads to partial or complete phthisis bulbi. The general description which we have just given has been taken from different portions of the work. We shall now discuss some of the more important details.

Perforation takes place most frequently through the sclerotic, the next most common event being simultaneous rupture through the sclerotic and into the anterior chamber. The process is not a mechanical one, but is due to the involvement of the sclerotic in the disease. The conjunctiva is usually adherent to the tumour, but rarely perforated by it. It is a curious fact, for which the author can give no reason, that in 45 out of 76 cases the tumour was situated at the outer side of the vertical meridian of the eye. It is generally single; more than two syphilomata have never been observed in one eye. The colour, as stated before, is variable, but tends to become yellow when caseous degeneration sets in, unless it happens to be concealed by the presence of pigment. The pigmentation is not, as some writers believe, due to the uvea, which as a matter of fact is separated from the surface by the whole thickness of the tumour. The syphiloma appeared in the vitreous in four instances, and in one only was it visible in the vitreous alone; it should be mentioned that in these cases the inflammatory symptoms were very slight, and there were no posterior synechiae or exudations, thus rendering the examination of the fundus possible, a thing which cannot be accomplished in the vast majority of the cases. Hypopyon, when it occurs, is not a true hypopyon, but consists of the products of the degeneration of the tumour or of precipitates from the aqueous humour. Two factors act in opposite directions as regards their influence on the intra-ocular tension, namely, the cyclitis and the presence of a tumour; the latter of course tending to raise it except when it bursts through the sclerotic. Seventy-five per cent. of the patients were between 20 and 40 years of age. Only 15 women were affected

as compared with 47 men. The severity of the disease is shown by the fact that 78 per cent. of the eyes attacked were rendered totally unfit for work. Furthermore, 28 per cent. ended in atrophy of the eyeball and enucleation was necessary in 30 per cent. In typical cases the diagnosis is simple. Syphilitic growths of the conjunctiva are multiple and freely movable over the sclerotic. Syphiloma of the sclerotic in the ciliary region is not pigmented or surrounded by a ring of pigment, nor does it begin with severe iridocyclitis or affect the intra-ocular tension. A deeply pigmented syphiloma of the ciliary body may suggest melanotic sarcoma, from which, however, it differs, as a rule, in being accompanied by severe inflammatory symptoms and diminished tension. In doubtful cases the effect of anti-syphilitic treatment will assist one in making a diagnosis. Tuberculosis of the ciliary body occurs chiefly in patients under 20 years of age, there is less inflammation and pain; the history, injection of tuberculin, and inoculation experiments will also help to decide the question.

As regards etiology, only two cases were due to inherited syphilis. In the acquired disease the syphiloma appeared in the early stage of the systemic affection (43 per cent. in the first half-year and 22 per cent. in the second half), and was generally accompanied by secondary manifestations. More rarely it appeared shortly after the latter. The cases which are associated with an early development of tertiary symptoms, and which have been described as "gommes précoces du corps ciliare," do not take a different course from the ordinary variety of the disease, and have therefore no claim to be regarded as forming a separate group. Ewetzky questions the possibility of distinguishing papules from gummata on pathological grounds, and considers that from the clinical point of view also the term syphiloma is sufficient for all practical purposes. The last chapter gives a detailed description of the pathology of the disease, and traces its effects on the different parts of the eye. The results obtained from the pathological examinations are rather one-sided, as the eyes available for the purpose were removed in the later stages of the disease. The tendency of the growth to spread along the ciliary body and thus to form an incomplete, or less frequently a complete, ring is amply confirmed, whereas the rupture in the sclerotic is always confined to a small area. He confirms the results of

previous observers as regards the structure of the growth. It consists of granulation tissue exhibiting a very marked tendency to caseous degeneration in the centre, and is made up of the usual arrangement of leucocytes, endothelioid cells, and connective tissue in different stages of development. In some cases a fibrous scar alone remained. Ewetzky found giant cells in one of his cases, but these are not usually present. The pigmentation he believes to be due to the destruction of the epithelium of the pars ciliaris, the pigment granules of which become liberated and are then taken up by the cells and tissue of the tumour. The syphiloma does not tend to project far into the vitreous humour like a sarcoma, but on the contrary attacks the anterior parts of the eyeball.

A bibliography with critical remarks thereon brings this extremely interesting and well written pamphlet to a close.

L. W.

---

O. Parisotti (Rome). **Pathological History of the Eye,** 1904. Paris: Baillière et Fils.

This book, after a preliminary chapter on technic, deals with pathological conditions found in the eye from the point of view of one engaged in histological research and interested in the various theories put forward by fellow-workers. It is therefore hardly a book to be recommended to any who are not to a large extent conversant with the very abstruse matters with which it deals, and even for those who are its value is much restricted by the lack of any systematic bibliography of the various papers referred to. It deals with the whole subject, but at very unequal length. Specially long chapters are devoted to sarcoma of the choroid and glioma of the retina, while on the other hand, retrobulbar neuritis is dismissed with a single page and sympathetic ophthalmia with two. The chief attraction of the book lies in the coloured plates, of which there are twenty. The first shows an epithelioma of the bulbar conjunctiva which has penetrated into the interior of the eye. The route by which penetration has taken place is shown to be the sheath of one of the anterior perforating ciliary arteries. This is a good example of what Parsons in his work on the Pathology of the Eye, now appearing, says of these tumours (vol. i., p. 145), "When the globe is invaded it is along the peri-vascular and peri-neural lymph spaces of the corneo-scleral junction,—never

elsewhere; it is the weak spot of the eye, and whilst epibulbar sarcomata rarely penetrate the globe, the epitheliomata do so more frequently." The second plate shows another conjunctival epithelioma which has not penetrated to the deeper parts of the eye, but which forms a large mass advancing on the outer side of the sclerotic towards the posterior pole. Another plate (plate viii.) illustrates a tumour of the cornea which presented the appearance of a malignant growth, but which after three operations remained without recurrence for over four years, and which the writer describes as a papilloma or "papillary epithelioma." There are cell-nests figured in the plate, and the conjunctiva appeared to be quite free from the growth so that the case should be interesting to pathologists and may constitute a seventh case of primary epithelioma of the cornea of which according to Parsons (*loc cit*, p. 263) only six have been recorded.

Another plate illustrates hyaline degeneration of the conjunctiva, a rare condition, which has been described by Herbert, whose work, however, is not referred to. Then we have an example of Sattler's second group of tuberculosis of the conjunctiva,—small nodules occurring in this instance on the bulbar conjunctiva and showing on section a well-marked tubercular structure. Then follow sections of pterygium, the most notable feature of which is the presence of highly refractive round bodies with minute excrescences or buds which the writer takes to be blastomycetes. He has also observed them in cases of trachoma and spring catarrh. While admitting with Fuchs that in many cases pterygium is developed from a pinguecula, some new factor is required to account for its frequent recurrence, and this he suggests is a vegetable parasite.

Another plate illustrating a case of "perithelial sarcoma of the limbus" shows very well the "pallisade" arrangement of the cells which surround spaces formed by vessels. Then we have good illustrations of a tubercle of the iris and of gumma of the ciliary body. The cases of deeper disease illustrated are albuminuric retinitis, melano-sarcoma of the choroid (in which a large mass of the tumour is shown outside the eyeball and an islet inside the optic nerve), and glioma of retina. On this subject the various theories of origin from the mesoblast, by way of fœtal vessels anastomosing with retinal vessels, from the external and from the internal layers of the retina, are

discussed at great length, and the conclusion arrived at is, "It cannot be too often repeated; we do not know the road which glioma takes to enter the eye." The plates show good illustrations of (1) a glioma occupying a great part of the globe, but in which the retinal layers on one side of the disc are still undestroyed; (2) a glioma at an early stage appearing at an edge of the disc, and apparently spreading by the nerve fibres; and (3) an early case in which nodules appear in the orbital tissue while none could be found in the nerve. In another case described the tumour appeared to have been propagated along the perivascular sheaths of the central vessels, the sheaths of the optic nerve, and the sheaths of the vessels traversing the sclerotic.

A. H. T.

---

F. de Lapersonne. **Stovaine.** *Recueil d'Ophtalmologie*, May, 1904.

This, the latest addition to the list of local anæsthetics, was prepared by Fourneau from one of the amino alcohols, who has given it its name of Stovaïne. Chemically, it is the hydrochlorate of benzoic ether of dimethylamin-propanol. De Lapersonne, having been requested to examine into its clinical value in ophthalmology, first satisfied himself in the laboratory that it was harmless and caused no ill-effects; he then proceeded to test it in practice, and recently gave an account of his results before the Ophthalmological Society of Paris. The toxicity of stovaïne he finds to be distinctly less than that of a solution of cocain of equal saturation. Using a 4 per cent. solution in the rabbit, he obtained anæsthesia after three drops had been instilled, complete over the conjunctiva and "third eyelid," but imperfect as regards the central area of the cornea. At the first instillation there was evidently some irritation, for the lids were sharply closed and there was free lachrymation, but the spasm relaxed and the eyes were opened again in half a minute, when the palpebral reflex was found to be abolished. Complete anæsthesia was present after one minute had passed, when the vessels of the conjunctiva were slightly engorged, and there was a little myosis. In different animals the anæsthesia lasted from three minutes to as long as ten. If one instill three drops at a time three times over at intervals of one minute one causes a deep anæsthesia, extending over the

whole cornea, which may last as long as 20 or 25 minutes, but as there is apt to be desquamation at various points care must be taken to avoid this in practice. On comparing the results under precisely similar conditions of saturation, etc., in the two eyes of the same animal, using stovaïn on one side and cocain on the other, de Lapersonne finds the anæsthesia to be more complete and to last longer on the side on which stovaïn is employed. On the rabbit after instillation of stovaïn he found indifference when he proceeded to perform the operation for strabismus, but on the other hand there was evidence of pain when he attempted iridectomy. When he injected a 1 per cent. solution under the conjunctiva, and still more when he employed a 4 per cent. solution, there was very considerable hyperæmia induced, but there was also very complete anæsthesia; he was able to perform tenotomy, for example, without the animal showing any sign of uneasiness; there was certainly deeper anæsthesia than one obtains with cocain similarly used.

One of the laboratory officials into whose eye he instilled the solution, complained of pretty severe burning and discomfort, as from the presence of a foreign body; at the end of two minutes the conjunctiva was quite insensitive, but the cornea was not so. In six minutes sensation began to return to the eye, and a second drop caused a very considerable renewal of the burning, smarting sensation. Accommodation was interfered with a little, but tension remained unaltered.

Further, de Lapersonne has performed under the influence of stovaïn 18 extractions of cataract and 4 iridectomies or sclerotomies. The patients always complained of a feeling of smarting at the first instillation, and the vessels of the conjunctiva became injected; though the section of the cornea was not felt, the iridectomy was painful, and once or twice there was slight loss of transparency of the cornea. The after-progress of the cases indicated no evil effects. When performing four operations for squint the author injected a little of the stovaïn solution under the conjunctiva after instillation of cocain; anæsthesia came on rapidly, but the picking up and division of the tendon were certainly not quite free from pain.

In instillation, then, there is the disadvantage as compared with cocain that the introduction of stovaïn is always painful and the anæsthesia not so complete, but for subconjunctival use it is superior. The fact that the vessels become so much

injected points to rapid absorption, but stovaïn having but very feeble toxicity that matters little. The combination of cocain and stovaïn to drop into the conjunctival sac seems to produce an excellent local anæsthetic.

W. G. S.

---

A. Cantonnet (Paris). **Treatment of Glaucoma by Osmotic Substances.** *Archives d'Ophtalmologie*, January, 1904.

The author bases his reasoning on the statement that the elimination of lymph from the tissues precedes, and is analagous to, the process by which waste products are excreted from the body by the kidneys, and that when the function of the kidneys is diminished, extra work devolves on other excretory portions of the general system, which in most instances does not afford sufficient compensation. In such cases the molecular compositions of the lymph is altered and the chlorides increased, and in consequence more aqueous fluid is absorbed from the blood-stream, until the correct standard composition of the lymph is restored. The general result of this is to increase the total volume, which in turn gives rise to the formation of œdematous areas in the body. When the function of the kidney becomes re-established, the accumulated material passes from the lymph into the blood, and thence escapes from the body in the urine; the volume of lymph naturally falls and the œdema disappears.

The scheme thus outlined is intimately associated with the presence of chlorides in the body and the process of osmosis dependent on it, as well as with a certain selective affinity present in the cellular tissues. It is also pointed out that the eye and other parts of the body where lymph-fluid is present in distinct quantity, must be recognised as adjuncts of the general lymphatic system.

Acting on the foregoing assumption, the author tried the effect of inducing a polyuria and stimulating increased elimination of chlorides. The most satisfactory way found for realising this object was by the administration of sodium chloride, lactose, or other osmotic substances. The free action of the kidneys was ascertained by the preliminary use of methylene blue, and sodium chloride was then given in doses of 5 grammes daily, increasing to 10, and in one case to 15 grammes.

The principle was tried on a series of 17 cases of glaucoma. Some improvement in visual acuteness was noted, and in the field of vision; there was also decrease of pain. The nett improvement was not very marked in any of the cases, but as the treatment in all those quoted seems to be of recent date, scarcely enough time perhaps has elapsed for any definite opinion to be formed. The result in 12 of the cases is said to have been good, in two cases the condition remained stationary or indecisive, and the three remaining eyes were worse. Pilocarpine was also used, which was a good thing for the individual patients, though it somewhat confuses the issue and vitiates the results, considered from a purely experimental point of view.

KENNETH SCOTT.

---

L. HEINE (Breslau). **Congenital Cystic Retina.** *Von Graefe's Archiv für Ophthalmologie*, lviii., 1.

HEINE gives an account of two cases: the first was one in which the eyes of a markedly tubercular child showed clinically what was at first taken to be a persistent hyaloid canal, which in front radiated out to form a membrane continuous with the ciliary processes; the other case was one in which the globe on section seemed at first sight to present a similar condition or a retinal detachment. He describes the microscopical appearances in the second case with special attention to the retina, which is mostly adherent to the pigment epithelium layer: it also lines the central cord that runs from the lamina cribrosa forward to form a septum close behind the lens. In explanation of this condition he suggests that it arose from the fact that the anterior part of the primary optic vesicle, instead of being invaginated to form the inner layer of the secondary optic cup, had hypertrophied into a solid mass that tended to fill up the cavity of the primary vesicle: the outer layers of this solid mass gradually approached the future retinal pigment layer, while the inner layers kept close to the central vessels. The result was that they separated, and thus formed a cystic space which afterwards simulated (as he assumes in the first case) the vitreous chamber. But the application of this view to the clinical case seems hardly convincing, for the appearances in it, according to the description, point rather to his original diagnosis.

THOMAS SNOWBALL.

E. B. Coburn (New York). **Hæmorrhages in the Eye at Birth.** *Archives of Ophthalmology*, xxxiii., 3.

It has been known for some time now that hæmorrhages are to be found in the eyes of new-born children with a frequency which it at first somewhat astonishing. Königstein is stated to have found retinal hæmorrhages in 10 per cent. of cases, Schleich in about 33 per cent., Bjerrum 3 per cent., Montalcini 25 per cent., Naumhoff 25 per cent., Hippel 41 per cent., and so on. Coburn's motive of investigating this subject at the present time is to endeavour to ascertain whether such hæmorrhages could account for the poor vision which is sometimes present in eyes without any ophthalmoscopic alterations. Even the most zealous ophthalmoscopist is obliged to admit that there are such cases; it is true that there may be a slight stippling of the fundus in some of those eyes which is a little out of the usual, but this can readily be matched in other eyes whose vision is quite equal to the normal standard. One does not of course mean to imply that in no case which may fairly be labelled "amblyopia" can no minute change be found, but there is a residuum of cases in which that statement is true.

Though he indicates at the outset that the congestion of the head, the moulding of the cranial bones, and the average duration of labour are necessarily greater in primiparæ than in multiparæ, he brings no proof whatever that these hæmorrhages are more frequent in first children. Is there any evidence to show that amblyopia without fundus changes is more frequent in the first born of a family and in single children than in any others? The reviewer knows of none. Former observers have found the hæmorrhages to be most frequent about the posterior pole of the eye, but Coburn's experience was quite the opposite; in the majority of his cases the hæmorrhages were near the equatorial region. Of the hæmorrhages noted by various observers some were rounded and some striped, that is to say, some were deep in the retina or even sub-retinal, and others were in the nerve fibre layer. It is very rare to find hæmorrhage in the ciliary region, iris, or anterior chamber, and it is but seldom that it happens in the choroid, curiously enough. It is in the retina that the vast majority occur. By some observers no actual rupture of a vessel has been found on

microscopic examination, and it has therefore been concluded that some of these hæmorrhages have occurred by diapedesis; and one or two writers have endeavoured to have it accepted that such hæmorrhages are absorbed more rapidly than those by actual rupture—a contention which may be true but which must be somewhat difficult of proof.

Coburn had the opportunity to examine 37 infants who died in a maternity hospital, none of more than three weeks in age, and was struck by the very evident congestion of the fundus even in those eyes in which no hæmorrhages were observed, but some were complicated by further extravasations of blood in the optic nerve, in the nerve head, in the sub-retinal region and sub-hyaloid as well. As usual, the majority of these hæmorrhages were in the nerve fibre layer, and when they occurred deeper they were apt to be larger. Extravasations, he says, are more apt to occur in congenitally weak children; he does not think himself justified in blaming the use of forceps for the occurrence, for it is of course in difficult or long-continued labours that hæmorrhages are most likely to occur and that forceps are most likely also to be required. A further element which he regards as tending to cause hæmorrhages is the dilatation of the nerve sheath with cerebro-spinal fluid, and the consequent compression of the optic nerve and the central vessels of the nerve and retina. Coburn tells us that these hæmorrhages are more apt to occur among negro children, and—this we do not quite comprehend—among "subjects of hæmophilia." A woman is extremely rarely the subject of hæmophilia, and it is not in the mother's retina that the hæmorrhage occurs, while in the case of the child he certainly produces no evidence that any subsequently show themselves to be bleeders. His phrases are: "Subjects with hæmophilia or with hæmorrhagic tendencies should be regarded with suspicion, and birth should be facilitated as much as possible," and "persons of a hæmorrhagic diathesis are most susceptible to this form of traumatism." One cannot help thinking that there is some confusion of ideas here.

In regard to the question which was put at the outset, namely, whether such hæmorrhages may be the cause of the so-called amblyopia ex anopsia, or of congenital amblyopia, there is nothing in the paper which can help to solve the problem.

W. G. S.

W. R. Gowers. **Medical Ophthalmoscopy.** Fourth Edition. London: J. and A. Churchill.

This well-known book, which fills a niche whereto no rival can make any real pretensions, has now reached its fourth edition, and has been edited on this occasion by the author and by Mr. Marcus Gunn, as was also the third edition. Each of the two authors is of the highest standing in his own department, so that with this combination we have a work which, whether from the medical or the ophthalmological point of view, is of supreme value. Its importance, alike to the physician and to the ophthalmologist, can hardly be overrated. The former will be astonished to find in how many ways and in how diverse an examination of the fundus by a competent observer will assist his diagnosis, help to direct his treatment, clear up the pathology, and guide his prognosis, while the latter may learn from its pages the enormous value of patient examination under many conditions, of wide experience in clinical work, and of thoughtful classification and division. The book contains practically all that is at present known regarding the subjects under consideration, and no scientific physician or ophthalmic surgeon ought to be without it. The arrangement of the book is too familiar to need special reference here; it need only be mentioned that after a brief introduction the various changes in the different parts of the fundus are discussed; then follows Part 2, which deals with ophthalmoscopic changes in special diseases, and at the end are plates of pathological conditions of the fundus. These plates do not rival those in certain books on ophthalmoscopy proper, but they are not intended to do so, they have a different rôle.

There is one paragraph on which we confess we look a little askance, for a footnote says that Sir W. Gowers is alone responsible for it, from which we gather that Mr. Gunn will not commit himself to agree; it deals with a condition which Gowers calls chiasmal neuritis. He would be a bold man who said more than that he had not met with such cases as are described there, when Dr. Gowers has committed himself to their existence, but so far as that we may certainly go.

The book is pleasant to read, save only that there are in places too many footnotes for convenience.

J. M. Ball (St. Louis). **Modern Ophthalmology: A Practical Treatise on the Anatomy, Physiology and Diseases of the Eye.** Philadelphia: F. A. Davis Co., 1904.

This is one of the large books comparable to that of Fuchs. It is a royal octavo of 820 pages. Its most striking character is its wealth of illustrations. In this it is distinctly modern. With very few exceptions these illustrations are excellent, and a large proportion of them are new. They include 417 figures in the text, and 24 coloured plates showing 36 conditions of the fundus, and 40 coloured representations of disease of the anterior segment of the eye.

In the plan of the book the development and anatomy of the eye are first taken up. After these come chapters on the Physiology of Vision and the Examination of the Eye. Then follow the various diseases, and after them the anomalies of the muscular apparatus, errors of refraction, ocular manifestations of nervous diseases, preparations for ophthalmic operations, the hygiene of the eyes, and the methods employed in the microscopic examinations of the eye.

Six of the chapters have been prepared by other writers. The diseases of the lids have been elaborately described, largely from the point of view of the dermatologist. There is a good, brief description and a photographic illustration of Blastomycetic Dermatitis, which has recently attracted attention from ophthalmologists on account of its tendency to involve the lids, and the distortion it causes in them.

The bacteriology of the conjunctiva, amaurotic family idiocy, methyl alcohol amblyopia, excision of the superior cervical ganglion of the sympathetic for glaucoma, and many other topics, unnoticed or barely mentioned in the older books, receive adequate attention here. Recent contributions to operative and medicinal therapeutics are also well reflected.

On the whole this work is too elaborate and too expensive to meet the widest popular demand. But the breadth, accuracy and completeness of its presentation of the subject, and the character of its illustrations, make it a valuable addition to the working library of every specialist in ophthalmology.

E. J.

G. A. Berry (Edinburgh). **Manual of Practical Ophthalmology.** Edinburgh: Y. J. Pentland, 1904.

This "short and essentially practical treatise" is said by the author to give "expression to his individual experience as regards diagnosis and treatment." This indeed appears to be its *raison d'être*, for the writer's views which appear in the preface are that the latest developments in ophthalmology are not sufficiently extensive or important to call for an addition to the already large number of text-books on diseases of the eye.

The volume before us, containing some 565 pages, is concisely and clearly written and comparatively free from typographical errors. It is illustrated with great liberality and most of the illustrations are good; a few, as for example, Figs. 60 to 62, 103 and 121, would, we think, be difficult to diagnose without an accompanying description.

The greater part of this book will be familiar to those who know Berry's larger treatise; the arrangement in the smaller book is, we think, better than in its predecessor. The separate chapter on operations has been omitted and the operative treatment in each section follows the description of the disease. Also the chapter on the examination of the eye is placed at the beginning of the book, where it ought to be, instead of near the end.

It is to us a matter for regret that the author has, in this as in his former work, written so exclusively on the clinical aspect of his subject. A treatise on disease of any organ, in which so little attention is paid to pathology, does not seem attractive to us, and we doubt if it will prove so to students, most of whom display a commendable desire to know the anatomical conditions underlying the clinical signs of disease.

Among "recent developments" to which we have found no reference in this most recent of handbooks may be mentioned: the use of the X-ray examination for the detection and localisation of foreign bodies in the eyeball; the light treatment of rodent ulcer and other diseases of the eyelids; the hemiopic pupillary reaction; the use of suprarenal gland derivatives in disease of and operations on the eye; the newer preparations of silver so largely employed by many surgeons in conjunctival and lacrimal troubles; and the operative treatment of high myopia.

J. H. Parsons. **The Pathology of the Eye.** Vol. i., Histology. Part I. London: Hodder and Stoughton, 1904.

As Mr. Parsons admits in his preface, the time for discussing the pathology of the eye with "dogmatic finality" is not yet arrived. This statement applies perhaps with even more force to the wider questions which must come up for discussion in the succeeding volumes of his book. With regard to the microscopical structure of tumours, etc., it is open to question whether on present lines much that is really new has yet to be learnt, our knowledge being limited by the methods of examination at our disposal. But although Mr. Parsons does not pretend to dogmatise, his success in collecting and summarising the knowledge already gained and in assisting his readers "to winnow the grain from the chaff" should meet with widespread approbation. Doubtless the way has been partly smoothed for him by the publication of recent works, notably that of Professor Greeff, but none the less Mr. Parsons' work promises to be a great one, a monument to his industry, ability and critical judgment. The volume under consideration deals with the pathological histology of the lids, conjunctiva, cornea, sclerotic, iris and ciliary body. The bacteriology of the conjunctiva is also fully treated of.

The pathological conditions dealt with are described with great clearness and precision of statement, and in full detail. The copious literary references would by themselves make the work a very valuable one. In a work so excellent one hardly feels it necessary to make detailed comment on special portions. The bacteriology of the conjunctiva is handled in a way that will commend itself to the clinician as well as the worker in the laboratory. In treating of conjunctival degenerations Mr. Parsons takes pains to state in the clearest fashion what such terms as hyaline, colloid, amyloid exactly imply, which is of great moment, for such terms are apt to be used loosely and vaguely. In describing pinguecula and pterygium prominence is given to the views of Fuchs, who believes that the latter is but a later stage of the former. With regard to spring catarrh it is perhaps worth noting that in a recent paper Dr. Schieck* puts forward the view that the primary changes

* See page 259.

are in the substantia propria of the conjunctiva. Mr. Parsons appears to treat the disease rather as an epithelial change. In describing the anatomy of the cornea Mr. Parsons does not commit himself on the question of whether there exists a lymph stream through v. Recklinghausen's canals. A very complete account of arcus senilis is given. Mr. Parsons, from his own observations, agree with Takayasu that the opacity is due to fatty globules. He used Sudan III. and Scharlach R. as staining reagents and used frozen sections, avoiding addition of fat solvents, such as ether. The exact nature of the fatty deposit is yet undetermined, but it differs somewhat in chemical reactions from the ordinary fats. The accounts given of the healing of corneal wounds and of corneal inflammations seem admirable. When discussing cyclitis emphasis is laid on the work of Buchanan, of which illustrations are also given. In this volume congenital abnormalities are not considered. The book is profusely illustrated. In illustrating specimens from his own work Mr. Parsons confines himself to micro-photographs on the ground of absolute fidelity. We are not absolutely in agreement with him on this point as so much that may be beautifully evident under the microscope is obscured or lost in a reproduced photograph. Still the fact that photographs represent actual appearances and not the theories or ideas of any special observer must perhaps be considered of paramount importance. We congratulate Mr. Parsons warmly on his work, and trust that nothing may occur to prevent succeeding volumes from attaining the very high standard which he has set for himself.

---

E. H. Oppenheimer (Berlin). **Spectacles: the Theory and Practice of Their Use.** Berlin: Hirschwald, 1904.

In this country the ophthalmic surgeon has perhaps too little technical knowledge regarding the manufacture and preparation of the glass employed for optical ends. In this little book he will find described and illustrated all that he can desire to know—the history of spectacles, the various methods of grinding and polishing, the different merits of flint glass and crown glass, the points in the metal work of the frames, the measurement of the distance between centres, the height and projection of the bridge, decentration, bispherical, bifocal,

lenses, crossed cylinders, toric glasses. We do not know of any other work which covers exactly the same ground occupied by this treatise.

---

SCRINI (Paris). **Handbook of Ocular Therapeutics.** Paris: G. Steinheil, 1904.

IN this book is gathered together information regarding the various therapeutic agents used in ophthalmology, using "Therapeutics" in the wider sense to include certain instruments and operations, bandages, chloroform, leeches, artificial eyes and what not, besides the medicines proper both local and for internal employment. Advice and instruction regarding the use of these various agents is included in the scope of the book, which "on every page reflects the influence of Panas' teaching," as Lagrange says in the preface. This is only to be expected, as it is written by one of the disciples of that distinguished surgeon, and is indeed a précis of his teaching.

---

## CLINICAL NOTE.

LOCAL ANÆSTHESIA.—A method employed by Guttman (New York), of which he speaks highly, is based upon Schleich's infiltration plan. It is carried out thus: First one or two drops of a 4 per cent. solution of cocain or 1 per cent. holocain are instilled within three minutes into the conjunctival sac. Then a hypodermic syringe is filled with 25 or 30 minims of a solution containing, in 100 parts of distilled water, 0·2 parts of sodium chloride and 0·05 or even as much as 0·1 parts of cocain; a very fine needle is required. The upper eyelid is turned over and infiltration is begun into the retrotarsal fold, the lid being held in roller forceps. The process cannot be begun over the cartilage itself as the conjunctiva is there so closely adherent to the cartilage. If one is careful to keep the needle as superficial as possible no pain is experienced, and four or five drops can be injected. The wheal thus formed prevents the lid from returning to its normal position and forceps can be dispensed with. The needle is again inserted, this time in the first wheal, and a few drops injected, and so on till after some twenty drops are

used the whole conjunctiva of the upper lid is anæsthetic. It is very largely for treatment of trachoma that this method of anæsethesia is employed by Guttman, and he finds it to have this great advantage that it causes the trachoma granules to stand out very prominently and obviously in the œdematous infiltrated tissue. He finds that the use of the expression forceps is nearly painless if this precaution be taken. He has also used it for removal of chalazion. The chief point in which his method differs from that of some others seems to be in making his first injection in the retrotarsal fold.—*American Archives of Ophthalmology*, xxxiii., 3.

---

## OPHTHALMOLOGICAL SOCIETY OF THE UNITED KINGDOM.

The President, Mr. John Tweedy, in the Chair.

*Meeting held July 8th, 1904.*

### Card Specimens and Cases.

*Tuberculous disease of the Conjunctiva.*—Mr. E. J. Smyth.

The Conjunctiva in this case did not show very extensive or deep ulceration, but in one or two places fine gelatinous looking filaments hung down from beneath the upper lid. The conjunctival trouble had existed some time, but no operation such as scraping had been done.

*A case of Buphthalmos associated with a Congenital growth of face and upper eyelid.*—Mr. Rayner D. Batten.

The patient, a little girl, showed marked Buphthalmos of the right eye, and the same side of the face exhibited the peculiar appearance of plexiform neuroma in two masses. Apparently the facial growth had at one time been removed, but not completely, and it had gradually extended. The upper eyelid was much thickened, but soft in consistency.

### Paper.

*Lantern Demonstration on cases of Thrombosis of the Cerebral Vein.*—Mr. George Coats.

Preparations from five cases of thrombosis of the central vein of the retina were shown and described. In one case, although thrombosis was known to have taken place, the specimen did not show it definitely, owing to the optic nerve having been cut in the usual manner, *i.e.*, longitudinally, instead of transversely, as recommended by the writer. Of the other four specimens, all showed organized thrombosis of the central vein, and the optic nerve having been cut transversely for microscopical purposes the thrombus was very clearly made out. In three of these cases complete obliteration of the lumen of the vein in a portion of its course had occurred, and the thrombus had become organized. In one of these specimens the manner in which the lumen

becomes re-established by the dilatation of the collateral vessels from the trabeculæ of the nerve was clearly shown. In another specimen, instead of the thrombus becoming organized and completely obliterating the lumen of the vessel, it had become canalized, the surrounding wall with the canalized thrombus adhering to it giving the appearance of enormous thickening of the wall in contrast with the exceedingly small central opening.

The changes taking place in the walls of the retinal vessels in these cases could be divided into (1) endothelial proliferation, (2) thickening of the connective tissue of the walls, together with, in some cases, (3) hyaline degeneration in the thickening, and (4) secondary thrombosis. In both the arteries and the veins various combinations of all these changes might at times be found. The writer advocated the use of Weigert's stain for elastic tissue in the investigation of all changes in the vessels, pointing out in the drawings on the screen its extreme utility.

Dr. Knapp and Mr. Marcus Gunn made remarks on thrombosis of the retinal vessels relative to their clinical significance.

REGINALD E. BICKERTON.

---

# Bibliography.


## Anatomy and Physiology.

Seggel. The light-sense in myopes. *Arch. für Oph.* 59, 1
Zietzschmann. Tarsus in lids of domestic animals. *Arch. für Oph.* 59 1.

## Congenital Abnormalities.

Bergmeister. Congenital irideremia. *Arch. für Oph.* 59 1.
Dyson. Micropthalmos, with cysts in orbit. *Med. Gaz.*, July, and *Ophthalmoscope* August.
Toufesco. Congenital aphakia. *Ann. d'Oc.*, August.

## Hygiene.

## Pathology and Bacteriology.

Knapp. Pseudo-membranous conjunctivitis: influenza bacillus. *Amer. Arch. of Oph.*, July.
Wiener. New formation of elastic tissue in anterior chamber. *Amer. Arch. of Oph.*, July

## Instruments and Apparatus.

Berger. Stereoscopic binocular lens. *La Clinica Ocul.*, May.
Köhler. Rontgen rays in shot-wounds of the eye. *Berl. Klin. Woch.*, 34.

## Therapeutics.

Alvarado. Nitrate of silver in ophthalmia neonatorum. *Rec. d'Oph.*, August.
Claiborne and Coburn. Collargolum and antistreptococcic serum in infected wounds of eye. *N. Y. Med. News*, 6 August.
Foucher. Subconjunctival injections of salicylate of soda in rheumatic iritis *L'Ophtal Provinciale.* August.
v. Hippel. Tuberculin in tuberculosis of the eye. *Archiv. für Oph.*, 59 1.

## Operations.

Dupuy-Dutemps. Glaucoma following extraction. *Ann. d'Oc.*, August.
Hirschberg. Suction among the Arabians. *Cent. f. Augen.*, August.
Quackenboss. Choroidal hæmorrhage following extraction. *Amer. Arch. of Oph.*, July.
Todd. Extirpation of sac after injection of paraffin. *Amer. Arch. of Oph.*, July.
Wicherkiewicz. Glaucoma following extraction of cataract. *Ann. d'Oc.*, July.

## Traumatisms.

Businelli. Penetrating wounds of globe. *La Clinica Ocul.*, May.
Huwald. Bee-stings of the cornea. *Arch. fur Oph.*, 59 1.
Lewis. Foreign body six years in the clear lens. *N. Y. Med. Record*, 6 August.
Lewis. Triple rupture of choroid. *Oph. Record*, July.
Marple. Foreign bodies in the eye. *N. Y. Med. Record*, 25 June.
Noldecke. Unusual injury to eye. *Munch. Med. Woch.*, 31.
Villard. Burns of the eye by sulphuric acid. *Rec. d'Oph.*, July.

## Tumours.

Scott. Fibro-myoma of conjunctiva. *Amer. Arch. of Oph.*, July.

## Sympathetic Ophthalmia.

Ahlstrom. Sympathetic ophthalmia. *Cent. f. Augen.*, July.
Dunn. Sympathetic Ophthalmia. *Lancet*, 13 August.

## Glaucoma.

Dupuy-Dutemps. Glaucoma following extraction. *Ann. d'Oc.*, August.
Grandclement. Glaucoma and adrenalin. *Die Oph. Klinik.*, 20 August.
Wicherkiewicz. Glaucoma following extraction of cataract. *Ann. d'Oc.*, July.

## Amblyopia and Visual Defects.

Vallet. Amblyopia ex anopsia. *Rec. d'Oph.*, August.
Gibbons. Strong magnifying glasses in amblyopia. *Jl. Eye, Ear, and Throat Dis.* May

## Refraction and Optical Questions.

Fergus. Plastographic apparatus as test of binocular vision. *Ophthalmoscope*, August.
Harris. Binocular and stereoscopic vision. *Brain*, Spring, 1904.
Heine. Movement in stereoscopic images. *Arch. fur Oph.*, 59 1.

## Regional Affections.

## Eyelids.

## Lachrymal Apparatus.

Aubaret. Radical treatment of dacryocystitis of nasal origin. *Ann. d'Oc.*, August.
Todd. Extirpation of sac after injection of paraffin. *Amer. Arch. of Oph.*, July.
Zazkin. Congenital dacryocystitis. *Woch. f. Ther. und Hyg. des Auges.*, 46.

## Conjunctiva.

Alvarado. Nitrate of silver in ophthalmia neonatorum. *Rec. d'Oph.*, August.
Fukala. Trachoma among ancient Greeks and Romans. *Amer. Arch. of Oph.*, July.
Golescano. Prognosis of purulent ophthalmia. *Rec. d'Oph.*, July.
Johnston. Conjunctival symptoms in pemphigus. *Jl. of Eye, Ear, and Throat Dis.*, May.
Knapp. Pseudo-membranous conjunctivitis: influenza bacillus. *Amer. Arch. of Oph.*, July.
Salva. Pemphigus of conjunctiva. *La Clin. Oph.*, 10 August.
Scott. Fibro-myoma of conjunctiva. *Amer. Arch. of Oph.*, July.
Snell. Epidemic of acute ophthalmia. *Lancet*, 13 August.
Stephenson. Fatal case of diphtheria of conjunctiva. *Ophthalmoscope*, August.
Verboeff and Derby. Parinaud's conjunctivitis. *Amer. Arch. of Oph.*, July.

## Cornea and Sclerotic.

Fejer. Œdema of Cornea. *Cent f. Augen.*, August.
Fejer. Two rare forms of keratitis. *Cent. f. Augen.*, July.
Huwald. Bee-stings of the cornea, *Arch. fur Oph.*, 59 1.
Puccioni. Cytology of the aqueous humour. *Bull. d'Ott'Osp. oft.*, Rome, July.
Richter. Hemorrhage into cornea. *Die Oph. Klinik.*, 20 August.
Roure. Transitory affection of episcleral tissue. *Ann. d'Oc.*, August.
Schirmer. Keratitis disciformis. *Arch. fur Oph.*, 59 1.

## Iris and Ciliary Body.

Bergmeister. Congenital irideremia. *Arch. f. Oph.*, 59 1.
Bettremieux. Division of synechiæ. *L'Ophtal. Provinciale*, August.
Foucher. Subconjunctival injections of salicylate of soda in rheumatic iritis. *L'Ophtal. Provin.*, August.
Shute. Abnormal mobility of iris as a diagnostic sign. *N. Y. Med. News*, 30 July.

## Lens.

Aubineau. Ossification of the lens. *Ann. d'Oc.*, August.
Lacaussade. Cataract and glaucoma. *L'Ophtal. Provin.*, August.
Lewis. Foreign body in the clear lens. *N. Y. Med. Record*, 6 August.
Toufesco. Congenital aphakia. *Ann. d'Oc.*, August.
Woodruff. Bilateral dislocation of lenses into anterior chamber. *Oph. Record*, July.

## Choroid and Vitreous.

Joyce. Detachment of choroid. *Medical Press*, 27 July.
Lewis. Triple rupture of choroid. *Oph. Record*, Ju y.
Quackenboss. Choroidal hæmorrhage following extraction. *Amer. Arch. of Oph.*, July.

## Retina.

Gonin. Spontaneous detachment of retina. *Ann. d'Oc.*, July.
v. Hippel. A rare disease of the retina. *Arch. f. Oph.*, 59 1.
Hirschberg. Cyanosis of the retina. *Arch. f. Oph.*, 59 1.
Rochat. A chemical reaction of the retina. *Arch. f. d'Oph.*, 59 1.

## Optic Nerve.

Fleming. Optic neuritis: especially the microscopic changes. *Rev. of Neur. and Psych.*, August.
Knapp. Hereditary optic atrophy. *Amer. Arch. of Oph.*, July.
Konigshofer. Classification of forms of neuritis. *Die Oph. Klinik.*, 20 July, and *La Clin. Oph.*, 10 August.

## Muscles (and Strabismus).

Cosse. Strabismus. *L'Ophtal. Provin.*, August.
De Unicas. Paralysis of external rectus: neurotic heredity. *La Clin. Oph.*, 10 August.
Payne. Ocular muscles and refraction. *Amer. Arch. of Oph.*, July.
Stevenson. Test of latent power of convergence. *Oph. Record*, July.

## Orbit and Globe.

Carbone. Operation in cysticercus. *La Clin. Ocul.*, May.
Coulomb. New method of taking cast of orbit. *Ann. d'Oc.*, July, and *Rec. d'Oph.*, July.
Dennis. Orbital complications of empyema of frontal sinus. Treatment by superheated steam. *Amer. Arch. of Oph.*, July.
Reis. Abscess in lamina cribrosa in course of cellulitis. *Arch. f. Oph.*, 59 1.

## Relations with Medicine.

Chiarini. Ocular manifestations of malaria. *Boll. dell' Osp. oft. di Roma*, July.
Dana. Eye strain and psychoses. *N. Y. Med. News*, 30 July.
Dejerine and Thomas. Word blindness: autopsy. *Rev. Neurol.*, 15 July.
Flatau. Optic neuritis in paratyphus. *Munch. Med. Woch.*, 28.
Grasset. Conjugate deviation with hemianopsia. *Rev. Neurol.*, 15 July.
Holden. Eye symptoms of hysteria, &c. *N. Y. Med. News*, 30 July.
Kiliani. Tumour of the chiasma. *Annals of Surgery*, July.
Painblan. Ocular complications of variola. *L'Echo Méd. du Nord*, 31 July.
Pechin. Ocular manifestations in apoplexy in old persons. *Rev. d'Oph.*, July.
Pernet. Involvement of the eyes in epidermolysis. *Ophthalmoscope*, August.
Sachs. Relation of epilepsy, &c., to eye disease. *N. Y. Med. News*, 30 July.
Stolting. Can a dead cysticercus injure an eye. *Arch. f. Oph.*, 59 1.
Velhagen. "Sugar-loaf head" and optic atrophy. *Munch. Med. Woch.*, 31.

## Miscellaneous.

Coburn. Associated movements of eye and upper jaw. *N. Y. Med. Rec.*, 13 August.
MacDougall. Facial vision. *Amer. Jl. of Psychology*, July.
Swinerton. Massage by the blind. *Amer. Med.*, 6 August.

# A CASE OF PARINAUD'S CONJUNCTIVITIS, WITH PATHOLOGICAL REPORT.

By

J. W. Stirling, M.B., *Lecturer on Ophthalmology, McGill University;*

and

John McCrae, M.D., *Lecturer in Pathology, McGill University.*

Parinaud's conjunctivitis (or lymphoma of the conjunctiva as the German authorities call it) is a disease of which hardly any mention is made in the text-books. It is characterised by the appearance of granulations and large follicular masses on the palpebral conjunctiva, which rapidly increase in size, and also by the enlargement of the præ-auricular, infra-maxillary and cervical glands, which enlargement occurs at the onset of the disease or not long after. These glands may suppurate or may resolve. There is also a coincident rise in temperature each evening, which in our case on one occasion reached 103°, but for the most of the time hovered about 100·3°, the morning temperature being one to one and a half degrees lower. As a rule only one eye is affected. The course of the disease is not rapid, tending gradually to complete resolution.

This disease has to be diagnosed from trachoma, and from tuberculosis of the conjunctiva. From the former it is distinguished by the tendency to complete recovery, by the glandular enlargement and elevated temperature, and by the huge size of the granulations; from the latter by its complete curability, and the entire absence of any

ulceration, as well as by the lack of bacteriological proof of tubercle.

Goldzieher states that the swellings in the cheek and neck are not purely glandular enlargements, but new growths of lymphoid tissue. In view of this Dr. McCrae's accompanying pathological report is of much interest. The pathology of the disease being so obscure, one cannot but regret the lack of an experimental intraocular inoculation in an animal.

The patient first came under my notice on the 11th of November, 1903, at which time he had been suffering from an inflammation of the right eye accompanied by slight ptosis for ten days. For this he had been employing a collyrium of boracic acid and cold compresses, but the symptoms becoming more severe, he consulted me. The condition which I found was as follows: Marked swelling of both lids of the right eye with ptosis, lachrymation, and photophobia; on everting the lids the palpebral conjunctiva appeared much thickened and red; dotted over it, especially on the inner third, were many papillary granulations, which on the retro-tarsal fold were of large size; these closely resembled the granulations of acute trachoma; the ocular conjunctiva was also injected and irritable, but not chemotic; no false membrane was present, and vision was unaffected.

The diagnosis of acute trachoma was made provisionally, and a culture was made from the conjunctival secretion, which secretion was small in amount and muco-purulent in character.

For treatment I prescribed a collyrium of boracic acid and borax, an ointment of loretin, and the application of a 2 per cent. aqueous solution of nitrate of silver, once daily

to the conjunctiva. In forty-eight hours the granulations had greatly increased in size, and had pretty nearly covered the entire inner surface of the eyelids; the lids were much thickened and the ptosis very marked. Another culture was made from the conjunctival secretion and the same germ found as in the first culture. These cultures showed bacilli of irregular form, which were very suggestive of the Klebs-Loeffler bacillus. A mouse was inoculated from the culture and died in two days. A false membrane was found which contained many bacilli similar to those above mentioned.

A shield was applied over the sound eye and a 15 per cent. solution of argyrol was swabbed on the conjunctiva four times daily.

Some small ulcerated patches appeared on the pharynx, but cultures which were taken from them proved negative, as did also a culture taken from the nose. The ocular conjunctiva became greatly chemosed, and the pre-auricular and cervical glands began to enlarge; this was ten days after I first saw the patient. The temperature also began to rise each evening to 99·2°, and finally reached 101°, there being a morning remission. The complex of symptoms now caused a revision of the diagnosis, and trachoma was definitely excluded, the symptoms being clearly those of Parinaud's conjunctivitis.

Considering the symptoms, the bacteriological findings, and the apparent failure of local treatment to stay the course of the disease, I decided to try the injection of Roux's anti-diphtheritic serum. Twenty-five hundred units were administered, followed at twenty-four intervals by a second and a third. The main result noted was that the granulations became more succulent and soft, but the

glands continued to enlarge, and deep fluctuation was made out. Dr. Armstrong, being called in, advised excision, which was accordingly done by him. In the pre-auricular, sub-maxillary and cervical glands he found necrotic tissue, with a very small amount of pus. Dr. McCrae's report gives the pathological condition. A most remarkable amelioration of the ocular symptoms rapidly followed the operation, and within twelve days only a few of the larger cock's-comb granulations on the retro-tarsal fold persisted, these not finally disappearing until two months later. It is noteworthy that, although cultures were taken from the throat and nose, no trace was found of a germ resembling that observed in the eye.

A somewhat similar case came under my observation eighteen months ago, but unluckily disappeared before I completed the report; there were the same huge elevations on the inner surface of the eyelids of the right eye. There was a slight rise of temperature; it did not mount higher than to 100° F., and the pre-auricular gland was enlarged. Microscopical examination of one of the huge granular masses showed a lymphoid structure and the presence of a germ similar to that above described.

Of much importance is the pathological report by Dr. McCrae, which I append:—

November 12—Conjunctiva of right eye; cultures: pure, of a weak growth of a bacillus, slender, mostly $3 \times \cdot 75$m. in size, gram-positive, showing club-shaped and dotted forms, as well as straight and slightly curved bacilli. This was thought to be Klebs-Loeffler bacillus.

November 13—Pure culture, similar to the above, was again obtained. Its cultural characteristics were tested, with the following result: Gelatine, good growth, no

liquefaction; broth, turbidity, no pellicle; in litmus milk slight acid reaction was observed; in sugar bouillons no gas production occurred; growth on potato was very slight, the streak being rather faint, greyish-white and moist. The granules could not be stained, though tried repeatedly by Nissl's method, this being the only observable difference between the organism and true Klebs-Loeffler bacilli; it was observed, also, that some of the individual bacilli were very large, and the club-shaped forms were very readily demonstrable, even more so than the generally seen clubs of the diphtheria bacillus.

Inoculations into the subcutaneous tissue of the back of a brown mouse resulted in the death of the animal in 36 hours. The skin wound was closed by caked serum, no membrane being apparent to the eye. On the subcutaneous layer of muscle, however, a membrane was apparent, and on section this was seen to contain great numbers of the bacilli described above which lay upon the surface and in the membrane, but were not found in the deeper tissues. The organism could not be obtained by smear or culture from any other part or organ of the body. A guinea-pig inoculated in the skin of the back was dull and did not feed for 24 hours, but showed no membrane at the site of inoculation; the wound healed properly, and after 48 hours the animal was perfectly well.

November 17—Right eye: Pure culture as before. Throat: Cultures showed many streptococci, some staphylococci, no forms resembling the Klebs-Loeffler bacilli. Nose: Culture from the right side of the nose showed staphylococcus aureus, no bacilli resembling diphtheria.

November 25—Conjunctiva of right eye: Smears negative. Culture gave pure growth of the same bacillus

as before. Left eye: Smears showed no organisms, cultures gave staphylococcus in pure culture, no bacilli.

December 2—Conjunctiva of right eye: Pure culture of same organism as before, growing feebly and scantily.

December 7—Cultures from right parotid gland, Loeffler's blood serum. No. i. gave no growth of any kind; No. ii. bacilli, 4—5m. × 1m., not at all resembling the organisms in question, staining well, gram-positive; No. iii. scanty growth similar to No. ii.

December 7—Gland tissue from parotid region: Mass of tissue, measuring roughly 4 × 3 × 2cm., on section seen to be partly composed of parotid gland, partly lymphoid tissue, dotted throughout by yellow, purulent areas (abscesses); smears from these areas show pus cells, but no organisms, and sections stained by Gram's method show a few scattered straight bacilli in different parts which do not at all resemble Klebs-Loeffler bacilli and are in very small numbers; they cannot be made out definitely in the edges of the abscesses.

December 7—Conjunctiva of right eye: Pure culture, of feeble growth on blood serum, of same organism as before; the individuals are now mostly smaller in size, and in addition to the straight, curved, and dotted forms, are now to be seen a few diplo-bacillar forms, of which the outer ends are slightly narrower than the bases.

December 8—Conjunctiva of right eye: Smears negative. Guinea-pig inoculated with solid culture from blood serum was evidently ill for some hours, but after 42 hours was observed to be in normal health; slight scabbing without membrane at wound. Smears made upon the unbroken conjunctiva of rabbits were without effect upon the animal,

and the cultures from the conjunctiva 24 hours later failed to show any organisms.

*Summary.* Pure cultures of bacillus resembling Klebs-Loeffler bacillus found during 25 days of active treatment of the eye; this bacillus was not found in the other eye, or in the nose or throat. When the glands suppurated it was not found in the gland tissue nor in the pus, though the organism causing the suppuration was not determined.

In view of the cultural characteristics and morphology (with the single exception of the granules being not determined), this is evidently the Klebs-Loeffler bacillus, and yet when one considers that it is fatal to guinea-pigs it cannot be the generally recognised type of that organism. It fulfils the conditions which determine the recognition of that form of so-called pseudo-diphtheria bacillus generally known as bacillus xerosis, but this bacillus is recognised as innocuous in the eye, where it is frequently found. The bacillus, whatever its exact nature, was the probable excitant in the inflammation of the eye because it persisted in pure cultures through 25 days despite active local antiseptics.

Without entering upon the vexed question of the relationship or identity of B. xerosis and B. diphtheriae, we may state that we are dealing with either a virulent form of B. xerosis or a less toxic than ordinary bacillus diphtheriae. In either event the presence, persistence and evidently causal relationship to the clinical condition is an interesting fact.

## REVIEWS.

E. E. Henderson and E. H. Starling. **Influence upon the Intraocular Pressure of Changes in the Intraocular Circulation.** *Journal of Physiology*, 1904. Vol. xxxi., 5.

One of the authors, Mr. Starling, had been engaged upon an investigation into the factors determining the amount and composition of the intraocular fluid which is constantly being poured into the eye, but found his enquiries largely baulked by the uncertainty which existed regarding the dependence of intraocular pressure upon blood-pressure. For though a number of investigators have attacked this problem, they are by no means at one in their conclusions; indeed in some instances these are almost diametrically opposed. It was thought desirable therefore to subject this question to entirely fresh examination.

Practically speaking, all the previous observers have agreed on one point, namely, that the intraocular pressure follows more or less precisely the alterations of general blood-pressure in the absence of any local disturbing element. The two authors confirmed this by increasing the blood pressure in a dog and noting the increase in the intraocular pressure. Their first conclusion is that (1) the intraocular pressure is a function of the blood-pressure in the ocular blood-vessels, and varies directly as this latter. Their second conclusion is more precise, and states that (2) the intraocular pressure rises and falls with the general arterial blood-pressure, and is not appreciably affected by a certain degree of rise of pressure in the great veins.

The next point to be investigated was the relation of the sympathetic to the intraocular tension. It is acknowledged by all that the sympathetic brings vaso-constrictor fibres to the eye, stimulation of which can be directly seen to cause (in an albino rabbit, for example) constriction of the vessels of the iris and ciliary processes; division of these fibres produces only a transitory effect—a point of very great importance in relation to operation on the sympathetic for relief of glaucoma. The authors met, in investigating the action of the cervical sympathetic, with a certain source of error which had to be

guarded against; the sympathetic supplies twigs to the unstriped muscle of the orbit, and contraction of this might compress the globe and thus raise the intraocular pressure. The course of events is then somewhat like this:—In a dog used for the purpose stimulation of the sympathetic gave rise to no alteration of the general blood-pressure, but raised that within the globe; then the ocular tension began to fall and continued lowered for some time. When the stimulus was stopped the intraocular pressure began again to rise. As the nictitating membrane was observed to become retracted during the initial stimulation the authors concluded that contraction of the orbital muscle was in all probability the cause of the first rise. The constriction of the blood-vessels which occurs as a result of the stimulation comes on more slowly, and causes a diminution in the amount of intra-ocular fluid which leaves the blood-vessels. There therefore occurs a slow lowering of pressure; when stimulation ceases, the vessels again slowly dilate, and as they do so the intraocular pressure of course gradually rises again. Even after the death of the animal stimulation of the sympathetic is capable of causing a rise of pressure, and this is synchronous with the contraction of the nictitating membrane. It is thus seen that (3) stimulation of the head end of the sympathetic causes a preliminary rise of intraocular pressure, due to contraction of the unstriped orbital muscle, followed by a slow fall occasioned by contraction of the intraocular blood-vessels.

(4) Stimulation of the peripheral end of the divided root of the fifth nerve causes a rise of pressure which is due to contraction of the unstriated orbital muscle. This effect is absent if the fibres coming to the Gasserian ganglion from the sympathetic nerve are not in a physiological state in consequence of extirpation of the superior cervical ganglion having been previously carried out. The occurrence of the so-called trophic disturbances and of hyperæmia of the conjunctiva after destruction of the fifth nerve or after irritative lesion of the Gasserian ganglion, has naturally suggested the inclusion in the nerve of vaso-dilator fibres; it is held also by some that it contains secretory fibres for the intraocular fluids, and over this question there has been much warfare. The two authors came to the conclusion that the nerve contained no secretory or vaso-dilator fibres to the eye, or at all events none which could be stimulated

by means of an electric excitation of the Gasserian ganglion, for when they applied stimulus to the peripheral end of the cut nerve, no alteration in blood-pressure occurred, while the intraocular pressure rose at once, remained constant for a time, and then gradually sank, but without reaching, so long as any patient was kept under observation, its former standard. When the stimulation ceased the intraocular pressure came down to normal. In certain of the experiments it was noted that stimulation of the nerve as described caused retraction of the nictitating membrane and contraction of the orbital muscle (besides dilatation of the pupil). It became necessary therefore, in order to eliminate any error caused by implication of sympathetic fibres which are known to pass through the ganglion, to repeat the experiment after excision of the superior cervical ganglion and after sufficient time had been allowed for degeneration to be established. When this was done and when therefore stimulation of the Gasserian ganglion could produce no sympathetic effects, there was no change at all in the intraocular tension; under these conditions also stimulation caused no contraction of the orbital muscle or nictitating membrane, and no dilatation of the pupil. The authors point out that it is interesting to note that the path for the external unstriated muscles of the eye is similar to that of the dilator fires of the pupil, and differs from that of the vaso-constrictor nerves to the vessels of the eyeball. Their fifth conclusion is that (5) there is no evidence of vaso-dilator fibres either in the fifth or in the cervical sympathetic nerves. Previous statements to the contrary are probably based upon imperfections in the methods or technique of the experiments.

The authors made certain investigations also concerning the action of nicotin and adrenalin; these may raise the general blood-pressure, and at the same time constrict the peripheral arterioles, so that it is not surprising to find that in certain individuals the actual effect is different from what it is in others. In certain the general effect predominates and imposes its influence upon the eye, while in others the local influence is so great as to overmaster the general. There may therefore in any given case be either an increase or a lowering of the intraocular pressure.

W. G. S.

---

S. Holth (Christiania). **Skiakinescopy: A New Method of Estimating Ocular Refraction.** *Annales d'Oculistique*, June, 1904.

This method, which the author has called Skiakinescopy, is conducted as follows:—At a minimum distance of 4 metres the patient is asked to look at a circular point of light 5 to 10 millimetres in diameter having an opal glass disc in front of it. The trial frames are put on, and the eye which it not being examined is generally excluded, though this is not absolutely necessary. If no astigmatism has been shown by a previous examination with Placido's disc or the ophthalmometer the surgeon takes a darning needle of 1 to 2mm. in diameter in one hand, and holding it horizontally before the eye, moves it from below upwards across the pupil. If ametropic the patient sees a distinct horizontal shadow across the light, and this shadow moves upwards (*with* the needle) in myopia and downwards (*against* the needle) in hypermetropia. When the ametropia has been corrected by the insertion of the correct glass in the trial frame, the shadow disappears. If the patient is unobservant or lets his accommodation come into play, several glasses may seem to cause the disappearance of the shadow. Under these circumstances the strongest convex and the weakest concave glass indicate the correction. In some cases an ill-defined movement is noticeable even with the proper correction. In such a case the last glass which the patient recognises as giving a distinct shadow *with* and the first which produces a shadow *against* in myopia (and the reverse in hypermetropia) are noted. Then the intermediate glass between the two indicates the refraction. The author regards this method as quick and accurate and applicable to all sorts of people over the age of seven years.

In cases of astigmatism the process is not so simple, as it is indispensable that the needle be moved parallel with the principal meridians. These meridians must be found by means of retinoscopy, the ophthalmometer, or Placido's disc, or by means of the author's "*cherche-méridien*" (axis-finder). This instrument consists of a slightly reddened tube 1 to 2mm. in diameter—a vaccine tube will do—mounted in a disc with a central circular aperture across which the tube extends. When the astigmatic patient looks through this hole and tube at the source of light—preferably without the intervening opal glass—

he sees it elliptical and a thin red streak forms a prolongation of its long axis, if the tube is at right angles to the meridian of greatest ametropia. In all other positions the streak will form a variable angle with the long axis of the ellipse. In a slightly modified form the cherce-méridien is used in the author's skiakinescope—an apparatus by means of which, in addition to skiakinescopy, kinescopy, Scheiner's test, and the prisoptometry of Culbertson can be applied. For a full description of the skiakinescope the original paper must be consulted.

The phenomena mentioned above are easy to observe when the astigmatsim is equal to or more than 1·5° In lesser degrees it is necessary to determine the principal meridians by some other method, *e.g.*, retinoscopy, ophthalmometer or the fan. To be successful, skiakinescopy presupposes tolerably good vision, and a fair amount of intelligence on the part of the patient. It is not applicable in severe diseases of the macula and optic nerve, in toxic amblyopia, etc. It is sometimes of considerable value in estimating refraction in case of keratitis and irregular astigmatism, and applied with both eyes open it may help in exposing malingering.

J. Jameson Evans.

---

Ernst Fuchs (Vienna). **The Anatomical Changes in Choroiditis.** *Arch. für Ophthal.* Vol. lviii., part 3.

This paper is concerned principally with the changes which are met with in the choroid in association with inflammatory and other lesions which usually follow upon injuries. The investigation had its origin in the discovery in certain cases of plaques of fibrous tissue formation situated between the choroid and the sclera, and it is with the object of explaining the mode of origin of such cicatricial masses that the writer has studied the subject from various points of view.

The first part of the paper is occupied by a brief review of the literature of the condition which Prof. Fuchs prefers, and with reason, to call "endophthalmitis septica," usually termed cyclitis, hyalitis, etc. The author then proceeds to examine in some detail the facts in the anatomical investigation of such cases, and arrives at the following conclusions:—In the

majority of cases in which the choroid is involved in the inflammatory process, the extension of the action is from the vitreous through the retina. There are three exceptions to this rule, namely (1) those cases in which there is diffuse infiltration of the ciliary body; (2) those in which there is intense optic neuritis, in both of which the extension may be by continuity of tissue; and (3) the supra-choroidal space may be the site of inflammatory action set up probably by toxins. The toxins are probably conveyed to the supra-choroidal space, where they soon become diffused, from the posterior surface of the ciliary body. In cases in which the retina has early become separated from the choroid, the latter is less likely to be involved in the inflammatory action secondarily, than if the retina remained in position.

Regarding the plaques of thickening (Verdichtung) of the choroid, Prof. Fuchs finds that the formation of fibrous tissue in the supra-choroidal lamina is usually the result of long-continued but comparatively feeble irritation, where there is a serous exudation, and in cases in which there has been hæmorrhage between the choroid and the sclera.

The histological changes involved are described at considerable length.

The paper is illustrated by 21 drawings (Plates 11 and 12), and also by five figures in the text, and containing many thoughts which are both interesting and suggestive, is well worthy of careful perusal.

LESLIE BUCHANAN.

---

PARINAUD. **An Operation for Ptosis.** *Annales d'Oculistique*, March, 1904.

THE operation devised by Dr. Parinaud is suitable for all cases of paralytic ptosis, whether congenital or acquired. It leaves no external mark, and not only raises the lid to its normal height when the eye is looking straight forward, but provides perfectly for its elevation when the cornea is turned upwards, and allows the lids completely to cover the eye on their closure. It consists essentially in the passage of a thread in such a manner that the rawed upper edge of the tarsal cartilage is brought into contact with the superior rectus muscle, with the

result that eventually organic union between the two is established.

The details of the operation are as follows:—The upper lid is everted, and the superior border of the tarsal cartilage is seized by fixation forceps. A second pair of forceps, or better still a sharp hook, fixes the conjunctiva immediately above the cornea. The two are held apart by an assistant. An incision 12—15mm. in length is made through the conjunctiva close to the upper tarsal border, and the wound is deepened by scissors or by tearing until the tendon of the superior rectus is exposed, care being taken not to injure the conjunctiva of the fornix. The muscle is then raised by forceps and a thread armed with a needle at each end is passed through the surrounding capsular tissue. Traction on the thread, if correctly passed, will cause rotation of the globe downwards. In case of any doubt as to the whereabouts of the muscle, the passage of a strabismus hook under it will clear it up. The next step is that the forceps attached to the tarsus is taken by the operator and a narrow strip, 5—6cm. long, is removed from the upper border of the tarsus. Both needles are passed through the upper cut border of the conjunctiva, through the tarsus close to its raw edge and eventually out through the skin about 4mm. above the free border of the lid and some 6mm. apart. Very little conjunctiva should be included in the loop, indeed it is not absolutely necessary to catch it up at all. The ends of the suture are tied loosely over a small roll of lint and are left long so that they can be tightened or loosened further if necessary. On the fourth day the threads are untied and the effect estimated. The suture is withdrawn altogether on the sixth to the eighth day. The operation can be performed on the adult without chloroform. It is simple, but the chief difficulty is the finding of the muscle without injury to the conjunctiva. The search can be facilitated by the injection into the tissues of a few drops of sterilised water or a weak solution of cocaine. It is not even absolutely necessary to raw the edge of the tarsus. If the thread is tied tightly at first the effect on the elevation is apparently excessive. Formerly Dr. Parinaud in such cases released the thread on the second day, but does not now do so even though the effect is twice or thrice as much as is permanently desirable. The patient himself by the efforts of the orbicularis can, after the thread has been withdrawn, bring

the lid down sufficiently to close the eye; or if this is not possible at first, stretching of the bands of adhesion can be accomplished by repeated attempts to look up; the insertion of the rectus goes further backwards than the mass of the lid can follow. Failing these natural methods the lid can be forcibly drawn down if seized by Desmarre's chalazion forceps.

Dr. Parinaud considers his operation superior to any other method of connecting the tarsus and the superior rectus, such as by a strip of the tarsus itself, because he asserts the position of the lid is regulated to a nicety by the natural efforts mentioned above.

J. Gray Clegg.

---

Pansier (Avignon). **Collectio Ophthalmologia Veterum Auctorum.** Paris: Baillière and Fils.

This book is full of interesting and instructive matter, and is admirably brought out by the publishers. The history of ophthalmic work from the earliest times, as set forth in the writings of the most distinguished authors of bygone days, is presented in an attractive form. The materials have been skilfully handled, and the selections, which are exhaustive in character, are carefully arranged. The whole work is evidently the result of long and comprehensive research, and, although the busy ophthalmic surgeon of modern times may not succeed in finding therein suggestions for the more successful treatment of his patients, we can recommend this work to all those who take an educated interest in the ancient literature of ophthalmic science.

---

Felix Lagrange (Bordeaux). **Tumours of the Eye and Orbit.** Vol. ii., "Tumours of the Orbit and the Appendages of the Eye." Paris: G. Steinheil, 1904.

This is the second volume of a large work on tumours of the eye, orbit, and appendages. In the first volume, which appeared some time ago,* the following subjects are dealt with in parts one to five:—(1) Tumours of the bulbar conjunctiva;

* A review of Vol. I. appeared in this Journal. 1902, p. 19.

(2) Tumours of the sclerotic and cornea; (3) Tumours of the uveal tract; (4) Tumours of the retina; (5) Pseudo-tumours of the eye. The present volume, comprising parts six to ten, is arranged under the following headings:—(6) Tumours of the optic nerve; (7) Tumours of the orbit; (8) Tumours of the lachrymal apparatus; (9) Tumours of the lids; (10) Tumours which invade the orbit from neighbouring structures. The subject of pulsating exophthalmos is given a place in the section devoted to tumours of the orbit. A prominent feature in the book is a bibliography of the published cases of rare forms of disease in the form of a concise tabulated account of each case which adds greatly to the usefulness of the work as a book of reference. Both the clinical and anatomical aspects of the subject have received attention. Here and there the author has introduced notes of his own observations, and has added to the literature a number of his valuable cases. There are many excellent plates and figures in the text. With this volume the author has completed an estimable treatise containing a vast amount of information laboriously gathered together over a period of many years.

---

GRANDCLÉMENT (Lyons). **The Value of Adrenalin in Glaucoma.** *La Clinique Ophtalmologique*, 12, 1904.

ADRENALIN is capable, in the opinion of Grandclément, of accomplishing what no other drug has the power to do, viz., of curing glaucoma without operation, and this result is not limited to cases of primary glaucoma, but extends even to those in which the increase of tension is secondary. Four conditions however, are absolutely essential to success, viz., (1) the glaucoma must be recent; it must not have had time to produce organic lesions either in the ciliary body or iris, and certainly not in the angles of the anterior chamber; (2) the adrenalin must be instilled into the eye every half hour without any interruption whatever for perhaps three days, until the tension has gone down. It is generally considered that in the treatment of glaucoma peaceful sleep is an important consideration, a fact which may be related to the prolonged contraction of the pupil which then occurs, but Grandclément's patients can have little chance of this; (3) the third *sine-quâ-non* seems more suspicious still, for it seems that eserine must be employed along with the

adrenalin, in order to combat the two principal causes of the process of glaucoma, to wit, on the one hand the hyper-secretion of aqueous humour by the congested ciliary body—the task which adrenalin has to accomplish,—and on the other hand the failure to excrete on account of the obstruction in the angle of the anterior chamber; this it is the function of eserine to combat by its action in drawing the iris away from the angle of the chamber and so opening up the spaces of Fontana; (4) lastly, it is essential to cease, or at least to reduce, the employment of adrenalin so soon as the tension has come down to normal, lest a permanent condition of lowered tension should result. The action of adrenalin as a vaso-constrictor is powerful but transitory, hence the necessity for frequent renewal of the application, but since its over-employment seems capable of inducing organic changes of the nature of atheroma in the large vessels—a fact which has led some to attribute arterio-sclerosis to an over-activity of the suprarenal bodies—one ought not to allow its reckless and continued use.

The first case which drew Grandclément's attention to the risk of producing undue lowering of the tension was that of a young man suffering from a persistent hyperæmia of the conjunctiva. Solely in order to cut short the hyperæmia, and without any thought of lowering the tension, which indeed was not increased, he employed frequent instillations of adrenalin. Presently the patient complained of failure of vision, and the eye was found to be alarmingly soft. Although the drug was at once cut off, it was six months before vision was again normal and before the tension had risen to its proper height. This alarming occurrence had at least this good effect, that it brought prominently before Grandclément's mind the great possibilities of adrenalin in the event of tension being pathologically raised. He resolved that in the next suitable case which presented itself he would give a thorough trial to adrenalin alone, and one soon was found. The patient was a woman of 37, who exhibited all the classical symptoms of subacute glaucoma, after a series of premonitory attacks. She obstinately refused to undergo any operative treatment, so that Grandclément, thus happily rendered "tranquille au sujet de sa responsabilité," seized the opportunity to make a thorough test of the value of adrenalin with eserine. In the first place, in order to prevent subsequent uncertainty, and although fully

convinced of the total inability of eserine by itself to cure such a case, he employed that drug alone for thirty-six hours; the result was absolutely *nil*. He then instilled every half hour day and night, as above indicated, drops of

| | |
|---|---|
| Adrenalin (1–1000) | 3·00 grammes. |
| Eserine | ·05 grammes. |
| Water | 10·00 grammes. |

After two hours pain began to diminish considerably; after ten hours hand movements could be perceived; after twenty-four hours the patient could guide herself with that eye alone. By the close of the third day she had recovered a large amount of sight, and tension was reduced even to a degree slightly below normal. The frequency with which the drops were used was therefore considerably diminished, but they were not left off, lest a recurrence should take place. At the end of a week vision had risen to two-thirds of normal, and the patient was considered definitely cured; even some months later it remained at that high level. During the first month, it is true, she had occasional slight returns of the rainbow, but this symptom yielded at once to a few instillations of the collyrium mentioned above.

Having thus treated this case successfully and the patient having remained well for five months, Grandclément is very hopeful that this method may enable a surgeon to avoid operation much more frequently than he at present does. He does not, however, even affect to consider that in old-standing cases the operation can be avoided, but he trusts that as knowledge of this method spreads more cases may be treated correctly from the beginning by the patients' own attendants, and so not become sufficiently severe to demand surgical interference. Even when operation has been demanded by the state of affairs, and has been performed, eserine and adrenalin have their function in keeping up and maintaining the good effect, and confirming the cure. It is not only in pure glaucoma that adrenalin appears to be useful, for Grandclément found it of great benefit in the case of a child of four years suffering from buphthalmos, which is regarded as a congenital form of glaucoma. In both eyes of this child, after treatment for six months with the combined collyrium, there was no question that vision was greatly improved; the tension, however, had not come down to normal.

Given, then, the conditions mentioned at the beginning of this article, Grandclément is firmly convinced of the high value of the combination of eserine and adrenalin in glaucoma, and even claims that by its means a permanent cure may be established and operation in many instances avoided. The reviewer does not wish to throw cold water upon his hopes, but one ought to remember that in glaucoma which has produced "no" structural changes (his first proviso) there are often very long remissions, and indeed a patient may have only one attack, recover under eserine or otherwise, and live many years without a second. It is not easy either to understand how a vaso-constrictor whose action is so temporary, can, even when instilled many times, produce a permanent cure when it does not really strike at the root of glaucoma. However that may be, it is well to remember that as a temporary measure the use of adrenalin may be of great service.

W. G. S.

---

S. Snell (Sheffield). **Eye Strain and Headache.** London: John Bale, Sons, and Danielsson, 1904.

Mr. Snell publishes in extended form an address which he delivered some time ago before the York Medical Society, dealing with eye strain and headache. In it the familiar facts are gone over, and a series of illustrative cases related. The sentiments of the patients are in some instances related at undue length, in our opinion; indeed some of the descriptions which they give are suggestive of extracts from the advertisements of some quack medicine. This may be all very well in an address to a society, but we think Mr. Snell was ill-advised to publish such matter *in extenso;* it can serve no good end. The book, we presume, is intended for perusal by ophthalmic surgeons, and we are all familiar with these hysterical accounts of distress relieved by suitable glasses, the pains being never so severe as when they are looked back upon. His main thesis, with which we have no quarrel, is that the so-called eye strain may be responsible for certain symptoms which have at first sight no obvious direct connection with the eye.

Giuseppe Grilli (Rome). **Cryoscopy and the Pathology of Senile Cataract.** *Recueil d'Ophtalmologie*, June, 1904.

To discover the cause of senile cataract has long been the dream of the ophthalmic surgeon. The author of this paper has been in the custom of analysing the urine of each patient in Parisotti's clinique before operation for cataract, and has been struck by certain constant characters which have come under his attention in the course of this duty. In order so far as possible to exclude sources of error, he has made careful comparisons, chemical microscopic and cryoscopic, of the urine of a series of cataract patients and of a series of normal persons. The points specially noted in the urine of the cataract patients have been low specific gravity, a relatively increased flow, comparative freedom from sedimentary deposits and absence of retinal elements therein, and a lowered osmotic tension. It was only after prolonged investigations that Grilli came to the conclusion that these differences, which at first he regarded as accidental, might have a real causative indication.

Since the method known as cryoscopy, its terms and its indications, are of very recent introduction and may not be too familiar to all ophthalmologists, the reviewer thinks it may be well here to indicate very briefly, from the writings of others, what these signify. Cryoscopy deals with the determination of the freezing point of the blood and of the urine particularly. The freezing point of the blood is extremely constant, for while its range of variation is only from ·55 to ·57 of a degree centigrade, the specific gravity may vary from 1046 to 1057. It is customary to use the symbol $\delta$ for this, and to write $\delta = -0{\cdot}55$, which means that the freezing point of the blood is by that amount lower than the freezing point of distilled water. Similarly the symbol $\Delta$ is used for the freezing point of urine, which varies from $-0{\cdot}9$ to $-2{\cdot}0$ below that of distilled water; it may vary from time to time during the twenty-four hours. The information gained by means of cryoscopy is not the same as that obtained by the specific gravity bottle, but deals with the molecular concentration or "osmotic pressure." When one observes that the specific gravity of the blood may vary so widely while the $\delta$ varies only so minutely, it is evident that some very essential health relation must surely be involved in the restriction being kept so narrow.

Dr. Knott, a well-known physicist, explains that "the depression of the freezing point is due to the need for work being done (in the act of freezing) in pushing out the molecule of the foreign substance held in solution;" while from the clinical side a depression in the freezing point of the blood indicates deficient excretory power on the part of the kidneys. (We must not be understood to say that this is the only possible cause, but for present purposes at any rate the statement is true enough.)

After this brief outline of the essentials of cryoscopy we may revert to Grilli's paper; he found a low osmotic tension, $\Delta$ being on an average $= -1{\cdot}10$ and the other characters mentioned above, in 80 cataract patients; the average of $\Delta$ for a number of healthy persons was $-1{\cdot}65$. These features suggested a condition of partial atrophy of the kidney, of chronic interstitial nephritis, or sclerosis of the kidney as it is sometimes called. But is it right to assert that all patients with cataract have sclerosis of the kidney, and if so, how is it that other indications of arterio-sclerosis are not present? It has of course long been a theory that arterio-sclerosis, whether local or general, has a marked effect in bringing on cataract. Atheroma of the carotid arteries is a condition not uniformly present in cases of cataract, but it is quite frequently so. Arterio-sclerosis is not necessarily uniformly distributed when it is present; it may affect kidney and not liver, for example, it may even affect only certain parts of an organ and leave other parts free. In answer then to the question, If arterio-sclerosis be the cause of cataract, why does cataract not attack all those who suffer from arterio-sclerosis, the answer is that unless the kidney is definitely affected cataract will not be manifested.

Grilli remarks, however, that he does not lay it down as a rule that all patients with cataract are sufferers from actual kidney mischief. Certain writers describe a condition of "senile kidney," which may probably be a manifestation of arterio-sclerosis affecting the kidney, in which, in particular, the proportion of urea is low, as well as of other effete matters. This condition, with which Grilli has met also in old persons not affected by cataract, but always to a less degree, agrees very well in clinical facts with the cases which he has lately been watching on behalf of Prof. Parisotti. Recent work,

however, in cryoscopy and in the significance of the presence of chlorides, which he has almost invariably found diminished in quantity, have seemed to him to indicate the line along which to look for the explanation of the origin of senile cataract. Observers have been, in Grilli's opinion, too much disposed to search in the eye itself alone for the cause, too much taken up with questions of minute histological alterations, etc., and have not given sufficient weight to the questions of nutrition in general. To this M. Frenkel is, he says, an honourable exception, for he has devoted considerable attention to renal permeability in connection with this very matter, experimenting chiefly with methylene blue. Leber and Hess among others appear to regard the processes of nutrition of the crystalline as being determined by diffusion, but in the opinion of Ovio osmosis plays a much more important rôle. If this be so then one must regard not merely the aqueous humor, but the fluids of the vitreous humor also and of the peri-equatorial lymphatics (Petit's canal) as contributing to the nourishment of the lens. These considerations then all point to the importance of the kidney condition. Numerous observers have shown that $\Delta$ in the case of normal persons is always about $-1{\cdot}65$, more or less, while in renal sclerosis it may be $-0{\cdot}56$, and substances will be retained in the blood which under ordinary conditions would have been eliminated. Taking it for granted then that the osmotic tension of the blood is thus raised, that of the lymph and intraocular fluids will certainly be raised as well, since these have their origin in the blood. The effect of this upon a lens will be that fluid will be extracted from it to pass into (say) the aqueous, while, as in experiments made for the purpose of investigating these matters, if the fluids be more attentuated, fluid will pass into the lens matter.

Peters and Troncoso, among others, have found the aqueous humor in persons suffering from cataract to possess an amount of diffusible substances in excess of the normal. The effect of this will be dehydration of the lens, which is exactly what Grilli finds to be the fact.

Deutschmann and others have shown that in senile cataract there is a formation of vacuoles and a slight separation between the nucleus and cortex, and Becker has shown that fluid does escape from the fibrils of the lens and tend to accumulate. Grilli considers it probable that these vacuoles are simply filled

by fluid on its way from the tissue of the lens to escape into the anterior chamber by osmosis through the capsule of the lens. It is a point at least not against this theory that cataract is more frequent, as is well known, in those whose work exposes them to great heat, for example in glass-blowers, for the extreme perspiration induced by the circumstances of their labour will naturally tend to increase the osmotic tension of the blood and other fluids. The same is true of the cataract of diabetes, whether it be due to the actual presence of sugar, or less directly to the inefficient removal of waste matters from renal inadequacy or heart weakness.

To put the whole matter concisely, Grilli's view is that from insufficient elimination of solids *via* the kidneys, and the consequent rise in osmotic tension, to be found in presence of "senile kidney," in the blood and in the fluids which owe their origin to the blood (*e.g.*, the aqueous humor), the lens, which is under normal conditions nourished by means of endosmosis, being now surrounded by fluid of increased osmotic tension, is obliged to yield up some of its fluid and is consequently "dehydrated;" this then produces cataract.

W. G. S.

---

D. Bossalino (Pisa). **Bacteriological Examination of the Conjunctiva in Patients Suffering from Cataract.** *Annali di Ottalmologia*, xxxiii., 3.

A phrase employed by Axenfeld in a recent paper has caused Bossalino to undertake a careful inquiry along this line. This phrase is, or rather these two statements are, that the tissues of the eye offer a relatively greater resistance than other structures to the attacks of micro-organisms, and that only when pneumococci are present in the conjunctival sac is it necessary on bacteriological grounds to postpone operation.

Everyone of course is aware that even in a normal state the conjunctival sac contains micro-organisms, but differences of opinion exist regarding the importance of various organisms which are frequently to be found in the sac in regard to the membrane itself and to the complications likely to arise after operation or other trauma. As a preliminary measure Bossalino passes in rapid review the knowledge we at present

possess in regard to this matter. He mentions the investigations of Gallenga (and of others), who showed that in a number of cases it was more than probable that the organisms (bacilli, staphylococci, etc.) present in the conjunctival sac had reached there from the secretion of the Meibomian glands; they have been found there even when the lachrymal secretion was sterile. In 87 examinations of the conjunctival sac in 57 persons, Fick found only six sterile. In the great majority he found bacilli, frequently associated with cocci; he never found cocci alone. Out of these 85 eyes, 37 were affected with chronic catarrh of conjunctiva. In another series of examinations he found germs of various sorts in 18 out of 50 "healthy" conjunctival sacs, and classifies the organisms found under such circumstances into four groups, viz., (1) those capable of giving rise to a specific form of inflammation if introduced into a conjunctival sac, *e.g.*, the gonococcus and the trachoma coccus; (2) those capable of acting similarly when there is a local loss of epithelium, *e.g.*, the tubercle bacillus and the staphylococcus aureus; (3) those which may remain in a conjunctiva, whether normal or pathological, without giving rise to any indication; and (4) those which are incapable of living or thriving there, and are carried away by the lachrymal secretion.

The author next proceeds to recount briefly the results obtained by other observers in various countries. Of these we may mention the conclusions arrived at by Wolkowitsch, working in the military hospital at Kieff. He finds that in the normal conjunctiva pathogenic organisms do not exist, that among those found the coccal form is the most frequent, that the season of the year is a potent factor in determining what organisms may be present—for example, the bacillus subtilis was frequently to be found in spring, and only then; that by means of microscopic examination he could demonstrate the presence of organisms in 70 per cent. of cases, and by means of plate cultures in 90 per cent.; that on different occasions the same conjunctiva might supply different organisms; and that the majority of the organisms found were only there by chance so to speak, and ought not to be regarded as regular inhabitants of the conjunctival sac. In the conjunctival sacs of sixty persons suffering from catarrhal conjunctivitis, Hirota found organisms in fifty-eight, and of forty normal individuals thirty-eight showed organisms also. He found that the most

frequent organism was a form of staphylococcus, but hesitated to regard it as the cause of the conjunctivitis, for the same was found with equal frequency in the normal conjunctivæ; this was true also in regard to the frequency in both groups of streptococci and pneumococci.

But it was not so much to determine the relative importance of the organisms present during a pathological condition of the conjunctiva that was Bossalino's intention; rather it was the investigation of the question whether a conjunctival sac can be rendered aseptic, and, if the answer should be in the negative, what importance one ought to assign to such organisms as survive the treatment customarily applied to the field of operation before and at the time of such a procedure as extraction of cataract. Bernheim has already attacked this problem; he used a culture of staphylococcus pyogenes aureus, and found that after that had been introduced into the sac it was impossible to render the membrane again completely sterile by the use of antiseptics, but certainly the growth and multiplication of germs could be, and were, thus greatly diminished. He seems to consider that the tears have a moderate or incomplete antiseptic power against staphylococci. It was shown clearly a number of years ago now by Valude and others that the bactericidal power of the lachrymal secretion is not more than slight, but that it is a bad culture medium, and organisms, if they live in it, at least do not thrive; they lose vitality if not life.

As regards the possibility of rendering the conjunctival sac aseptic, the work of Gifford is of value, demonstrating as it did the want of absolute success in this direction; the number of organisms can be reduced, and sometimes greatly reduced, so that what one might call approximate sterility is attained to, but complete and final asepsis is not secured. Carapelle, it is fair to say, however, believes that this attempt may under some circumstances be successful, but the majority of writers do not concur in this view.

To turn to Bossalino's own experiments, he made cultures from the conjunctival sacs of all patients (18) operated on for cataract during a certain period of time in the Clinique at Pisa; these were made in the usual way in agar-agar and in glycerine-agar, the platinum loop being swept over the conjunctiva from one to two days after the operation, which

was always conducted along careful lines. When no actual discharge was picked up on the loop, the thread was introduced again into the most probable area of infectiveness, namely, the lower cul-de-sac towards the inner side. In all the cases the operation was successful, and there was no serious complication of any kind; yet in every instance save one there was absolute proof of the presence of organisms. Thus in these seventeen cases staphylococcus albus was found fourteen times, staphylococcus aureus four times, and so on.

Approaching the subject by another route, he made a wound in the cornea of a rabbit, and introduced a few drops of a pure culture from the eye whose condition he desired to examine; there was considerable reaction for a time in each of these "cases," but the symptoms gradually passed off without any bad result. He tried similarly with the abdominal cavity of the guinea-pig, and here again the result was negative; there was no sign of uneasiness after a few hours, and in fact there were no symptoms produced at all. He made special investigations in the case of one patient who suffered from an old-standing dacryocystitis. The sac was excised, and later the cataract was extracted, with an excellent final result. Two days after the extraction the bacterial condition of the conjunctival sac was tested. In all the cultures there was a copious growth of aureus, and much less of the albus. Several experiments with this staphylococcus aureus all proved futile, that is to say, it appeared to have no serious pathogenic properties, but the culture seemed to recover its injurious nature after having passed through the body of an animal, for a culture taken from the œdematous area surrounding a skin wound made and infected, proved capable of killing a guinea-pig in twenty hours when it was injected into the peritoneal sac, and yet before this was done cultures specially made showed that no other organism had become mixed up with the staphylococcus—it was a pure culture.

Up to a certain point then Bossalino's results are confirmatory of those of Axenfeld, who regards the pneumococcus alone as of grave importance among the organisms found in the "normal" conjunctiva, the others being of little or no importance; this may be because the ocular tissues are endowed with a higher resisting power than other structures, but experiments have convinced the author that organisms taken from the conjunctiva

of the operated eye are not pathogenic, not as regards that eye only, but as regards the other also, and even as regards subcutaneous tissue and the peritoneum. If he is correct, then the resistance of the eyes is not due to a greater resisting power on the part of their tissues, but to a loss of virulence on the part of the bacteria. All are agreed even now that the use of an antiseptic lotion diminishes the actual number of organisms in the conjunctival sac, but it is not universally recognised that the pathogenic action of the surviving germs is also reduced thereby; this conclusion, reviewing the effect of his investigations, Bossalino feels himself obliged to maintain.

W. G. S.

---

Otto Bruns (Heidelberg). **On the Experimental Production of Inflammations of a Phlyctenular Nature through the Action of Dead Tubercle Bacilli.** *v. Graefe's Archiv für Ophthalmologie*, 58, 3.

This paper gives a careful account of some experimental work of the author's on the lines suggested by Prof. Leber.* After a short summary on the work done in this connection with live bacilli, the author relates with care the results which have been produced in other parts of the body by the use of the dead organisms. He notes that dead tubercle bacilli can produce a nodule of very similar structure to the miliary tubercle, and that in this the organisms may retain their characteristic staining reactions for months. No generalisation of course takes place. As to the occurrence of caseation some difference of opinion exists.

The author divides his experiments into two groups—(1) the injection of sterilised tubercle bacilli into the rabbit's cornea; (2) the injection of dead tubercle bacilli, with or without the addition of some inert material to form an embolus, into the arterial system of the rabbit. The technique of preparing the cultures and the methods of injection are carefully gone into. Controls were used to test the sterilisation of the cultures. By the first method no appearances closely

* Th. Leber, Ueber die phlyctanulare Augenentzündung. Bericht über die 29te Versammlung der Ophthalmologischen Gesellschaft, Heidelberg, 1901.

resembling phlyctenules were ever observed, but for all that the results were of some interest, as showing how very closely the action of dead organisms may resemble that of the living. The author never met with any caseation, but has seen some evidence of necrosis. He gives it as his opinion that the action cannot be considered merely mechanical, but must be due to some chemical influence exercised by the germs.

The experiments in the second series were more successful. In order to reach the external part of the eye it is necessary to introduce the material into the external ophthalmic artery, a branch of the internal maxillary, but as neither of these arteries is easy to get at, the author selected the external carotid after previous ligature of the internal. In all thirty-three experiments were made. Seven animals died from various causes before any manifestations had time to appear; in ten the eye was lost through embolism of larger vessels and necrosis, while in six no result followed so late as up to three months after injection. In 50 per cent. of the remainder appearances that resembled phlyctenular conjunctivitis, both anatomically and clinically, were observed. The author gives a minute description of the clinical and microscopical appearances of these cases. He sums them up as follows:—"After several days, with some preliminary conjunctival injection, there appear suddenly in the conjunctiva one or more small nodules. A favourite site is the limbus, just outside the pigment ring, but they have also been found at the seat of the muscular insertions and in the fornix. They show a clear prominence, and are somewhat transparent, so that they resemble vesicles. The neighbouring vessels are much enlarged. After ten to twenty days they begin to subside, and finally disappear without leaving any trace. Exceptionally the first nodule is the only one, but as many as four have been found. They do not necessarily appear simultaneously, but as one is healing another may make its appearance."

The author notes three main points of difference between the human affection and his artificially produced phlyctenules, viz., (1) the experimental phlyctenules were smaller; (2) ulceration was never observed—at most, extreme thinning of the epithelium; (3) there was never any affection of the cornea. As regards the microscopical structure, he finds this to agree very closely with the description given by Leber, which, however, as is well

known, differs considerably from that given by other authors. The author disclaims any idea that his experiments show the real origin of phlyctenular conjunctivitis in the human subject. He admits that the only complete proof of this would be the discovery of such organisms in pathological material, but as even in some of his expermiental phlyctenules no organisms were found, it is evident that this may present some difficulty. A considerable quantity of material might have to be examined before a definite result was arrived at, and this material is naturally not easy to obtain.

The paper is a model of clear descriptive writing; all necessary detail is minutely gone into, and the facts obtained are not made to support a heavy burden of theory. It certainly marks a step in advance in our knowledge of the pathology of phlyctenular conjunctivitis. E. Erskine Henderson.

---

O. Zeller (Tübingen). **The Treatment of Hypopyon Ulcer with Römer's Pneumococcus Serum.** *Medicinisches Correspondenz-Blatt des Württembergischen ärtzlichen Landesvereins*, Sept. 3rd, 1904.

Till very recently bacteriological enquiry practically limited itself to questions of etiology, so far as concerned ophthalmology at all events. But in this respect the researches, specially of Römer, upon the subject of hypopyon ulcer have opened up certain possibilities in the direction of therapeutics, and have put into our hands a means of influencing the course of the disease, which can hardly fail to prove of immense value.

Römer starts with the principle that ulcus serpens corneæ is caused by a specific infection, with pneumococci; in 95 per cent. of the cases the Fraenkel-Weichselbaum diplococcus lanceolatus is present. By dint of extremely careful and painstaking investigation he found himself, on the bases of other immunity enquiries and Ehrlich's side-chain theory, in a position to say that pneumococcus immunity is due to the development of substances inimical to the growth of low organisms, and not to an anti-toxine, and that the eye, and in particular the cornea, participates in a general immunisation process; he is quite certain of the identity of the pneumococcus with the organism which gives rise to hypopyon keratitis. The only real difference between the two conditions

so far as concerns this matter is that in hypopyon ulcer the systemic reaction is so slight that practically no bacteriolytic substance is created; it certainly cannot be detected in the blood of the patient. The idea therefore upon which this method of treatment is founded is to supply artificially this antitoxin or protective material which is thus lacking. The production of this substance is naturally a problem of great difficulty, but it can, we believe, be supplied by Merck, Darmstadt, and in the hands of Römer at all events, under who instructions it was first "manufactured for sale," it has proved of great value in the treatment of hypopyon ulcers, not only when produced experimentally in the rabbit and monkey, but also in actual clinical work. He considers that in it we have not merely a means of treatment superior to all others, but that it should be used as a prophylactic in cases of injury of the cornea, even a slight solution of continuity being so fruitful a source of hypopyon keratitis.

Zeller has recently treated a certain number of cases of hypopyon ulcer, beginning at as early a stage in the disease as possible, with Römer's serum, some along with, some without, other remedies. The amount injected at a time was usually 5ccm., and his results have apparently been more than satisfactory. He considers it indubitable that the injection has been beneficial and has assisted in the cure of the condition, but he is not able to endorse Römer's high claims in regard to its value. In one of his cases the injection of serum appears to have induced an attack of myocarditis; in all or nearly all the patient's evening temperature was sent up by it.

W. G. S.

---

## Bibliography.


### Anatomy and Physiology.

Bietti. Entoptic phenomena in forced expiration. *Klin. Mon. f. Augen.*, September.
Carlier. Elastic tissue of the eye in birds. *Brit. Med. Jl.*, 24th September.
Grossmann. Investigations on Accommodation. *Brit. Med. Jl.*, 24th September.
Grossmann. The Sanson-Purkinje reflex. *Brit. Med. Jl.*, 24th September.
Marquez. Optic chiasma, binocular vision, etc. *Annals of Oph.*, July.

### Congenital Abnormalities.

Gilbert. Opaque nerve fibres. *Klin. Mon. f. Augen.*, July.
Snyder. Microphthalmos, &c. *Annals of Oph.*, July.

### Hygiene.

Frank. Colour perception in relation to signal lights. *Oph. Record*, August.
Hamburger. The myopia question. *Klin. Mon. f. Augen.*, July.
Lalor. Testing vision of native soldiers. *Ind. Med. Gaz.*, September.
Liebreich. Influence of school upon the eyes of children. *Klin. Mon. f. Augen.*, July.
Sayer. Deterioration of vision during school life. *Amer. Jl. of Oph.*, July.
Seggel. The myopia question. *Klin. Mon. f. Augen.*, July.

## Pathology and Bacteriology.

Johnston. Bacteriology of panophthalmitis. *N. Y. Med. News*, 20th August.
Knapp. Bacteriology of trachoma. *Amer. Archiv. of Oph.*, September.
Puccioni. Cytology of aqueous humour. *Bull. dell. Osp. Oft.*, Rome, August.

## Instruments and Apparatus.

Bailey. Scale for determining muscular insufficiences. *Annals of Oph.*, July.
Higgins. Minus cylinders. *N. Y. Med. Record*, 3rd september.
Lippincott. Irrigator for anterior chamber. *Amer. Jl. of Ophth.*, July.
Roselli. Graduated sound for the globe. *Boll. dell. Osp. Oft.*, Rome, August.
Stevenson. Instrument for removing granulations in trachoma. *Oph. Record*, August.

## Therapeutics.

Bulson. Dionin. *Oph. Record*, August.
Koller. Subconjunctival injection of cocain. *Ophthalmoscope*, September.
Roy. Treatment of iritis by subconjunctival injections. *Ann. d'Oc.*, September.

## Operations.

Barrett and Orr. Operative treatment of entropion and trichiasis. *Ophthal.*, September.
de Britto. Opticociliary neurectomy. *La Clin. Oph.*, 25th August.
Colburn. Operation for relief of nystagmus. *Oph. Record*, August.
Frohlich. Trephining of sclera in glaucoma. *Annals of Oph.*, July.
Hodersch. New method of iridectomy. *Klin. Mon. f. Augen.*, July.
Loring. Sympathectomy for Glaucoma. *Amer. Archiv. of Oph.*, September.
Natanson. Operation for symblepharoo. *Klin. Mon. f. Augen.*, July.
Wamsley. To restore tear drainage. *Oph. Record*, August.
Wicherkiewicz. "Open" treatment after extraction. *Klin. Mon. f. Augen.*, September.

## Traumatisms.

Gagarin. Evulsion of both optic nerves. *Klin. Mon. f. Augen.*, September.
Kohler. Rontgen ray photograph in gun-shot wound of the eye. *Berl. Klin. Woch.*, July
Villard and Delord. Cicatrisation of perforating wounds of cornea. *Arch. d'Oph.*, August

## Tumours.

Besch. Sarcoma of orbit. *Klin. Mon. f. Augen.*, July.
Cantley. Glioma of retina and scalp. *Ophthalmoscope*, September.
Enslin. Melanotic sarcoma of eyelids. *Klin. Mon. f. Augen.*, July.
Mills. Adenocarcinoma of eyelid. *Amer. Archiv. of Oph.*, September.
Monthus. Tubercular pseudo-tumour of eye. *Arch. d'Oph.*, August.
Sommer. Sarcoma of eyelids. *Wch. f. Ther. und Hyg. des Auges.*, vii. 52.

## Sympathetic Ophthalmia.

Motais. Transmission of sympathetic ophthalmia by the veins. *L'Oph. provin.*, September.
Thiel. Sympathetic amblyopia. *Amer. Jl. of Oph.*, July.

## Glaucoma.

Frohlich. Trephining of sclera in glaucoma. *Annals of Oph.*, July.
Galezowski. Glaucoma. *La Clin. Ocul.*, July—August.
Horstmann. Glaucoma simplex. *Amer. Arch. of Oph.*, September.
Hotta. Glaucoma in highly myopic eyes. *Klin. Mon. f. Augen.*, July.
Loring. Sympathectomy for Glaucoma. *Amer. Archiv. of Oph.*, September.
Searles. Atropin and eserine in glaucoma. *Amer. Jl. of Oph.*, August.

## Amblyopia and Visual Defects.

Altland. Quinine amblyopia. *Klin. Mon. f. Augen.*, July.
Valenti and Marchi. Effect of nicotine on vision. *Boll. dell'Osp. Oft.*, Rome, August.

## Refraction and Optical Questions

Baslini. Ophthalmometric researches. *Arch. d'Oph.*, September.
Barnett. Pseudo-neuritis due to astigmatism. *Amer. Jl. of Oph.*, August.
Frenkel. Relation of myopia to opacities of cornea. *Ann. d'Oc.*, September.
Gould. Postmydriatic refraction tests. *Annals of Oph.*, July.

## Regional Affections.

### Eyelids.

Dutoit. Lymphoma of eyelids. *Amer. Archiv. of Oph.*, September.
Mills. Adenosarcoma of eyelids. *Amer. Archiv. of Oph.*, September.
Enslin. Melanotic sarcoma of eyelid. *Klin. Mon. f. Augen.*, July.
Sommer. Sarcoma of lids. *Woch. f. Ther. und Hyg. des Auges.*, vii. 52.

## Lachrymal Apparatus.

Cirincione. Excision of the sac. *La Clin. Oc.*, July—August.
Demaria. Antitoxic effect of tears upon diphtheria-toxin. *Klin. Mon. f. Augen.*, September.
Jackson. Dislocation of lachrymal gland. *Oph. Record*, August.
Libby. Polypus of canaliculus. *Oph. Record*, August.
Shoemaker. Bilateral enlargement of lachrymal glands. *Annals of Oph.*, July.

## Conjunctiva.

Bartels. The purulent ophthalmia of certain wild fowl. *Klin. Mon. f. Augen.*, September.
Brown. Pemphigus of conjunctiva. *Annals of Oph.*, July.
Knapp. Bacteriology of trachoma. *Amer. Archiv. of Oph.*, September.
Parker. Non-operative treatment of Trachoma. *N. Y. Med. Record*, 17th September.
Schiele. Eczema of conjunctiva. *Woch. fur Ther. und Hyg. des Auges.*, 50, 51.

## Cornea and Sclerotic.

Frenkel. Relation of myopia to opacities of cornea. *Ann. d'Oc.*, September.
Lafon and Delord. Neuroparalytic keratitis. *Rev. Gen. d'Oph.*, 31st August.
Nibo. Treatment of opacities of cornea. *La Presse Méd. Belge.*, 14th August.
Veasey. Family macular degeneration of cornea. *Amer. Arch. of Oph.*, September.
Zeller. Treatment of ulcer of cornea with pneumococcus serum. *Med. Corresp.-Blatt.*, *Wurtemburg.* 3rd September.

## Iris and Ciliary Body.

Frenkel. Mydriasis "à bascule." *Archiv. d'Oph.*, September.
Harms. Pathology of iridocyclitis with deposits on posterior aspect of cornea. *Klin. Mon. f. Augen.*, July.
Herbert. Size of pupil in iritis. *Ophthalmoscope*, September.
Meller. Free cysts in anterior chamber. *Klin. Mon. f. Augen.*, September.
Roy. Treatment of iritis of subconjunctival injections. *Ann. d'Oc.*, September.
Steele. Anisocoria. *Oph. Record*, August.

## Lens.

Augieras. Spontaneous absorption of cataract. *La Clin. Oph.*, 25th August, and *L'Oph. provin.*, September.
Peters. Pathology of the lens. *Klin. Mon. f. Augen.*, July.
Thomson. Pathology of the lens. *Annals of Oph.*, July.
Weiss. Traumatic posterior polar cataract. *Klin. Mon. f. Augen.*, September.
Wolffberg. Method of artificial ripening of cataract. *Woch. f. Ther. und Hyg. des Auges.*, 52.

## Choroid and Vitreous.

Reis Change in choroid after ophthalmia nodosa. *Amer. Archiv. of Oph.*, September.

## Retina.

Cantley. Glioma of retina and of scalp *Ophthalmoscope*, September.
Deutschmann. Treatment of detachment of retina. *La Clin. Ocul.*, July—August.
Hawthorne. Opaque nerve fibres. *Ophthalmoscope*, September.
Millitrin. Dilatation of an artery and vein of retina. *Amer. Archiv. of Oph.*, September.
Quirin. Retinitis punctata albescens. *Klin. Mon. f. Augen*, July.

## Optic Nerve.

Burnett. Pseudo-neuritis due to astigmatism. *Amer. Jl. of Ophthal.*, August.
Grimsdale. Acute retrobulbar neuritis. *Treatment*, August.
Roosa. Retrobulbar neuritis. *Annals of Oph.*, July.

## Muscles (and Strabismus).

Posey. Paralysis of upward movement. *Annals of Oph.*, July.

## Orbit.

Ahlstrom. Pseudo-leukaemic tumour of orbit. *Klin. Mon. f. Augen.*, September.
Besch. Sarcoma of orbit. *Klin. Mon. f. Augen.*, July.
Nicolini. Ivory exostosis of orbit. *La Clin. Oc.*, July—August.

## Relations with Medicine.

Lagrange and Aubaret. Congenital syphilis of the eye. *Arch. d'Oph.*, August.
Phillips. Eyestrain a cause of sinusitis. *Amer. Med.*, 17th September.
Shoemaker. Eyestrain as cause of migraine. *Amer. Jl. of Oph.*, July.
Stoewer. Tertiary syphilis of the eye. *Klin. Mon. f. Augen.*, September.
Terrien. Chancre of the eye. *Le Prog. Méd.*, 3rd September.

## Miscellaneous.

Miel. Who first demonstrated the inverted image? *Arch. d'Oph.*, August.
Teillais. Ocular hystero-traumatism. *Arch. d'Oph.*, August.
Wolffberg. Why the moon looks larger near the horizon. *Woch. f. Ther. und Hyg. des Auges.*, vii. 52.

# NOTES ON CASES OF PULSATING EXOPHTHALMOS.

By C. H. Usher, Aberdeen.

Notwithstanding that a large number of cases of pulsating exophthalmos have been reported, it is only in comparatively few that an *autopsy* has been made.

Lagrange[1] in his recent work on "Tumours of the Eye and Orbit," in which he gives a résumé of 247 cases of pulsating exophthalmos, says that the pathological anatomy of this affection is based on the data derived from 19 *autopsies*. These examinations show that the nature of the lesion is by no means constant.

Amongst the conditions which have been found are aneurysm of the internal carotid, aneurysm of the ophthalmic artery in the cranium or in the orbit, ruptured internal carotid, venous lesions only—inflammation of ophthalmic veins and of the cavernous sinus.

In some of these cases, which include both idiopathic and traumatic forms, doubt has been expressed as to the reported lesion being responsible for the symptoms. Bull[2] states, without references, that since Sattler's paper (1880) on the subject was published 18 *autopsies* have been reported, which brings the number, although still very limited, to considerably over 19.

The following notes of three cases of pulsating exophthalmos include: a fatal case of traumatic origin in which a *post-mortem* examination was made; one of spontaneous or idiopathic pulsating exophthalmos which has been under observation for nearly seven years; and a third case belonging to the traumatic group which has been followed for 18 months.

Case I. *Right traumatic pulsating exophthalmos; ligation of right external and internal carotid arteries; death; post-mortem examination.*

G.S., aged 32, a fisherman, was admitted to the Royal Infirmary on 14th June, 1904. A few hours previously he had been shot on the head by pellets from a fowling piece, at a distance of 12 yards. When struck he was rising from a stooping to an erect position and was facing the shooter, who was firing at a bird over his head. He was knocked down, but is not certain whether he lost consciousness. His nose and his left ear bled. He vomited several times after the injury and complained of great pain in the head and right orbit.

On examination the following conditions were found:—

Right eye: V.=no perception of light. Pupil half dilated, no action to light. Cornea slightly hazy all over. Lids greatly swollen, tense and ecchymosed, and with difficulty separated sufficiently to expose the cornea. Pulsating movement felt through upper lid. Proptosis. Globe scarcely moves at all in any direction. At upper inner part of upper lid is a small wound.

Left pupil circular, active to light, and of medium size. Cornea clear. Movements of globe full.

The patient is a strong, healthy-looking man; he complained of great pain in his head and right orbit. In addition to the wound of the right upper lid there are four others apparently made by pellets:—(1) in scalp, pellet is felt beneath it, this proved to be a No. 4 shot; (2) over left malar bone; (3) at left tip of nose; (4) through the helix of left ear. Chest and abdomen normal. No paralyses of arms, legs, or face. Urine: acid, 1020, no albumen or sugar. He had always had good health. Is said to be alcoholic.

*June 15th.* Pain not quite so severe. Hears noises in his head which he likens to those produced by a waterfall or a steam-engine; they are diminished when the right carotid is compressed. Proptosis is very marked. Pulsation, synchronous with the heart beat, is felt when the fingers are laid on the right lids; it is clearly visible, as it is communicated to the lids. On auscultation a loud blowing bruit is heard over right globe and temple. The right side of the neck is seen to pulsate markedly whilst on the left side pulsation is scarcely visible. Vomited several times last night. Right eye exposed with difficulty; cornea somewhat hazy; some chemosis. Left pupil circular, active to light, not dilated.

*June 16th.* Vomited once last night. The noises in the head are getting worse. He has pain in right brow, but not so severe as formerly. The bruit has a blowing character during systole and is very loud over the right eye and right temple, but is heard also over the left eye and temple. He hears no noise in the head so long as the right carotid is compressed, but as soon as the finger is relaxed the noise returns. Some discoloration of the left lower lid is seen, possibly due to the wound on the cheek. In the left eye there is no pulsation; its pupil is circular and active to light, the movements of globe full, the media clear and the fundus normal. With this (left) eye he reads 1 J at 12 inches.

*June 17th.* Dr. Gray ligatured the right external and internal carotid arteries just above the bifurcation. Pulsation could then no longer be felt in right orbit. Three hours after operation the patient became restless and attempted to get out of bed.

*June 18th.* Right eye shows swelling of lids and proptosis, but much less marked. No bruit. No pulsation. Left

eye is kept closed. Very restless, keeps moving both his legs, and his right arm is used as though he were catching at objects in the air. In the evening potassium bromide and chloral hydrate were given and he slept for some hours afterwards.

*June 19th.* About five in the morning he was suddenly seized with dyspnœa, became blue in the face, comatose, and died in twenty minutes.

*Mental condition after the operation.* He often thought that he was at home, but was conscious, and recognised people and sometimes spoke to the nurse. Took nourishment well. No fits. No vomiting. Complained of aching all over him and of headache. The operation wound was quite healthy. His chart showed that the respirations varied from 16 to 18, and pulse rate from 68 to 82 per minute. The temperature was normal until five hours before death, when it rose to 102·6°.

A communication between the internal carotid and the cavernous sinus seemed to be the most likely explanation of the symptoms in this case. To explain the complete loss of vision it was thought possible either that the optic nerve had been divided by a fracture at the optic foramen, or that a pellet had entered the orbit at the wound on the inner part of the upper lid and had passed backwards injuring the optic nerve or the retinal artery.

Through the kindness of Professor Hay, who made the *post-mortem* examination, the right orbit intact and part of the base of the skull were removed for careful examination.

The condition of the body generally need not be reported as it does not afford any evidence as to how the intracranial lesion described below was produced.

On removal of the brain a blue appearance was seen

through the right orbital plate of the frontal bone in marked contrast to the appearance of the left supra orbital plate. There was a small quantity of fluid tinged slightly red in the front of the middle cerebral fossa.

We are indebted to Professor Reid for his minute dissection of the orbit and cavernous sinus, and for the following report:—

Two specimens were received: (1) a wedge-shaped portion of the base of the skull consisting of the right orbital cavity, the body of the sphenoid, and a part of the basilar portion of the occipital bone; and (2) a brain. The skin and soft parts including the eyelids and the contents of the temporal and pterygo-maxillary fossæ were absent. The walls of the orbit and the contents of that cavity had not been disturbed.

On looking at the front of the specimen as it was received the eyeball was seen to bulge forwards and a large amount of hæmorrhage was visible under the sclerotic conjunctiva. Looked at from above, the dura mater lying upon the roof of the orbit presented normal appearances. The part of that membrane forming the outer wall of the cavernous sinus, and the part in relation with the Gasserian ganglion and the inferior maxillary nerve before its exit from the cranial cavity, showed much hæmorrhage both in their substances and immediately underneath it. On examining these portions of the dura mater minutely no aperture or other abnormality was visible. The specimen was subjected to the X-rays and the skiagram gave no indication of the presence of a foreign body.

On incising the upper wall and pushing to the right the outer wall of the cavernous sinus, much blood was seen. In the inner and upper walls of the internal carotid artery as it made its upward turn to pass to the brain, and just

before it gave off its ophthalmic branch, two rents appeared. They communicated with the cavity of the cavernous sinus and were separated from one another by a narrow bridge in the upper wall of the vessel. (See drawing.) The inner rent was very much larger than the outer and the edges of both apertures were ragged and everted, especially the inner one.

There was no fracture of adjacent bone, no appearance of aneurysm of internal carotid or of the ophthalmic artery, and no evidence of tumour or of a foreign body. There were no signs of injury to the optic nerve or to the nerves in connection with the outer wall of the cavernous sinus.

On removal of the roof of the bony orbit the periosteum of the cavity bulged especially behind the internal angular process of the frontal bone where it seemed darker in colour than elsewhere. On incision the tightness and bulging of the membrane were accounted for by (1) a swelling of the fleshy portions of the ocular muscles caused by what appeared to be an œdematous condition of their substances; (2) much distension and tortuosity of the ophthalmic veins; and (3) two extravasations of blood: one in the ocular side of the superior oblique and the internal rectus muscles anteriorly, and the other on the orbital aspect of the external rectus more posteriorly. In addition to these extravasations there was evidence of blood-staining throughout the rest of the cavity, but there was no definite or particularly blood-stained track connecting the two extravasations, such as might have been caused by the passage of a pellet through the orbital cavity.

The contents of the orbital cavity were carefully dissected. A very minute aperture with an even margin was found in one of the branches of the superior ophthalmic vein a little way behind the internal angular process of the

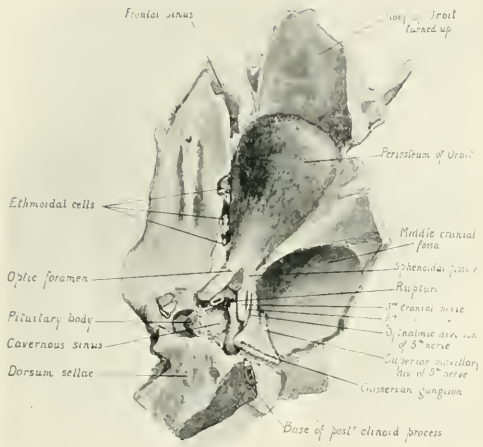


DRAWING OF PROFESSOR REID'S DISSECTION.

(The drawing is made to scale.)

The lesser wing of the sphenoid, the upper part of the optic foramen, and the posterior clinoid process on right side have been removed. The roof of the orbit is raised and turned forwards, exposing the distended periosteum. The cavernous sinus and the rupture in the internal carotid artery are shown.

frontal bone, but whether or not such aperture had been artificially produced in the progress of the dissection it was impossible to say. It lay in the centre, however, of the extravasated blood in relation with the superior oblique, superior and internal recti muscles.

All the other structures within the orbital cavity presented normal appearances with the exception of the œdematous conditions of the muscles and the enormously distended and very tortuous conditions of the veins.

There was no evidence of injury to the bony walls or the enclosed periosteum.

On removing the upper walls of the ethmoidal cells the cavities of these spaces were seen to be filled by blood-stained mucus.

On subjecting the brain to the Röntgen rays no evidence of foreign body or other abnormality was discovered. Its blood vessels, pia mater, and arachnoid were quite healthy, and upon dissection the organ presented normal features.

*Remarks.* In a case of Blessig's[3] a wound found in the internal carotid artery was considered to have been made accidentally during the dissection, but in the present case we are assured that such could not be so.

The large rupture of the internal carotid into the cavernous sinus doubtless was the cause in this case of the symptoms present during life, and of the condition of the orbit found after death, but it is very difficult to account for its presence. There was no fracture of bone causing injury to the vessel, and no evidence of a pellet having entered the orbit or cranium. There were no signs of previous disease in the artery such as atheroma or aneurysm. A microscopical examination showed no evidence of disease. We seem then to be driven to accept the somewhat unsatisfactory explanation that the wound

was caused, when he fell, by *contre-coup, c.f.*,[4] or the even more unlikely view that it was caused by an undiscovered pellet that passed through the sphenoidal fissure—transit through the optic foramen appears impossible—without leaving evidence of damage to the structures occupying this part. No lesion was found on the left side of the skull. The bleeding at the nose and the left ear was accounted for by local lesions at those situations. The blood-staining in the ethmoidal cells is attributed to distension of their veins which communicate with the ophthalmic veins.

The dissection has a resemblance to a drawing from a case of Nelaton's in which the artery is represented as being torn in the same situation as in the present specimen, but in his case there is also an orifice in the wall of the sphenoidal sinus communicating with the cavernous sinus.

A prominent feature in this case was the marked visible pulsation of the neck on the side of the lesion. An examination of both common carotids after death showed nothing to account for the abnormal amount of pulsation, which could probably be explained by the diminished resistance to the blood-stream in the right carotid produced by the lesion at the cavernous sinus.

To what extent the ligation of the arteries was responsible for the symptoms that followed the operation, or what part alcoholic habits played in the production of the symptoms is doubtful, but before the operation the patient experienced much relief when the right common carotid was compressed by the finger, and the bruit, pulsations, and noises in the head ceased. Further delay, with prolonged digital compression, before operation might have been advisable so as to have allowed a fuller development of the collateral circulation, but it is not likely that, with

such a large opening in the internal carotid, this would have effected a cure. Early operation was decided upon in view of the severe pain and great general distress, the risk of the cornea sloughing as a result of the great tension in the orbit, and the danger from hæmorrhage. Out of 63 cases of ligation of the carotid for pulsating exophthalmos four cases had disturbances of cerebral functions and three of these ended fatally.[5] Lagrange's statistics show that of 99 patients with pulsating exophthalmos treated by ligature of the common carotid death occurred 12 times as a consequence of the operation.

Case II. *Left spontaneous pulsating exophthalmos; ligation of left internal and external carotid arteries; recovery.*

Wm. P., aged 57, a shepherd, was admitted to the Royal Infirmary on October, 1898. One morning, seven or eight weeks previously, when he rose, he noticed a "stiffness" in the left eye as if it were bulging or swollen, and on looking in the mirror he found that it was redder than the right eye. There has been no pain in it, but only a feeling of "motes." Sight of left eye is as good as ever. No history of injury. The left eye is in the same condition now as when he first noticed it, except that he thinks it bulges slightly more now, the redness is the same as when first noticed. For the last six or seven weeks he has heard a sound in his head which he describes as like the noise made by breathing through the mouth. This noise he hears only when either ear is against the pillow.

He has always been very healthy; has been temperate; no history of syphilis or of rheumatism except for slight occasional pains in back; ruptured for five years.

No history of heart affections, gout, or rheumatism in his family, and no eye affections.

*On examination.* Eyes: *Right eye,* V. $^{6}/_{9}$ Hm. ·5D; pupils equal and active to light; T.n.; media clear; fundus normal. *Left eye,* V. $^{6}/_{12}$ Hm. ·5D. Œdema of lids, especially the upper one, and congestion of veins of upper lid. Proptosis; pulsation of eyeball; movements of the globe impaired in all directions, especially outwards. Conjunctival vessels injected; chemosis; with stethoscope a loud blowing bruit synchronous with the pulse is heard over the eyeball resounding as if in a cavity. It is widely conducted by the bones of the skull, being heard in right temple. It almost ceases on pressing left carotid. The left optic disc is paler than the right and the retinal veins are distinctly larger. No pulsation in either arteries or veins; rest of fundus normal. Has right inguinal hernia. Heart: Apex beat in 5th left interspace just inside the nipple line, visible, diffuse and waving in character; distinct irregularity. Systolic bruit is heard at the apex, also marked accentuation of the second sound at pulmonic area; at inner end of 5th left interspace there is reduplication of first sound. Radial arteries rigid.

Lungs normal. Urine normal colour, acid, 1020, no albumen or sugar, mucous deposit; 5th and 7th nerves normal. Hearing: right, watch on contact; left, not at all. Nasal and oral cavities normal. No evidence of aneurysm elsewhere.

*On October 20th* Professor Ogston ligatured the left internal and external carotid arteries just above the bifurcation.

*On November 15th,* with the exception that the retinal veins of the left eye were slightly larger and darker than those of the right eye, both fundi were normal.

*November 30th.* R.V. $^{6}/_{9}$ with +3D sph. reads 1J at 13in. L.V. $^{6}/_{9}$ with +3D sph. reads 1J at 13in. Pupils equal and

contract to light and on accommodation. Movements of globes full. Proptosis still present on left side but much less marked than before operation. Conjunctival vessels more dilated than on right side. No pulsation felt on pressing globe backwards. A bruit is audible on placing stethoscope on globe but is faint and is not heard at temple or on other globe. The ophthalmoscopic appearances are the same as on 15th.

*July 27th, 1904.* Dr. Hector (Tarland) kindly writes to report that the patient has been working constantly since he left the Infirmary, and that he has had no trouble with his eye.

*August 9th, 1904.* Patient came to the Infirmary to-day for an epithelioma on his lower lip. He has been working constantly since we saw him last nearly seven years ago. His work, that of shepherd, is carried on in a steep, hilly district. The noises that he formerly heard in his head have never returned and he sees as well with the left as with the right eye.

*On examination. Left eye* is proptosed to a slight, but quite definite degree. Movements of globe full. Convergence normal. No thrill felt or bruit heard over the globe. No enlarged vessels seen on the globe. Oph. media clear. Fundus normal. V. $^{6}/_{6}$ partly Hm. ·5D, reads 1J with + 4D Sph. Field is full. *Right eye* is quite normal. V. $^{6}/_{6}$ partly, Hm. ·5D, reads 1J with + 4D Sph. Pupils are equal, size 2·75mm., contract to light and on accommodation. Sensation of cornea apparently the same on each side. There is no distension of vessels on the lids or face of either side. He looks in good health and with the exception of slight stiffness when he gets very wet there has been no trouble with his neck since the operation. There is evidence of marked arterio-sclerosis in many of his blood-vessels. In

view of this fact, combined with the nature of his occupation and the absence of traumatic lesion, we may reasonably believe that the cause in this case was an aneurysm of the internal carotid or of the ophthalmic artery.

It may be noted that the majority of cases of spontaneous pulsating exopthalmos have occurred in females—23 out of 32 (Sattler).

Case III. *Left traumatic pulsating exophthalmos; ligation of left common carotid; recovery.*

H.T., female child, aged 4, admitted to the Sick Children's Hospital in February, 1903. Two months ago a neighbour noticed that the child's left eye was bulging out. The mother says that this has got steadily greater. Two weeks before the bulging was noticed the child fell down a flight of four or five wooden steps and struck the left side of her face, causing bruising of the eye lids and swelling, so that the eyeball was invisible. There was unconsciousness for ten or fifteen minutes, bleeding from the nose, and nausea, but no vomiting. Nothing had been noticed amiss with the eye before the injury.

Parents are healthy. Patient is the seventh of a family of nine; three have died—the fourth child, aged five months, from enteritis; the sixth, aged three years, from influenza; the ninth, aged three days, from hæmorrhage of the bowels.

*Examination of eyes. Left eye:* marked proptosis straight forwards. No strabismus. Movements of globe full. There are several large and very tortuous vessels in the ocular conjunctiva chiefly at the outer half, and also in conjunctiva of lower lid. No dilated vessels are seen in the palpebral conjunctiva of upper lid. The veins seen

through the skin of upper lid are fuller than those in right upper lid. Pupils equal, size 2·5mm., but the left one reacts sluggishly to light. No dilated vessels on the iris. On pressing the globe backwards distinct pulsation is felt. Nothing abnormal felt in orbit. On auscultation a loud bruit is heard synchronous with the pulse, it is heard loudest over the eyeball, less loudly over the left temple, and still less loudly over the right eyeball. The bruit can be stopped by pressing the left common carotid artery. There is a scar on upper part of left frontal region. Corneal reflex present. T.n.

*Vision.* The child recognises objects such as knives, scissors, coins, etc. Ophthalmoscopically:—Media clear. Marked pulsation in all of the large retinal arteries. Retinal veins are considerably distended and tortuous, the bends forming short curves. The retinal veins in the right eye are particularly straight.

*Right eye* is quite normal.

On being asked, the child admits hearing a noise in her head, but has not complained of it.

She is of a stolid type and does not cry; the carotid can be pressed without causing her inconvenience. Nothing abnormal noted in other parts. Grasp is equal on the two sides. Knee jerks are present and equal.

*On March 4th* Dr. Rose tied the left common carotid. At the time the ligature was applied no obvious change occurred in the retinal arteries or veins (pupil dilated with homatropine), but on close examination immediately after the operation no pulsation could be detected in the retinal arteries. Proptosis diminished. A distinct bruit could be heard over the globe one hour after the operation.

*March 9th.* Proptosis is obviously less marked and the

conjunctival vessels have diminished in size, no pulsation of globe felt, bruit still heard but very feebly when compared with what it was before operation.

*March 23rd.* Proptosis greater again and bruit louder. Vision probably normal, counts fingers and recognises coins. Movements of globes full. Pupils equal and active to light.

*March 26th.* Left optic disc is redder than the right. No pulsation in the retinal arteries. Retinal veins are more engorged and tortuous than before operation.

*Mar. 30th.* The conjunctival vessels have again become almost as markedly engorged as before operation.

*August 1st, 1904.* The child was brought by request. She has been in good health since she left the hospital and plays about like other children. The mother says that the left eye gives the child no trouble with the exception that on bright sunny days she sometimes covers it with her hand; she believes that the sight of the left eye is quite good, as she has frequently tested it by closing the right eye.

*On examination. Left eye* presents much the same degree of proptosis as was present sixteen months ago, and the swelling and tortuosity of the conjunctival vessels remain in the same condition as at that time. Movements of the globe are full, but on convergence the globe makes very little attempt to move inwards. The pupil is wide and does not contract to light or on accommodation; tension normal. The veins on the upper lid are more prominent than those on the right upper lid. When she closes her eyes the lids cover the cornea. There is a diffuse haze of the cornea but it is not very conspicuous; there is no ulceration and no congestion around the cornea. Optic disc and the larger retinal vessels are seen with the

ophthalmoscope, but owing to the corneal haze the details of the fundus cannot be made out.

*Vision.* Named correctly several small objects at distances from 1 to 12 feet. No pulsation of globe and no bruit can be heard over globe or temple.

*Right eye.* Pupil circular and active to light. Movements full. Fundus normal. No paralysis of limbs or face. Hearing good on both sides.

We may note two points in the case:—(*a*) the age of the patient; in Lagrange's list of 166 cases of traumatic pulsating exophthalmos two of the patients were four years of age, but none of those whose age is stated were younger than this child; (*b*) the complete absence of movements of the pupil that accompanied its dilatation; this is an unusual occurrence.[6]

The treatment adopted in each of the three cases here recorded was similar, viz., ligation, on the same side as the lesion, of the common carotid (Case 3), or else of the internal and external carotid arteries simultaneously (Cases 1 and 2). In Case 1 the ligature was applied much sooner after the onset of the symptoms than was the case in either of the other cases. No discomfort was experienced after the operation in Cases 2 and 3, which may be regarded as cured.

The suggestion of ligaturing the external and internal carotids instead of the common carotid was made to us by Professor Reid.

The advantages of this procedure are (1) prevention of collateral circulation by the branches of the opposite external carotid into branches of the external carotid on the affected side thence down to the bifurcation into the internal carotid; (2) diminution of the rush of blood between the branches of the ophthalmic artery and those

with which they communicate outside the orbital cavity, *e.g.*, the facial, infra-orbital, temporal, etc., on the side of lesion.

REFERENCES.

[1] "Traité des Tumeurs de l'Oeil," 2nd vol., 1904.
[2] Norris and Oliver. "System of Diseases of the Eye," 1898, Vol. iii., p. 32.
[3] Lagrange. "Tumeurs de l'Oeil," 2nd vol., p. 271.
[4] De Wecker and Landolt. "Ophtalmologie," p. 906.
[5] Norris and Oliver. "System of Diseases of the Eye," Vol. iii.
[6] de Wecker and Landolt, Vol. iv., p. 869.

---

## PRESENT VIEWS REGARDING THE ORIGIN OF THE VITREOUS.

By Prof. CIRINCIONE, Genoa.

PART. I.

OF recent years the embryology of the vitreous has been a favourite object of research by many workers, who, after having studied a few embryos of one or more of the different classes of vertebrates, consider themselves competent to form and hold opinions on its origin only because their writings are well illustrated. At the present time there is not a single embryological formation in the eye that has not been at one time or another considered to be the *fons et origo* of the vitreous; for it has been ascribed to the epidermis invaginated in the formation of the lens, the mesodermic invagination filling the secondary optic vesicle, the blood plasm, the white blood corpuscles, the retina, the pars ciliaris retinæ and finally even to the lens.

This only demonstrates the difficulty of the question and the great necessity of caution in the interpretation of facts and in the formation of theories. I believe few have spent so much time and labour on the study of this subject as I have since 1889, and yet I find it necessary constantly to undertake new researches with new methods of technique. I hold, and I have expressed this opinion many times, that in researches of this nature a great amount of circumspection is necessary before attributing one significance more than another to that which

histological preparations show, and that above all it is necessary to have proper material for study and good preparations.

Not believing in resting altogether on one's own judgment, but in finding out the opinions of other authorities, I attended, in June, 1903, the German Congress of Anatomy at Heidelberg, where a discussion was announced on the origin of the vitreous. (See Appendix). I took a part in this Congress with the hope that such discussions might stimulate further work, and so result in clearing the ground of prejudices and preconceived ideas.

Nowadays works on the vitreous follow each other with such rapidity that it is difficult for one who does not closely follow the literature on this subject to form an exact idea of the present views as to the origin of the vitreous, and I propose now rapidly reviewing the investigations made up to date, adding thereto the controversial points, so that the reader may form his own judgment on this question, of so much interest to the anatomist as well as to the ophthalmologist.

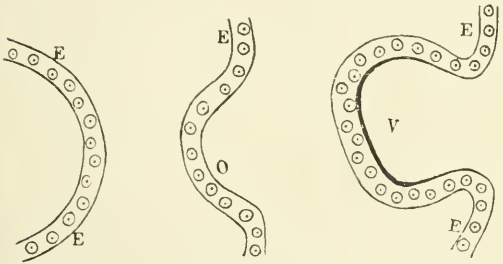


Fig. 1. Fig. 2. Fig. 3.

The space between the lens and retina wherein the vitreous lies is formed in a different way in the embryos of vertebrates and of invertebrates. In *the invertebrates* the epidermis at that spot where the eye develops becomes dimpled in (O, Fig. 2), and in time deepened to form a hollow sphere with an external opening (Fig. 3), which either becomes closed (Fig. 4), or a lens fills the opening more or less completely (Fig 5). Such is the way the globe of the eye is developed with its vitreous

cavity, (V) lens and retina, the latter having its pigment layer on the superficial aspect of the retina. Fig 3 corresponds to the eye of charydea marsupialis, Fig. 4 is that of nereis cultrifera, and Fig. 5 octopus vulgaris.

*In vertebrates* the vitreous chamber, as was first shown by Remak in 1855, is formed as the result of a much more complicated process. In embryos of this class one has to deal with an ectodermic covering which invests the whole body, and a medullary canal derived from it in the following manner:—On the dorsal aspect of the embryo—which at an early stage of its development shows an oval outline (Fig. 6)—a longitudinal sulcus (C) is formed which, deepening into a groove (Figs. 7 and 8), finally becomes a closed canal, detached and independent of the ectoderm from which it originated. (In the drawings transverse sections of the embryo are illustrated at the level of C, Fig. 6.)

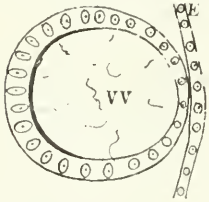


Fig. 4.

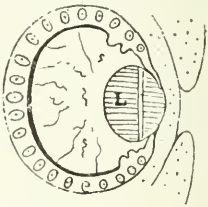


Fig. 5.

From the cephalic extremity of the neural canal the primary optic vesicles are developed as hollow buds attached to the future brain by the optic peduncle. The ectoderm (E) corresponding to the apex of the vesicle (indicated by the shaded portion in the figures) becomes thickened, dimpled in, and invaginated within itself, thereby forming the secondary optic vesicle (Figs. 14, 15, 16). At the same time, the surface ectoderm over the primary optic vesicle becomes dimpled in to form the hollow sphere representing the embryonic lens which comes to lie in the cavity of the new vesicle while it is still in the process of formation (*i.e.*, the secondary optic vesicle, Fig. 18, V O S ).

This invagination of the distal portion takes place not only at the apex, but also below and throughout the whole length of the vesicle, so that the secondary vesicle can schematically be represented by Fig. 16. At this stage a section made parallel to the neural canal would present an appearance, as in Fig. 19, of a horseshoe open below. The primary optic vesicle (Figs. 10, 11, 12) and the cavity of the secondary optic vesicle (Fig. 17) in vertebrates are surrounded on all parts by mesoderm (M M), which is not the case in invertebrates; in the latter no invagination of the optic vesicle takes place, as development is arrested at the stage of the primary optic vesicle, while the pigment layer of the retina occupies the superficial aspect of the same.* In invertebrates the globe

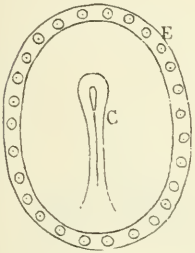


Fig. 6.

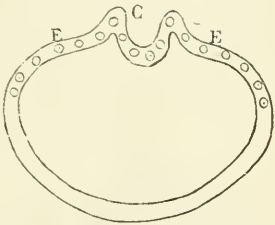


Fig. 7.

of the eye is filled by a product of secretion from the retinal cells called the vitreous, in which are to be found fine fibrillæ, or rather protoplasmic prolongations from the cells of the retina. The nature of this gelatinous mass has never been properly studied, though it has never been compared to the vitreous of vertebrates, as in origin and development it is the homologue of the fluid that fills the primary optic vesicle of vertebrates, and also the neural canal. As regards the vitreous of vertebrates, "whose histogenesis is at present the most

* The homologue is complete when one remembers that in vertebrates inversion of the surface ectoderm results in the development of the neural canal.

interesting and the most discussed problem in embryology,"* opinions of the greatest diversity are held. By some it is supposed to be derived from the ectoderm as in invertebrates, others hold it to be of mesodermic origin, while a third party considers that it is of mixed origin, being derived at the same time partly from the ectoderm and partly from the mesoderm.

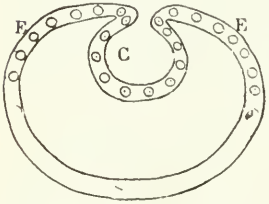


Fig. 8.

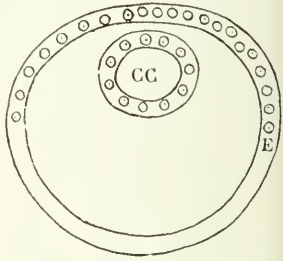


Fig. 9.

Fig. 10.

Fig. 11.

* Aurel von Szily—Zur Glaskörperfrage. Eine vorläufige Mitteilung—*Anatom. Anzeig.*, 1904.

## REVIEWS.

LOESER. **The Ocular Symptoms of Aneurism of the Internal Carotid.** *Archiv für Augenheilkunde*, August, 1904.

CASES of aneurism of the internal carotid, other than traumatic, which have been diagnosed during life, are not common. In the case here recorded the diagnosis was made more difficult by an attack of facial erysipelas, which, it was supposed, had caused orbital cellulitis, to which the proptosis, venous congestion, optic neuritis, hæmorrhages and paralysis of eye-muscles were at first attributed. The symptoms improved under iodide of potassium, and it was not until five months after the patient had been first seen, and in consequence of complaints from her of a rhythmical humming in her head, that the skull was auscultated, when a loud bruit, best heard in the right temporal region, revealed the true nature of the case. The moral is that in obscure cases of proptosis and paresis of eye-muscles the possibility of aneurism should always be remembered. It is a remarkable fact that in the nine cases now recorded (excluding traumatic cases) the patients have all been women. With regard to the question of undertaking ligature of the common carotid, the evidence shows that it is a procedure which should by no means be lightly undertaken in these cases of primary aneurism when the vessels through which a collateral circulation can be established are not unlikely to be themselves diseased. In two out of five cases in which the operation was performed death occurred within a week, a very different proportion from that which holds in ligature of the carotid for conditions other than primary aneurism. On the other hand, in two cases in which ligature of the carotid was proposed, but not accepted by the patient,* an arrest of the disease (by large doses of iodide of potash or spontaneously) was obtained. In Hutchinson's case the diagnosis was confirmed when the patient died ten years later of aneurism of the abdominal aorta. In the circumstances, and taking into account, too, that in one of the fatal cases a recent softening of the whole hemisphere was found at the *post-mortem*, the author is inclined to condemn ligature of the common carotid in these cases altogether, though he would advocate systematic compression followed, when necessary, by ligature first of the internal, and after an interval of the external carotid. A. H. T.

* Humble's and Hutchinson's, both reported in the *Lancet* for 1875.

WIDMARK. *Mitteilungen aus der Augenklinik des Carolinischen Medico-Chirurgischen Instituts zu Stockholm.* Part 5.

CONTRIBUTIONS of this kind, local to a particular clinique, are apt to be overlooked. Nevertheless they often, as in this case, contain important information. The multiplication of ophthalmological periodicals is in one respect much to be regretted, for it makes the task of the student who would keep abreast of his subject almost insurmountable. No doubt many journals, in common with the *Ophthalmic Review*, endeavour to give their subscribers a useful epitome of the current literature of ophthalmology, but even at the best a "boil down" can never be equal to the original article. The contributions in the work which we are at present considering are nine in number, viz.:

1. A case of Bilateral Congenital Lachrymal Fistula.
2. A case of unusually good Visual Acuteness in an Aphakic Eye.
3. On Transfixion of the Iris.
4. A case of Bilateral Hydrophthalmos complicated with Separation of the Retina in the Right Eye.
6. Two cases of so-called clear Mikrophthalmos with Glaucoma.
7. On Nævus of the Conjunctiva.
8. A case of Encanthis Maligna.
9. A new operation for Senile Entropion.

The transfixion of the iris is the operation which Fuchs described at the Heidelberg Congress in 1896, and is a useful substitute for iridectomy in certain cases of posterior synechia. The present contribution deals with nine examples of the operation. Dr. Ekehorn's method of operating for senile entropion seems an extremely simple one. It consists of taking out a large flap of conjunctiva from the neighbourhood of the retrotarsal fold and of stitching the edges of the wound together.

---

MERCK. **Annual Report on the Advancement of Pharmaceutical Chemistry and Therapeutics for the year 1903.**

THIS useful résumé of the literature of the year, dealing with a number of the drugs in use, chiefly those of recent introduction, has reached us. It is brim-full of information, a certain

proportion of which is of special moment to the ophthalmic surgeon. All that has recently been written on, say, iodipin, may be found summarised in it, and concerning such new or strange drugs and substances as Johimbin, Hetol, Ichthargan, Eumydrine, Thiosinamine, Trigemin, everyone knows that such information as is to be had will be found in "Merck."

---

A. Natanson (Moscow). **The Changes in the Lachrymal Glands which Follow Extirpation of the Sac.** *Klinische Monatsblätter für Augenheilkunde*, June, 1904.

Extirpation of the lachrymal sac usually effects the gradual disappearance of the troublesome epiphora that accompanies the conditions for which this operation is undertaken. This is due, not to the atrophy of the corresponding lachrymal gland, but to the removal of the constant irritation of the gland set up by the disease; the gland returns to its normal function. In some cases, however, the epiphora does not disappear, and for these the excision of the palpebral portion of the gland has been attended with success. This result, it has been suggested, is brought about by an injury during this operation to the ducts of the main portion of the gland which becomes subsequently atrophied; and Schirmer has shown that the disappearance of the secretion follows, whether only the palpebral portion or the whole gland has been removed. It is this effect of division, or rather excision of a piece, of the ducts of the orbital portion of the gland that Natanson has here investigated, and he publishes the results of part of a series of experiments on dogs. He has found so far that, while the changes in the gland were insignificant within four weeks after he excised the ducts, there was marked degeneration of the secreting epithelium with some hyperplasia of the connective tissue six weeks after the experiment.

It may be noted that Seydewitz, of Greifswald, has made similar experiments on the rabbit, and produced an atrophy of the orbital portion of the lachrymal gland after destruction of its ducts.

Thos. Snowball.

---

ALVARADO (Valladolid). **New Contribution to the Study of Nitrate of Silver.** *Recueil d'Ophtalmologie*, August, 1904.

DR. ALVARADO opens his article by quoting in full a translation of the report of a case of cauterisation of the cornea by a very strong solution of nitrate of silver, published by Schalscha, of Berlin, in the *Wochenschrift für Therapie und Hygiene des Auges* of February 14, 1904. The report was shortly as follows:—In the treatment of an ordinary ophthalmia neonatorum a solution of 2 per cent. strength was prescribed, but by an error on the part of the dispenser a 20 per cent. was supplied, and two or three drops were instilled into both eyes of the infant. Fifteen minutes later the skin of the lids was stained black, the lids themselves were so œdematous that they could not be separated by the fingers. A sanguineous liquid exuded from the conjunctiva. By the aid of retractors, which caused free bleeding, the corneæ were exposed and found to present the milky whiteness seen in lime burns. The conjunctiva was covered by a thick membrane with shreds of tissue and pus. The condition got worse during the ensuing twenty-four hours, and then it rapidly improved. Two days after the instillation the corneæ were again examined and were discovered to be intact and lustrous. Symblepharon was anticipated, but on the fourth day the blennorrhœa had disappeared and the eyes were practically normal. Schalscha, in commenting on the case, considers that the treatment of purulent conjunctivitis lasts too long, and that its duration might be safely curtailed by the use of 3 or 4 per cent. solutions instead of the ordinary 2 per cent. That a 20 per cent. solution produced no permanent lesion he attributes to the fact that the epithelial covering of the conjunctiva and cornea was intact. To those who fear such strong solutions he confidently recommends protargol. Dr. Alvarado is a firm believer in the more concentrated solutions, and thinks there is nothing to fear from their use, and this although Roth has cited a case of cauterisation of the cornea by a 10 per cent. solution. He has made trial of picric acid, but has given it up as being certainly no better than silver nitrate; in cases of chronic conjunctivitis (not gonorrhœal) he has found collargol to have some value, but it is not very reliable.

J. GRAY CLEGG.

TEILLAIS (Nantes). **Ocular Traumatic Hysteria.** *Archives d'Ophtalmologie*, August, 1904.

THERE is a certain type of hysterical amblyopia, that, namely, in which the loss of vision, more or less complete, follows an injury to the eye itself or to its adnexa, which is eminently calculated to give much trouble to the examining surgeon in respect of questions of compensation for injury. In practically all cases of traumatic hysteria it will be found that the injury has given rise to a train of symptoms conveniently summed up in the expression nervous shock, symptoms partly physical, partly psychical. It is important to bear in mind that the original injury which lights up such a train of symptoms is not necessarily, nor indeed is it frequently, at all severe in itself. Teillais recounts two such cases which have recently come under his notice, and which, in view of the circumstances indicated above, are worthy of some attention.

The first was a case of complete amaurosis lasting a year, from which eventually the patient completely recovered. A printer, aged 32, consulted Teillais five years ago regarding certain eye symptoms which began in the left eye and then very suddenly attacked the right also. The patient attributed the loss of sight to an accident in which a piece of furniture fell, striking his left eye and lacerating the skin of the forehead and left upper eyelid. There was present a small white scar corroborating his description of the injury; it was not, he said, until a week after the accident that he first observed any defect of the left eye; with an effort he could see to read even with it alone, and as the right eye showed no sign he continued to work just as usual. Three weeks after the accident, however, he was obliged to cease work in consequence of the progressive failure of the right eye. His mental balance became decidedly less satisfactory; a great dread of blindness seized upon him and deprived him of rest and sleep; he believed that he fainted more than once. Patient was a tall, thin man, who had suffered from intestinal worms, and who, since becoming a printer, had repeatedly had symptoms of lead colic; he was somewhat given to intoxication. The left eye had only perception of light; with the right he made out with much difficulty somewhat large print. Ophthalmoscopic examination was negative, the pupils reacted to light, there was no muscular lesion; the field of vision was very considerably

reduced, and the only colours correctly named were red and blue. Common sensibility of the lids and forehead was quite normal, except that there was one spot pressure on which gave rise to extreme reaction. As in a large number of hysterical cases, there was anæsthesia of the conjunctiva and margin of the cornea; on the left side this was complete, and on the right a minor degree of the same condition was present. The state of vision became worse, so that with the left eye there was mere perception of light, and with the right he could just make out the outlines of objects, but there was no change in the fundus whatever. The area of anæsthesia became larger, however, extending to the arm. In this condition he remained for a whole year, when he came back to say that quite suddenly and without any warning or reason that he could suggest, vision had returned to the right eye; he was then found to possess full vision, but without perception of colours, and his field was decidedly restricted. Shortly thereafter vision began to return to the left eye, and the cutaneous anæsthesia to vanish. The case thus was one undoubtedly of hystero-traumatism, for one cannot suppose that poisoning, either by lead or by alcohol, was the cause of these symptoms which he displayed, but it is more than probable that the alcohol at all events contributed to the liability to hysteria.

The second case was one of bilateral amaurosis, complete for two and a half months, but eventually resulting in recovery. It was that of a boy of 15, who on the evening previous to his first appearance had received a blow from an elastic ball, from which ecchymosis and swelling of the right upper lid had resulted. Except for this and for considerable injection of the conjunctival vessels there was no sign of injury; the cornea was perfectly normal, the pupil regular and active; save for the hanging of the upper lid there was no indication whatever of damage to the muscles of the eye, and vision was quite perfect; the ophthalmoscope showed no alteration. At the end of a fortnight the only trace of mischief was a slight degree of ecchymosis, and the patient had gone back to school. Two months later his parents informed Teillais that he had suddenly become blind. Three weeks' delay followed on account of paralysis of motion and evidently also of sensation in the right leg, but from this he recovered with the same suddenness, and he was then able to come in from the country and attend. On examination there was found absolutely

no trace of the injury, and although the eyes looked quite well and were able to converge accurately, vision was reduced to bare perception of light and of hand movements. The ophthalmoscope showed nothing; the conjunctiva on both sides and the margin of the right cornea were anæsthetic. Motion had returned to the right leg, but over a large area of thigh, leg, and dorsum of the foot there was complete anæsthesia. Electrical treatment produced no change, no benefit whatever, but one morning about three months after he announced that he could see. He was then examined and found to have still some restriction of the field, but good vision, and sensation in arm, face, and leg appeared to have completely returned. On enquiry it appeared that when much younger the boy had suffered from typhoid fever, which is regarded by some authorities as being particularly liable to be followed by hysteria; in this case Teillais regards it as the chief factor, but insufficient of itself to produce the condition until the occurrence of the injury.

To show how a very slight surgical procedure may lead to a somewhat similar train of symptoms, Teillais relates the case of a patient who consulted him on account of lachrymation; it was necessary to incise the canaliculus, and during this process the patient fainted. On account of his extreme distress the question of probing was postponed for some time, and when at last he submitted the moment the little operation was begun he fell into a species of fit. The facial muscles became contracted, the mouth deviated to the right, and the right forearm adopted an attitude of semi-flexion. This spastic condition lasted an hour, and next day there was complete anæsthesia of the right side of face and neck, arm and forearm; there was also blepharospasm of the right side which lasted a fortnight. It appeared then that for a long time the patient had had a numb feeling in the right arm. His case illustrates a point often noted in cases of this kind, namely, that where there is anæsthesia it is apt to be located in those areas of skin overlying the region of the muscles paralysed.

Dupuy-Dutemps, who published two cases of prolonged or permanent complete amaurosis after trivial accidents, considers that while in partial amblyopia the diagnosis between a genuine hysterical blindness on the one hand and a simulated condition on the other may be attended with considerable difficulty, in the case of complete blindness the position is a little different.

For it is practically impossible for a person who is actually able to see to avoid with complete success at all times all movement of convergence; it is practically automatic. If, therefore, the patient, when put at his ease as much as possible and examined judiciously on repeated occasions, still can never be observed to make any motion of convergence when taken off his guard and suddenly invited to fix an object, there is at least a strong presumption that he is truly, though perhaps only hysterically, amblyopic and is not simulating. If any degree, however slight, of permanent divergence is also present the diagnosis may almost be said to be certain. One must admit no doubt that the persistent absence of any evidence of convergence is a strong point, but it does not quite exclude all errors.

The line of demarcation between unconscious, functional, "hysterical" amblyopia on the one hand, and conscious simulation of blindness, complete or partial, on the other, is not at all times very easy to draw. As a contribution to the literature of a condition of interest, more frequent no doubt in France than among our people, Teillais' article is worthy of attention. W. G. S.

---

SEARLES (Oshkosh, Wisconsin). **Atropin v. Eserine in Glaucoma.** *American Journal of Ophthalmology,* May and August, 1904.

Two papers have recently appeared from the pen of Dr. Searles, in which he strongly maintains the very heterodox opinion that in glaucoma, atropin, so far from being injurious, is in a high degree beneficial, in fact "there is no other drug at the present time to be compared with it." He relates the cases of three patients who mercifully recovered under treatment with 2 per cent. atropin and 4 per cent. cocain, with jaborandi and opium internally and "Dr. Gross's tablet." He approves highly of warmth applied to the eye by means of hot water; this has a great effect in relieving the pain which is so intense when the affection is acute.

The reviewer confesses to a total inability to understand the grounds, even as stated by the author, on which he asserts the beneficial action of atropin, especially as he relates two cases in the second article in which he himself admits that a

violent attack of glaucoma was induced or precipitated by the use of that drug. His physiology does not agree with that of the schools, for he states that the pupil dilates during sleep. His therapeutics are equally extraordinary. "Atropin is now perfectly safe in the practice of the writer to use in the presence of any form of glaucoma, providing the [ciliary] muscle is held in abeyance. His client would not have been attacked if she had strictly obeyed instructions to avoid all use of the eyes for near work." The patient to whom this refers was a lady, 64 years of age, who consulted Dr. Searles on account of rapidly progressing presbyopia and "a possible tendency towards glaucoma." She was treated with atropin for ten days, and was then "attacked with acute inflammatory glaucoma in both eyes." Another quotation further illustrates Dr. Searles' peculiar views on therapeutics. Speaking of total loss of sight from glaucoma, he says: "Jaborandi was given regularly once a day, from 15 to 40 drops at bedtime. One eye only was allowed to be treated locally. At the end all increase of tension had disappeared from both eyes! and the pupils responded to light, showing that the oculo-motor center had been reached."

So far as one can discover in this remarkable couple of papers, efforts at accommodation are the real cause of the onset of glaucoma in eyes which are at the time under the influence of strong solutions of atropin, but just how this takes place is not explained. "That glaucoma occurs co-incidentally with the exhibition of atropin is most true, but it is due to an entirely different cause than [*sic*] the one recognised, namely, obstruction by the way of thickening of the iris base. The glaucoma charged to the use of atropin can always be quickly cured by the further exhibition of atropin. Atropin is to the eye what splints are to the fracture, and we should no more make use of the one than the other [*sic*] while under such control. The use of atropin under this precaution as an inflexible rule is perfectly safe and wonderful in its results. Atropin now comes to the front in a new rôle. It is to become our chief weapon against glaucoma in meeting its inflammatory side. Atropin removes for the time being one side of the iritic [*sic*] angle, in maximum dilatation as completely as the best possible iridectomy."

It would be a serious matter indeed were it probable that the writings of an author so ungrammatical in his style, so

ignorant of facts, and so little amenable to instruction, even from the melancholy consequences of his conduct to his patients, should produce any influence upon uninformed minds, but so disastrous a result, we trust, may not take place. Is it to be wondered at that Christian Scientists, Zionists and the like flourish so in a country whose legitimate practitioners can commit themselves as Dr. Searles has here done?

W. G. S.

---

# Bibliography.

---

## Anatomy and Physiology.

Bach and Meyer. Experimental inquiries regarding the pupil. *v. Graefe's Archiv.*, 59, 2.
Beevor and Collier. Cerebral localization of vision. *Brain.*, Summer.
Bouchart. Stereoscopic vision. *Rec. d'Oph.*, September.
Cirincione, Origin of the vitreous. *Arch. f. Augen.*, August.
Levinsohn. Physiology of the pupil reflex. *v. Graefe's Archiv.*, 59, 2.

## Congenital Abnormalities.

Abelsdorf. Heterophthalmos in albino animals. *v. Graefe's Archiv.*, 59, 2.
Chance. Various malformations of the eye. *American Medicine*, October 1.
Graef. Anophthalmos. *N. Y. Med. Jl.*, September 3.
Hirsch. Persistent vessel in vitreous. *Arch. f. Augen.*, September.

## Hygiene.

Greeff. The hygiene of schools in regard to the eyes. *Klin. Jahrbuch.*, 13, 1

## Pathology and Bacteriology.

## Instruments and Apparatus.

Griffin. Modification of Bowman's suction curette. *Ophthalmoscope*, October.
Veith. Electrical apparatus for the eye. *Woch. f. Ther. und Hyg. des Auges.*, 2.
Vorstadter. An eye heater. *Woch. f. Ther. und Hyg. des Auges.*, October 6.
Wolffberg. Apparatus for testing vision. *Woch. f. Ther. und Hyg. des Auges.*, October 6.
Wolffberg. Shield for the eye. *Woch. f. Ther. und Hyg. des Auges.*, October 6.

## Therapeutics.

Sano. Subconjunctival therapeutics. *Arch. f. Augen.*, August.

## Operations.

Bocchi. Opeo treatment after extraction. *Ann. di Ott.*, xxxiii., 10.
Bourgeois. Infection of wound in extract of cataract. *L'Oph. provin.*, October, and *La Clin. Oph.*, October 10.
Bull. Operations in presence of an infected conjunctiva. *N. Y. Med. Record*, Sept. 24
Enslin and Kuwahara. Suppurative meningitis after enucleation. *Arch. f. Augen.*, Sept.
Hirschberg. Suction operation. *Ophthalmoscope*, October.
Holth. Tattooing the cornea in colours. *La Clin. Ocul.*, September.
Valois. Indications for enucleation. *L'Oph. provin.*, October.

## Traumatisms.

Barrett. Injuries of the eye, *Intercol. Med. Jl. of Australasia*, August.
Evans. Eye symptoms of traumatic hysteria. *Birmingham Med. Rev.*, September.
Ryan. Injuries of the eye, *Intercol. Med. Jl. of Australasia*, August.

### Tumours.

Alt. Glioma of the retina and the question of rosettes. *Amer. Jl. of Oph.*, September.
Baquis. Angiosarcoma of choroid. *Ann. di Ott.*, xxxiii., 10, 11.
Clegg. Epibulbar melanotic sarcoma. *Lancet*, September 10.
Del Monte. Melanotic sarcoma of the cornea. *Ann. di Ott.*, xxxiii., 10.
Hanke. Neuroma of the eyelids. *v. Graefe's Archiv.*, 59, 2.
Wood. Lipoma of external rectus. *Oph. Record*, September.

### Sympathetic Ophthalmia.

### Glaucoma.

Carbone. Influence of iridectomy in glaucoma. *La Clin. Ocul.*, September.
Galezowski. Pathogeoesis of glaucoma. *Le prog. Méd.*, September 24.
Pes. Changes in retina in glaucoma absolutum. *Archiv. f. Augen.*, September.
White. Glaucoma. *Oph. Record*, September.

### Amblyopia and Visual Defects.

Buller and Wood. Poisoning by wood alcohol. *Jl. Amer. Med. Assoc.*, 15 and 16.
Haitz. Stereoscopic examination of the centre of the visual field. *Klin. Mon. f. Augen.*, October.
Harman. Fields of vision in tobacco amblyopia. *Lancet*, September 17.
Kroner. "Fatigue-fields" of vision. *Zeitsch. f. Klin. Med.*, 54, 3.
Valobra. Hysterical hemianopsia. *Rev. Critic. di Clin. Med.*, September.

### Refraction and Optical Questions.

Eaton. Presbyopia. *Oph. Record*, September.
Heine Excessive myopia. *Cent. f. Augen.*, September.
Gibbons. Accommodation after extraction. *Jl. of Eye, Ear, and Throat Dis.*, July.
Orlandini. Influence of the crystalline lens in astigmatism. *Ann. di Ott.*, xxxiii., 10.

## Regional Affections.

### Eyelids.

Hanke. Neuroma of eyelids. *v. Graefe's Archiv.*, 59, 2.

### Lachrymal Apparatus.

Fleischer. Histology of lachrymal glands. *Anatom. Hefte.*, 78.
Fortunati. Tuberculosis of lachrymal gland, *Ann. di Ott.*, xxxiii., 10.
Hymmen. Extirpation of the sac. *Med. Corr.-Blatt, des Wurt. Landesvereins*, October 1.
Suker. Use of lachrymal probes. *Amer. Jl. of Oph.*, September.
Villard. Abortive treatment of abscess of the sac. *La Clin. Oph.*, October 10.

### Conjunctiva.

de Falco. Pathogenesis of certain diseases of the conjunctiva. *Ann. di Ott.*, xxxiii., 10.
Nydegger. Tracboma and some diseases resembling it. *N. Y. Med. Jl.*, September 17.
—— Tracboma in immigrants. *American Medicine*, October 1.
Peters. Some forms of secondary conjunctivitis. *Die Oph. Klinik*, October 25.

### Cornea and Sclerotic.

Del Monte. Melanotic sarcoma of the cornea. *Ann. di Ott.*, xxxiii., 10.
Lotin. Gummatous swelling of the sclera. *Arch. f. Augen.*, August.
Martin. Keratomycosis aspergillina. *Archiv. f. Augen.*, August.
Puccioni. Treatment of keratoconus. *Ann. di Ott.*, xxxiii., 10.
Villard. Hypopyon ulcer after ozoena. *La Clin. Oph.*, October 10.
zur Nedden. Infective marginal ulcer of the cornea. *v. Graefe's Archiv.*, 59, 2.

### Iris and Ciliary Body.

Goldzieher. Iridocyclitis in congenital heart disease. *Cent. f. Augen.*, September.
Meller. Hyaline degeneration of pupillary margin. *v. Graefe's Archiv.*, 59, 2.
Schieck. Pigmented cysts of posterior surface of iris. *Klin. Mon. f. Augen.*, October.

### Lens.

## Choroid and Vitreous.

Baquis. Angisarcoma of choroid. *Ann. di Ott.*, xxxiii., 10, 11.
Fleischer. Tumour of the choroid. *Klin. Mon. f. Augen.*, October.
Rumschewitsch. "Drusen" of lamina vitrea, *Klin. Mon. f. Augen.*, October.

## Retina.

Alt. Glioma of the retina and the question of rosettes. *Amer. Jl. of Oph.*, September.
Bardelli. Subretinal cysticercus successively operated upon. *Ann. di Ott.*, xxxiii., 10.
Guibert. Detachment of the retina. *La Clin. Oph.*, 17.
Leri. Retina in tabetic amaurosis. *Nouv. Icon. de la Saltpêtrière*, August.
Scheer. Hæmorrhage into the retina from compression of the thorax, *v. Graefe's Archiv.* 59, 2.

## Optic Nerve.

Schnaudigel. Cavernous degeneration of the optic nerve. *v. Graefe's Archiv.*, 59, 2.

## Muscles (and Strabismus).

Bourdeaux. Muscular insufficiency. *La Clin. Oph.*, 17.

## Orbit.

## Relations with Medicine.

Galezowski. Syphilis of the eye. *Rev. d'Oph.*, September.
Gendron. Ocular complications of influenza. *L'Oph. provin.*, October.
Loeser. Ocular symptoms due to aneurism. *Arch. f. Augen.*, August.
Volhard. Eye symptoms in paralysis of the arm. *Deutsch. Med. Woch.*, 37.

## Miscellaneous.

Albertotti. Historical documents relating to the work of Benvenuto. *Indian Med. Gaz.*, October.
Albertotti. Spectacles in a picture painted in the year 1352. *Ann. di Ott.*, xxxiii., 10.
Aubineau. Legal aspects of injuries to the eye. *L'Oph. provin.*, October.
Berger. Disturbance of vision following use of an aniline hair dye. *Arch. f. Augen.*, Sept.
Birch-Hirschfeld. Action of Roentgen and radium rays upon the eye. *v. Graefe's Archiv.*, 59, 2.
Friedmann. Hysteria or dissimulation. *Oph. Record*, September.
Gonni. Jubilee of Ophthalmology. *Rev. Méd. de la Suisse Romande*, September 20.
Hinshelwood. Congenital word-blindness. *Ophthalmoscope*, October.
Meige. Ophthalmic migraine. *Rev. Neurol.*, September 30.
Stephenson. Congenital word-blindness. *Lancet*, September 17.

# FURTHER INVESTIGATIONS ON ACCOMMODATION.*

By Karl Grossmann, M.D., F.R.C.S. (Edin.),
*Ophthalmic Surgeon, Stanley Hospital, Liverpool.*

Since I gave a report of my investigations on accommodation at the annual meeting of the British Medical Association[1] in July, 1903, I have subjected the result to a careful re-examination, and can uphold my statements in every particular.

These investigations were at the time prompted by the examination of a case of total congenital aniridia duplex with good range of accommodation, and gave as their result the following changes during accommodation (1) The diameter of the lens equator becomes smaller; (2) the antero-posterior (axial) diameter of the lens increases; (3) the anterior pole of the lens moves forward (towards the cornea), the posterior pole of the lens moves backward; (4) by means of retinoscopy, a ring-shaped shadow zone becomes visible between the centre and the equator of the lens, as an expression of the refractive changes which occur—of the formation of a lenticonus accommodativus; (5) it was proved by means of the Sanson-Purkinje reflex images that the posterior surface of the lens also forms a lenticonus; (6) the lens *in toto* moves upwards and inwards.

Besides this was noticed, though only at the height of eserinization, the appearance of the ciliary processes, and

*A paper read at the Annual meeting of the British Medical Association in Oxford. We are indebted to the courtesy of the *British Medical Journal* for the use of the illustrations.

their centripetal movement (towards the axis of the eye); and the tremor of the lens, first observed by Hess, was also seen very distinctly.

The result of these different points, of which the first six have now for the first time been demonstrated as established facts and not as hypotheses, have not been refuted by anyone, and have been universally accepted with the one exception of Dr. Tscherning. Now, after the traction theory has been deprived of one support after another, Dr. Tscherning tries to replace missing facts by a highly imaginative hypothesis. At the end of this paper I shall disprove also this latest hypothesis.

The observation No. 6, that the lens moved upwards and inwards during accommodation, seemed as unexpected as difficult to explain. The movement took place and could be observed during voluntary effort of accommodation, although not to so high a degree as after eserine. As I had already remarked at Swansea, this movement more than counterbalanced the slight sinking of the lens due to gravitation which took place at the height of eserinization. Although it is so much greater, it cannot be proved entoptically, because in a normal eye it is accompanied by a simultaneous and analogous movement of the contracting pupil, which is also dislocated upwards and inwards.

Meanwhile it has been observed again this year in another case of congenital absence of iris. Mr. Story, of Dublin, to whom the patient went, informed me by letter that for the present he had not been able to conduct a more minute examination, but could observe "an indefinite decrease of the equatorial diameter of the lens, with apparent dislocation upwards and inwards. The lenses stand normally in this patient a little upwards and inwards, and this dislocation is more accentuated by

eserine." We may without doubt look forward to a detailed account of the case from Mr. Story.

The observations made on my case of aniridia gave me an explanation for the following case, which is so interesting that I give it somewhat fully here:

Mr. B., aged 37, came to me in October, 1903. Besides some other symptoms of the nature of conjunctivitis, I noticed in both eyes a pronounced and symmetrical displacement of the pupils upwards and inwards. Their function was otherwise quite normal (Figs. 1, 2 and 3). Both corneæ are of normal size and shape, and are about 11mm. in diameter. In medium light the pupils have a diameter of 3mm., and are situated as indicated by the accompanying diagrams (Figs. 4 and 5) where the sizes of both pupil and iris in the two principal directions are given in millimetres. The centre of the pupil does not coincide with the centre of the iris, and the line passing both these centres I will call here the principal axis. In the right eye the principal axis (marked ------- in Figs. 4 and 5) was inclined with its upper end 40 degrees towards the nose, in the left 10 degrees. In the direction of these axes both pupils show a slight tendency to be oval.

Vision for distance was: S R $= {}^{30}/_{30}$ with cyl. $-1{\cdot}75$, deviation from the vertical of the upper end of the cylinder axis 40 degrees (towards the nose); S L $= {}^{30}/_{30}$ with $-3{\cdot}0$ sph. $\supset$ cyl. $-1{\cdot}75$, deviation from the vertical of the upper end of the cylinder axis 10 degrees (towards the nose).

When examined for short-range vision, it was found that very small print, lines, dots, etc., can be made out much better when the axis of the right glass is turned more horizontally by 17 degrees, and for the left eye by 10 degrees, as shown in Fig. 6.

Glasses for near work were therefore prescribed in which the axes of the cylinders were inclined, as above indicated, differently from their position in his distance glasses.

From the first there was hardly any risk of a mistake, the patient being very precise and clear in all his answers; and a series of re-examinations excluded the possibility of error. The explanation for this unusual condition

suggested itself to me from observation No. 6 on the irisless eye; it is due to a dislocation of the lens inwards and upwards during accommodation. I was in the fortunate position of being able to examine most carefully the corneæ of the patient, with the help of the Oxford Helmholtz ophthalmometer, which Professor Gotch had kindly lent me for my investigations. No trace of corneal astigmatism was present; both corneæ, however, had almost exactly in their respective centres an apex of a curvature a very little stronger than the rest. It followed that both lenses were suspended slightly eccentrically, which accounted for the astigmatism. During any accommodative effort an additional movement of the lenses upwards and inwards took place. For the right eye the inward component of this movement was larger than for the left eye, quite in harmony with the eccentricity of both pupils, as already existing for the state of rest; and thereby it was effected that, with the corneal apex remaining in its place, the axis of the astigmatism—at its upper end—moved towards the nose, and more so in the right than in the left eye.

This observation has since then been corroborated by two further cases of a similar nature, though not quite so pronounced as the one given here *in extenso*. In my opinion it furnishes the explanation of a somewhat rare and obscure condition, namely, a temporary alteration, improvement, or even disappearance, during accommodation of the astigmatism found to exist for distance, or *vice versâ*. Such an occurrence has hitherto often been explained by a purely hypothetical partial contraction of the ciliary muscle; it now finds a simple explanation by a lateral displacement of the lens during accommodation. I have been fortunate in being able to observe this

accommodative movement of the lens, and also to demonstrate it here in Oxford last year, but although I have no doubt that its existence is the rule, it will be possible only under exceptional conditions to prove its occurrence.

This change of axis of the astigmatism having once been ascertained, it was found much easier for the patient himself to recognise it whenever the pupils had been slightly dilated by a quantity of cocain small enough not to interfere with the accommodation. This suggested another question, namely, whether the improvement of vision was brought about by the narrowing of the pupil alone, or, by its concomitant dislocation upwards and inwards, also assisted by its shape, which simultaneously became more oval.

For the solution of this question, it appeared desirable to examine the mechanism of accommodation in an eye with a pupil of a pronounced oval shape. For various reasons, investigations on ruminants could not be undertaken, and I therefore decided to select an eye in which the oval type of pupil had developed to its extreme, namely, to a slit-shaped pupil, of which we have the most pronounced and familiar example in the eye of the cat.

I did not approach the subject with very sanguine hopes, remembering what an observer generally so reliable as Hess, partly alone, partly in conjunction with Heine, had stated with regard to the range accommodation in various animals, of which dog, cat and rabbit are specially mentioned. In all of them the range of accommodation was stated to be extremely limited, so that only the eye of the monkey could be compared with the human eye in this respect. My investigations on the eye of the cat, however, have shown that Hess's assertions are open to correction.

It became necessary to examine the facts concerning the accommodation of the eye of the cat both anatomically and physiologically. The difficulty—hitherto unsurmountable—

of determining anatomically the shape of the lens during accommodation, consists in the circumstance that up to now no unexceptionable method of fixing the shape of the lens was known. I tried osmic acid in different concentrations, pure and with chromic acid, and Fleming's solutions, but found that in a series of experiments with the unopened eyeball action took place neither evenly nor deeply enough, while in the opened eyeball the additional grave objection existed of the disturbed intraocular pressure. Moreover, I have sometimes observed very marked distortions through swelling and other uneven action. In fact these methods proved quite unreliable.

Should it become possible to fix the lens in its shape and place, it would then be desirable to introduce some staining method in order to differentiate the lens clearly from its surroundings. An observation which I had made some time previously came to my help and led to a method of examination which combines both fixation and staining of the lens in a thoroughly satisfactory manner.

When examining bullocks' eyes for other purposes I had noticed that on freezing the eyes the lens had become chalky white, while the surrounding parts, aqueous and vitreous, were semi-transparent and of a dark colour. It was thus possible to fix the lens in its position without any disturbance and to make topographical transverse sections in which the lens stood out in a sharply-defined hard white outline from the dark grey of the surroundings. Different formulæ were employed for freezing mixtures, but as it was advisable to freeze the eyes as rapidly as possible, I resorted, on the suggestion of Dr. Mann, of Oxford, to solidified $CO_2$. Liquid $CO_2$ is commercially obtainable; by vaporising part of it a snow of solid $CO_2$ can be obtained which is used to cool alcohol. Temperatures so low can in this way be produced that a small object, such as an eyeball, when dropped into the alcohol, freezes almost instantly.

The frozen eye is then taken out and sawn in the direction marked beforehand. The technique is a little troublesome and requires some practice, but exquisite pictures may be obtained. On the other hand, it is not easy, and requires a good deal of patience, to obtain good photographs of the frozen sections; the surfaces are rather apt to melt during the slow process of focussing such small objects with an ordinary camera.

Nevertheless I have been able to take a series of photographs which, even in the less sharp specimens, give some idea of the surprising clearness of the originals.

For the purpose of examination the atropinised or eserinised eyes of freshly killed animals were frozen and opened with a fine saw through the vertical meridian, marked previously with a coloured thread. The following differences were found:—

In the atropine lens the anterior surface is more strongly curved than the posterior surface, and is of a regular, spherical shape; the posterior surface, always curved in a smaller degree, showed in many cases a pronounced central flattening. (Figs. 7, 8, 9, 14.)

In the eserine lens the anterior surface is scarcely different from that of the atropine lens; the curvature appears the same in the centre and the surrounding zone, only towards the periphery there is often a stronger curvature present. (Figs. 11, 12, 13.) The posterior lens surface, however, shows a change in form as marked as it was unexpected; a pronounced lenticonus has appeared, the apex of which is situated above the axis of lens centre, at a height which corresponds approximately to half the distance between the centre of the lens and its upper margin (Figs. 11, 12). The equatorial diameter of the eserine lens is scarcely any smaller than that of the atropine lens.

The figures (Figs. 8, 9, 10, 11, 12, 14) represent the "vertical" meridians, in which we find the extremes of the differences between the eserine and atropine lens. The meridians are not absolutely vertical, but correspond to the direction of the slit of the contracted pupils; their upper ends are slightly divergent (inclined towards the temple). Intermediate figures are found in the intermediate meridians.

It is clear that we have here to deal with a phenomenon which, though new, is indisputable, and on it—as upon a solid foundation—we can build further conclusions. The principal one of these is that there must exist in the eye of the cat not only a very considerable amount of accommodation, but also that this accommodation must be accompanied by a high degree of astigmatism. In other words, the effect of the accommodation will consist in an increase of the refraction, principally in the direction of the vertical meridian.

And if we consider how such an astigmatism could be corrected we find that two ways would be open to us to effect

this—namely, either by a concave cylinder lens placed with its axis in the vertical meridian, or else by stenopœic slit put in the same direction. *In the eye of the cat we find the second alternative employed: the pupil contracts to a slit, the direction of which corresponds with the principal axis of the astigmatism, and corrects it more or less completely.*

If this explanation of the above-stated anatomical differences between the atropine lens and the eserine lens is correct, it should be possible to demonstrate physiologically that during accommodation a fair amount of astigmatism occurs with its principal axis in the direction of the slit of the pupil. From the very beginning I had strong misgivings with regard to the already mentioned assertion of Hess—expressed as recently as February, 1904, in the *Clinica Oculistica*—that the amount of accommodation in the eye of the cat is very small. Apart from the seemingly excellent vision of the cat for near objects, the large extent of the field of binocular vision[2] spoke in favour of a highly developed vision for near objects.

In order to clear up this point, iridectomy was performed on the cat's eye, which is a more complicated operation than in man, since, in consequence of the larger size of the blood-vessels of the iris, the anterior chamber at once fills with blood. It takes several months before its absorption admits of a reliable examination of the refraction. This latter requires some practice before one becomes accustomed to determine the refraction for a definite part of the fundus. It will be found that the portion which approximates in position to our yellow spot has, in the atropinised eye, a fairly high degree of hypermetropia. After eserinisation, however, I found in the iridectomised eye myopia, and for the vertical meridian a well-marked myopic astigmatism. The amount of accommodation measured was, on an average, equal to 9 dioptrics, with the addition of 5 dioptrics more for the vertical meridian. Allowing for the original hypermetropia, this would correspond to a near point of about 5in., and would, with the help of the slit-shaped pupil, admit of sharp focussing for the distance of the fore-paws—analogous to our short-range working distance; it would be called into use when a cat was playing with a mouse, etc.

After these results it appeared desirable to see whether the accommodative dislocation of the lens observed in the human eye was also accompanied by a noticeable, if small,

excentricity of the posterior lenticonus. The Helmholtz ophthalmometer and my patient with aniridia were both happily accessible. The reflex images were produced by a naked arc light doubled by prisms. The posterior lens pole, to all appearance situated exactly in the centre of the posterior lens surface, was unsuited for the measurement of the reflex images, owing to the small white opacity (polar cataract), but careful measurements carried out in the circumpolar zone showed that after eserine actually a slightly stronger curve existed upwards and inwards from the posterior pole than downwards and outwards. The difference in the size of the reflex images was, however, very small, and would probably not have been detected with a less accurate instrument.

The establishment of these facts is of great importance, as they indicate a decided analogy between the mechanism of accommodation in man and in certain other animals, not necessarily anthropoids. It will therefore be admissible, though of course with due reserve, to apply certain conclusions obtained from investigations on animals to the human eye.

The question then arose how to explain the eccentricity of the lenticonus, and why when I observed the lenticonus first in the aniridic human eye I was wrong in assuming it to be correctly centred, and its apex coinciding with the posterior pole of the lens. I think the answer will be found most easily by studying the surrounding anatomical conditions prevailing in eyes with oval or slit-shaped pupils. We find that the ciliary body forms a ring which, in the eye of the cat, is narrower at the upper than at the lower end of the vertical meridian. Between the two extremes there are gradual transitions which are symmetrical in the nasal and temporal half. The size of

the ciliary muscle, and therewith the possible amount of its contraction, is greater at the lower than at the upper end of the vertical meridian, while the temporal and nasal halves are symmetrically arranged, and hold each other in equilibrium. It results from this anatomical condition that by the contraction of the ciliary muscle during accommodation, a greater amount of relaxation of the zonula occurs in the lower than in the upper part, and therefore the conditions are given for an accommodative deformation of the lens with a pronounced asymmetry in the vertical meridian.

In animals with a more horizontal pupil we find an analogous asymmetry of the ciliary body in the direction of the horizontal diameter. In man the pupil and ciliary body are approximately circular, but still we find that the ciliary body is broader outwards and downwards than inwards and upwards, which holds good also for the iris. The amount of asymmetry is here very small, and not generally noticed except in such extreme cases as that described above.

Evidently a certain correlation exists between the size of the ciliary muscle and the sphincter of the iris. While the iris in the atropinized eye of the cat forms a narrow ring of equal width all round, the narrow slit of the eserinized pupil leaves the iris at its upper end much narrower than at its lower end. An analogous condition, though more horizontally situated, occurs in the eye of the ruminants.

These observations help to demonstrate the preponderating importance of one function of the iris, namely, that of acting as a correcting diaphragm for the purpose of eliminating as much as possible the effects of aberration. We notice an inter-dependence between the muscular

apparatus of accommodation and that of its diaphragm. The ciliary body not being equal all round, the lens moves in one direction during accommodation, while the diaphragm contracts in such a manner as not only to shift the position of the narrowed pupil with the optical axis, but also to adapt its very shape to the optical requirements.

That this function of correcting aberration is more important than that of regulating the entrance of light, is generally shown by physiological and pathological observations. Physiologically the pupil of youth is wide. The lens is bounded by approximately spherical surfaces. These surfaces become more parabolic or hyperbolic during accommodation, and the pupil narrows accordingly with it. In age the lens fibres become sclerosed, the cortical layers lose their jelly-like softness. The elasticity of the capsule gradually loses its power of altering the shape of the lens, and the latter becomes more permanently hyperboloid, with a marked anterior and posterior lenticonus, such as we find transitorily in the youthful lens during accommodation. Likewise, we find that the pupil of age contracts gradually more and more until we often see in old age the pinhole pupil, which is, however, easily dilatable with mydriatics.

With regard to the regulation of light, on the other hand, the amount of light that reaches the retina is, *ceteris paribus*, owing to the decreasing transparency of the optic media, smaller in age than in youth. Nevertheless in age the pupil is narrower, producing sharper images.

It will be interesting to see whether the eye of the cat shows an analogous slit-shaped contraction with advancing age. Observations in this direction do not exist so far as I know, and it will, of course, take some years before I can report any observations on this point.

Pathologically, too, we see that the light-regulating function of the iris may long have been destroyed—for example, in locomotor ataxy—while the synergetic contraction of the pupil still accompanies accommodation.

In conclusion, I wish to touch on some points in the reply to my previous paper which Dr. Tscherning has just published.[3] The publications of Dr. Besio,[4] made under the auspices of Dr. Tscherning, were, as he rightly assumes, unknown to me. I should otherwise have commented at the time on some of the conclusions set forth there, to which I can only refer very briefly here, namely:

The flattening of the periphery of the lens during accommodation is in itself of no importance, it is simply an accessory to the increased curvature of the centre, which is the essential point for the accommodation. The dead and excised lens does not admit of any unmodified conclusions as to the behaviour of the lens in the living eye. Both Crzellitzer's and Tscherning's experiments have been disproved since by other experiments of Hess.[5]

The quantities calculated (not measured) by Dr. Besio for the increase of the diameter of the lens are far too small (fractions of a millimetre) to admit of any conclusions as to the alteration of the equatorial diameter of the lens. My own direct measurements gave an apparent difference of $1\frac{1}{3}$mm., but I already mentioned at the time that this amount is too small, because it represents only the distance of the optical images of the anterior and posterior lens pole. After reduction the real distance is found to be nearer 3mm. than 2mm. The transverse section of the lens focussed for distance as represented by Tscherning is wrong, even if the curves of the anterior and posterior surfaces are sketched only diagrammatically. The lens is

not rounded at the equator but sharp-edged. Tscherning says: "It is asserted that the lens trembles owing to relaxation of the zonula as assumed by Helmholtz, but no one has, to my knowledge, seen that the reflex image of the anterior lens surface ever trembles," but I here state again and distinctly that in my case of aniridia the lens moved *in toto;* the tremor was observed in the sharp equatorial margin, in the posterior and in the anterior polar cataract. In order to obviate the possible objection that after all the tremor may be confined to the intra-capsular mass of the lens, I have to record an observation made since in a case of iridectomy performed some time ago for a corneal opacity. Within the area of the artificial coloboma a small deposit of uveal pigment was visible on the anterior surface of the anterior lens capsule. During eserinization this pigment mark trembled with the lens. Thereby proof is given that also Tscherning's latest hypothesis—according to which during accommodation the anterior lens capsule becomes taut and fixed through increased tension of the zonula, while simultaneously the posterior capsule becomes relaxed—is wrong and contradicts the actual facts.

With regard to the possibility of a greater amount of relaxation of the posterior as compared with the anterior lens capsule, time does not allow me to enter into particulars here; I am therefore glad to be able to refer in this respect to a paper just published in the *Journal of Physiology*, vol. xxxi., p. 1, by Professor T. P. Anderson Stuart, who comes to conclusions diametrically opposed to those of Tscherning.

REFERENCES.

[1] *British Medical Journal*, September 26th, 1903; *Ophthalmic Review*, January, 1904.

[2] *V. Graefe's Arch.*, xxiii., 3, p. 127.

[3] *La Clinica Oculistica*, November, 1903; *Ophthalmic Review*, April, 1904.

[4] *Journ. de Physiologie et de Pathologie Générale*, June and September, 1901.

[5] *La Clinica Oculistica*, February, 1904.

FIG. 1.—Showing position of pupils (upwards and inwards).

FIG. 2.—Right eye.

FIG. 3.—Left eye.

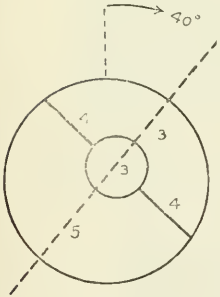


FIG. 4.—Diagram of iris and pupil of right eye.

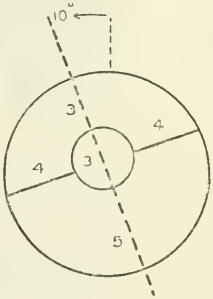


FIG. 5.—Diagram of iris and pupil of left eye.

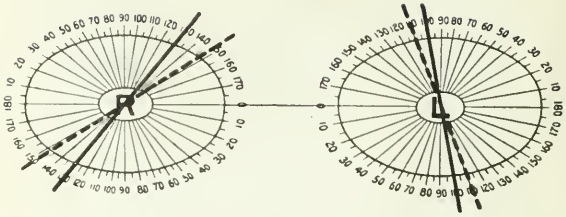


FIG. 6.

——— Axis of cylinder during rest (distance).
--------- ,, ,, ,, accommodation (reading, etc.).



FIG. 7.—Eye frozen in mucilage in a wooden box; vertical section; cornea upwards; atropine lens; anterior (upper) surface much more strongly curved than posterior surface, the latter flattened in centre.

FIG. 8.—Atropine lens; cornea upwards; vertical section.

FIG. 9.—Atropine lens; vertical section; cornea inwards, touching that of the other half.

FIG. 10.—Atropine lens; vertical section; cornea outwards. The left (upper) half a little distorted in the photograph by being nearest and slanting towards the camera.

FIG. 11.—Eserine lens; vertical section; corneæ outwards; anterior lens surface not noticeably different from atropine lens; posterior surface shows marked lenticonus with eccentric apex turned upwards.

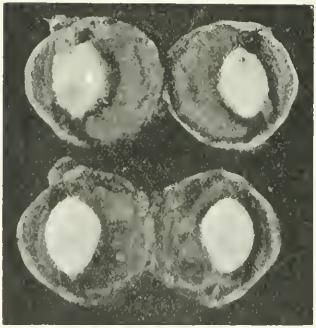

FIG. 12.—Above section through atropine lens and below section through eserine lens of same cat; corneæ outwards; vertical sections; the left upper half damaged; right half clear; lenticonus and eccentricity in lower lenses well marked.

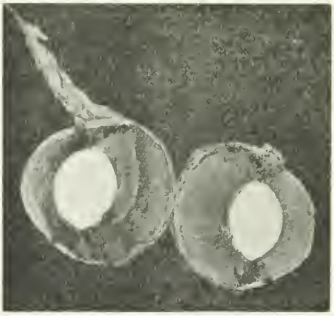

FIG. 13.—Eserine lens; horizontal section; corneæ outwards; lenticonus in that particular meridian barely recognisable.

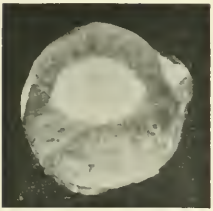

Fig. 14.—Atropine lens; vertical section; cornea upwards; not sharply focussed, but flattening of posterior lens surface well recognisable.

---

## STEREOSCOPIC TREATMENT OF SQUINT.

By A. Freeland Fergus, Glasgow.

The subject of binocular vision cannot but be of great interest to the physiologist; moreover, it is of great practical importance to the ophthalmic surgeon. On the intuitive development of binocular vision in the infant depends the prevention of squint and the retention of useful vision in both eyes. The careful training of this function is very important in dealing with many cases of concomitant squint, and is also of value in the treatment of paresis of ocular muscles and of the various forms of heterophoria.

In his excellent monograph which appeared about eighteen months ago Mr. Worth laid great stress on functional training. Prior to his time authors have called attention to the value of stereoscopic exercises, and stereoscopes have been employed by ophthalmic surgeons for a period of at least twenty or thirty years. The best and fullest description, however, of the functional treatment of

squint with which I am acquainted is undoubtedly that of Mr. Worth.

Concomitant convergent squint may begin in very early childhood, but on the other hand may not be present till after the lapse of some years. In the first group of cases the amblyopia of the squinting eye is usually very profound, but as a rule when the squint has not developed till a later period of life then, generally speaking, both eyes have fair vision. A young child, say of about two years of age, begins to squint. At first the affection may be alternating, *i.e.*, at one time one eye is obviously the squinting eye, at another the other; but before long the affection is manifested only by one eye. Under such circumstances the little patient may be taken to a medical man who to its guardians' satisfaction, if not to his own, associates the condition with teething or with some gastric disturbance, and assures the relatives that the child will outgrow it. At this early period such a course of action as a rule seals the doom of the eye, and in after life when the patient comes to have the deformity removed it will be found that the eye which was thus neglected when the cortical functions were being established is hopelessly and considerably amblyopic. No training of any kind in such circumstances is of much avail, and the most that can be done is to attempt to remove by operation an unsightly deformity. Had proper steps been taken when the strabismus first appeared then the patient almost certainly would have had two useful eyes instead of one. It is beyond the limit of the present communication to discuss the treatment recommended by Mr. Worth; suffice it to say that it chiefly consists in educating the form sense in both eyes. We have tried it now for a period of fully a year, and when intelligently carried out by the patient's

guardians we have found it to be entirely satisfactory. In the treatment of such cases at so early a period of life the use of stereoscopes or of Mr. Worth's ingenious amblyoscope can in the nature of things play little or no part. It is to be remarked, however, that certain of Mr. Worth's figures, particularly the cage and the bird, are quite available for children of about three or four years of age. Mr. Worth also finds that his figures consisting of circles can be used with advantage. When these are viewed through his instrument the observer has the idea that he is looking either at the outside or inside of a tube, and Mr. Worth's experience is that even a very young child with binocular vision can indicate which of the two he is looking at.

Coming now to speak of persons at a more advanced period of life, one curious fact is to be noted, viz., that it is possible for a person to have two excellent eyes and, although there be no squint, still have not binocular vision in so far as he has no perception of the third dimension. This probably explains an interesting observation which I have occasionally made. Suppose we are testing a patient's form sense by means of Snellen's distance types. Let us further suppose that we are testing the right eye and that a blinder is in front of the left. The patient may be able to see all the letters with the right eye. It sometimes happens that on removing the covering and placing it in front of the eye which has just been examined the patient forthwith states that he is unable to see any of the letters and that his right eye is now quite blind. He is once more able to read the letters on his attention being called to the fact that he can do so with his left eye. This will happen notwithstanding that the left eye is open and that its vision is excellent as measured by Snellen's scale.

In other words, some persons seem to have the power of being conscious of impressions coming from one eye. They appear to have the power, where both eyes are good, of disassociating the vision due to one from that of the other. The truth is that cases of this kind undoubtedly occur in which there is no squint; probably they are to be explained by the absence or diminution of the power or fusion and by a parallel anatomical position of rest.

Patients who are improved by stereoscopic exercises are, firstly, all young children who are capable of recognising such test objects as are supplied with the amblyoscope. Careful exercises with the proper use of a bandage, so far as my experience goes, invariably put such cases right. Should the squint be alternating then each eye must be alternately excluded from the act of vision for a space of about three or four hours daily. If, however, it has already been established in one eye, then the eye which is habitually used for fixation should be carefully bandaged for several hours each day. Secondly, the stereoscope is of great use where the squint has not appeared till a rather later age. I am not sure that here it gives such brilliant results as it does in early childhood, but still it has a marked effect. It certainly is of great use as an adjunct to operative interference, although for that purpose I prefer the plastograms to be described presently. Lastly, the stereoscopic exercises are of immense value in treating the various forms of lateral heterophoria. It seems to me that it is much to be desired that we had a stereoscope for vertical heterophorias.

The stereoscopes which I have hitherto employed have been the convenient forms of Doyne and Landolt, and more recently I have made use of Mr. Worth's amblyoscope. They are all serviceable implements and have this feature

in common that the two half images, one belonging to each eye, are combined to form one whole. Most of the exercises with these instruments show only a flat surface, which is a very different thing from stereoscopic vision. Some of Mr. Worth's figures, however, as already indicated, afford admirable examples of stereoscopic vision.

The ordinary picture stereoscope is not available, because when the patient looks through it the examiner has no guarantee that the patient has the sense of perspective and distance. I have found those coloured pictures called plastograms to be superior to anything else as a test of binocular vision and as a training in stereoscopic exercises. The plastogram is constructed as follows:—Two nearly similar pictures are printed on the same piece of paper with only a slight space intervening between them. One of the pictures is of a reddish and the other of a greenish colour. A piece of red glass is put in front of one eye and a piece of green glass in front of the other. If a person have binocular vision the two pictures are at once combined into one and a stereoscopic effect is obtained. If a person who has binocular vision, and has got on trial this stereoscopic impression, then moves his head or his body from side to side, he will at once find that the objects in the foreground of the picture also move from side to side relatively to those in the background. If the movement be present the patient has binocular vision, if it be absent he has not. An ordinary stereoscope shows somewhat similar movements, but the advantage of the colour stereoscope is that it enables us at once to ascertain which eye the patient habitually employs for purposes of fixation. I have for several months back in my practice used this simple and cheap instrument in cases both of divergent squint and of convergent squint and of heterophoria, and that with the

most satisfactory results. The patients are directed to use the apparatus for a period of twenty minutes at least twice daily.

In viewing any of the plastograms which are hitherto seen, stereoscopic effect is only obtained when the red glass is held in front of the right eye and the green before the left. The views may be obtained from Mr. Bauermeister, Gordon Street, Glasgow, and are also on sale in many "fancy goods" shops.

---

## PRESENT VIEWS REGARDING THE ORIGIN OF THE VITREOUS.

By Prof. Cirincione, Genoa.

Part II.

I shall begin with the views of Prof. Kölliker, as expressed in his paper, which was published after it was read at the Heidelberg Congress—(A. Kölliker, "Die Entwicklung und Bedeutung des Glaskörpers," *Zeit. f. Zoologie*, 1903). Kölliker begins by stating that there have been put forward the following views as to the origin of the vitreous: The mesoderm, a transudation from the vessels, the retina and lens, which four, he considers, are all that exist in the literature.* He says that Tornatola expects the credit of having put forward the view of the ectodermic origin of the vitreous. Referring to his work, Kölliker makes rather a severe criticism when he says that "if his study of the comparative anatomy of the vitreous in invertebrates should result in his (Tornatola's) opinion as to its origin from the retina, it must be noted that his facts directed to prove his theory are not so certain as they ought to be." Kölliker therefore considers that Rabl, Fischer and Addario are the three authorities on the ectodermic theory of origin.

Rabl (1889), in his masterly work on the lens, states incidentally that the vitreous is developed from the intermediate

* Others would have the vitreous derived from the white blood corpuscles (Bertacchini), the choroidal flexus (Real y Beyro), etc.

area of the retina between the visual and blind part. In a second article (*Anatom. Anzeig.*, No. 25, 1903) he refers to the works of Tornatola and Addario as corroborating his argument. Fischel (1900) also holds that the vitreous is formed by prolongations arising from the retina between its visual and blind part, while Addario believes that the vitreous is developed from the posterior part of the orbiculus ciliaris, that is, between the ora serrata and the beginning of the zonule of Zinn. In a second heading Kölliker discusses the theory of the lenticular origin of the vitreous, which he rejects, and summing up v. Lenhosseck's writings, he concludes on p. 6:—"After this review of the latest works on the development of the vitreous I wish now to emphasise the fact that I recognise only two (possible) ways of origin for the vitreous; they are, the one ectodermic provided by retina, and the other mesodermic."

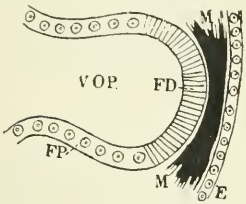


Fig. 12.

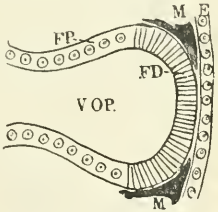


Fig, 13.

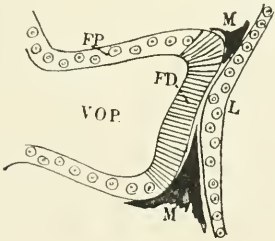


Fig. 14.

A. *The Retinal Origin.* Kölliker admits at once of the presence of a primitive or retinal vitreous and of a vitreous derived from the ciliary body. The former, he states, exists only in the early stages of development of the eye, as it disappears and is no more discernible in the later stages. After demonstrating his researches on his point he passes on to the consideration of

B. *The Mesodermic Origin.* Here Kölliker states: "I am firmly convinced that in all the individuals (?) in whom blood-vessels are found in the embryonic vitreous a greater or less part of it has been derived from the mesoderm, but I do not agree with Cirincione in thinking that the whole of the vitreous is of mesodermic origin." Then referring to his own investigations, he concludes by stating that "if now one refers to the views of the most recent authorities on the origin of the vitreous one finds that Tornatola, Addario, and Rabl deny altogether any participation of the mesoderm in the formation of the vitreous; in opposition to their views, Van Pée maintains that the greater part of the vitreous is of mesodermic origin, and Cirincione, who in all his fine work on this subject holds that the ectoderm does not participate in the vitreous formation but only the mesoderm."

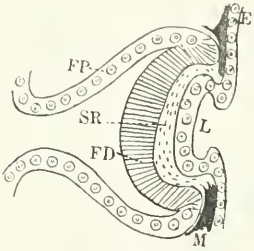


Fig. 15.

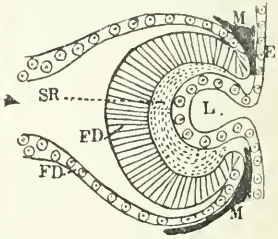


Fig. 16.

Those who look back after having read Kölliker's work must realise that we are to-day still far from seeing the embryology of the eye relieved of such contradictions, yet I believe that I have in a small way assisted in their elimination by strengthening some important facts and noting some causes of error—

facts and opinions that are slowly being confirmed and utilised by embryologists:—

1. The existence in mammals of a mesodermic layer between the primary optic vesicle and the ectoderm, which *entirely disappears before* the lens comes to lie in the secondary optic

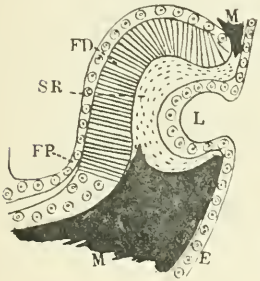


Fig. 17.

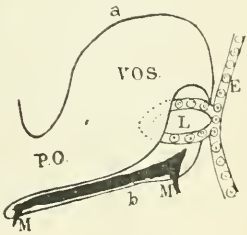


Fig. 18

vesicle, is a fact I noted in 1894. Kölliker, who then denied this, now fully confirms it by stating "that in mammals before the lens is formed there exists without doubt between the primary optic vesicle and the ectoderm a thin layer of mesoderm, and the only question is whether it is pushed inwards during the development and growth of the lens. I at first

Fig. 19.




Fig. 20.

thought with Arnold, Lieberkühn, etc., that this did take place, but lately I have become doubtful, as in sections cut in series of the primary vesicle I have not been able to find any cellular elements lying here." This fully upholds what I maintained in the first chapter of my work on the peri-lenticular capsule, which I concluded with the following definitely recognised observations:—"First, that in mammals and also in man there is a layer of mesoderm between the primary optic vesicle and the ectoderm (Fig. 12); secondly, that this mesoderm disappears (Fig. 13), so that the primary optic vesicle comes in contact with the ectoderm." This is exactly what Kölliker now holds. The importance of these facts is realised when one remembers that from this interposing mesodermic layer, as I have called it, the mammalian vitreous was supposed to be developed (Ciaccio, Kölliker, Lieberkühn), while in birds and other vertebrates lower down in the scale the vitreous was thought to be derived by transudation from the vessels (Kessler). Having, however, shown that the interposing mesodermic layer disappears in mammals before the lens is developed, one is able now to establish a harmony between the different classes of vertebrates as there is no further necessity to hold different views as to the development of the vitreous in one class and in another.

2. *The Peri-lenticular Mesodermic Covering of Mammals.* Some have denied its presence, but Van Pée, in his work referred to by Kölliker, states on page 363, when referring to the development of mesoderm in the secondary optic vesicle, that already in the embryo of a sheep 11mm. in size "there is present round the lens a true mesodermic envelope rich in blood-vessels." As proof of this I reproduce here micro-photographs from a human embryo of 14mm. In them the lens is completely enveloped by a mesodermic covering such as I described. (I have preferred for more clearness to reproduce, instead of my own preparations, micro-photographs of preparations belonging to Prof. His).*

3. *Contents of the Incipient Secondary Vesicle.* This substance, which I described later as a retinal or lenticular product, I first described in 1894 as filling up the space between the retina and lens (Figs. 15, 16, 17 S R),

* Some have stated that from this mesodermic envelope I consider the capsule of the lens and even the cornea (!!) are developed—views which I never held.

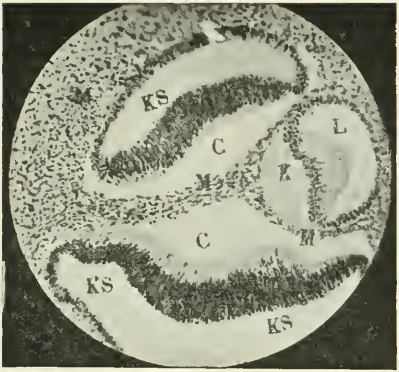


Fig. 21.

Fig. 22.

and I held that it was not vitreous, but only a provisional substance, which was later to be replaced by the vitreous proper. Kölliker, who does not appear to have seen that part of my work, came to the same conclusion, and called this filling up substance *primary or retinal vitreous.* "In my experience," he states, "it follows that the visual part of the retina slowly loses the power of forming vitreous fibres, beginning first at the fundus of the vesicle, *i.e.*, at the entrance of the optic nerve and of the hyaloid artery. Here the retinal prolongations disappear and give place to a fine limiting membrane which sometimes clings and remains attached to the vitreous where this is detached. In time the vitreous fibrillæ disappear throughout the whole extent of the visual retina, so that in the vitreous of 4cm. one sees a clear appearance of radiating fibres only in that extreme limit of the retina which belongs to the ciliary region, *i.e.*, the pars ciliaris retinæ." Hence the vitreous derived from the visual part of the retina disappears, to give place to the permanent vitreous, which, Kölliker holds, comes from the retina ciliaris and from the mesoderm. I was not wrong therefore when I denied that the vitreous was derived from the visual part of the retina.

Kölliker lays great stress on the non-visual or ciliary portion of the retina as being the ectodermic origin of the vitreous, a view first supported by Rabl and then by Fischer and Addario. I must remark that little light has been thrown on this question, and while up to a short time ago the theory of the origin of the vitreous from the visual retina received much support, it is now abandoned and the ectodermic origin is attributed to the non-visual or ciliary part of the retina. We must not, however, forget the views of v. Lenhosseck, an eminent embryologist, who is not at all convinced of either the one or the other theory of the epidermic origin of the vitreous, which, he holds, is derived from the embryonic lens. It must be noted that a full study of the various classes of vertebrates has never been made by any of the supporters of these various theories, in fact Fischer only makes a passing reference to this question in his work on the regeneration of the lens, while Rabl, in his second work, only devotes a few pages to it, which are illustrated by figures from Tornatola and Addario, with whose preparations neither I nor others can agree. Rabl himself says that "in the embryo of *sauropidi* I have been unable to convince myself of the retinal origin of the vitreous, though I am aware

that Tornatola, even in the fowl, pictures the vitreous fibrillæ springing up from the retina, and I have no reason for doubting him, though my results have not yet shown me such fibres or their relationship."

From all this it is easy to see that all those authorities who favour an ectodermic origin are in search of a safe ground, seeing that those fibres which arise from the non-visual portion of the retina constitute in their great extent the zonule of Zinn, and those few which make their way into the vitreous, and they are *not present in all vertebrates*, serve most probably to support the anterior portion of the vitreous. Some authorities, and chiefly the latest, among whom are Kölliker and Van Pée, admit an ectodermic and a mesodermic vitreous, with this difference, that the ectodermic (ciliary) origin takes the first place, while the mesoderm plays a secondary part. One would then be dealing with a *vitreous of mixed origin*. Virchow with truth asked "how an ectodermic formation came to be in such intimate union with a mesodermic structure."

In conclusion to what has been said, it follows that the theory of the origin of the vitreous from the visual retina has now been given up, and that the supporters of its ectodermic origin have supported the lens and orbiculus ciliaris at the same time that others have considered the mesoderm and ciliary part of the retina as the seat of origin of the vitreous, and it is therefore to be hoped that further research will render the mesodermic origin which I support, in consequence of my researches throughout the whole vertebrate class, acceptable to all.

---

## REVIEW.

Sir William Gowers. **Lectures on Diseases of the Nervous System.** Second series. London: J. and A. Churchill, 1904.

In the practice of his specialty the ophthalmologist has many interests in common with the neurologist. Much of the subject matter contained in these ten republished lectures will interest the student of ophthalmology quite as much as his neurological confrère. The book opens with the Bowman Lecture of 1895 on subjective visual sensations. This lecture has been re-arranged and re-written throughout, even although the author has found it unnecessary to modify his chief conclusions in the light of more recent experience. The subject is considered under the

headings of (1) visual sensations in migraine, (2) visual sensations in epilepsy, and (3) miscellaneous sensations. Sir William Gowers adheres to the opinion which he expressed in 1885, that the observations of Ferrier as to higher visual centres for the perception of visual impressions situated in the region of the angular gyri are correct, and he founds his description of the facts of subjective sensations on this assumption. The second lecture, the Bradshaw Lecture of 1896, is devoted to sensations of sound, and in it, among other things, the difference between visual and auditory sensations is discussed. Abiotrophy is a term introduced by the author to denote failure of vitality, a degeneration or decay in consequence of a defect of vital endurance. Optic abiotrophy or abiotic wasting of the optic nerves receives special consideration in this lecture. The progressive loss of sight which is met with in some cases of tobacco amblyopia after the tobacco has been withdrawn, without any increase in the signs of neuritis, shows "that the toxic agent was only the exciting cause of a process really due to an inherent defect of vitality." Another lecture published as a contribution to the Festschrift in honour of the seventieth birthday of Professor von Leyden, deals with myasthenia and ophthalmoplegia, and in it the peculiar characteristics of the ocular muscular defects in myasthenia gravis are described. Myopathy, metallic poisons, syphilitic diseases of the nervous system, inevitable failure (a study of syphilitic arterial disease), syringal hæmorrhage into the spinal cord, and the use of drugs, are the titles of other lectures, which contain a wealth of original observation from the pen of a master of lucid expression.

---

## OPHTHALMOLOGICAL SOCIETY OF THE UNITED KINGDOM.

The President, Mr. John Tweedy, in the Chair.

*Meeting held October 20th, 1904.*

### Card Specimens.

*An Ophthalmoscope.*—Mr. N. Bishop Harman.

One of the chief merits of this instrument appeared to be its extreme portability without a case; at the same time it is practically free from risk of breakage. The handle, which folds back upon the mirrors, at

the same time completely encloses and shields them. By means of fifteen actual glass lenses in the instrument, and their combinations, a range of seventy consecutive dioptres could be made to pass the sight hole, the range for concave lenses being from 39D. to 1D., while that for convex lenses was from 30D. to 1D., there being the usual blank as well. The mechanism utilized is that known as the "Jumping Indicator," such as is used in numerous speed indicators for ships, cycles, stop watches, etc.

*Pigmy Needles for Suture of the Conjunctival Flap after Cataract Extraction.*—Mr. E. E. Maddox.

These needles are very much shorter than the smallest eye needle hitherto used, and have also a much stronger curve, so that immediately after the point has penetrated, it is brought well clear of the surrounding tissues. One of the advantages found from the use of sutures is that in the resulting post-operative astigmatism the curvature is much more regular than in cases healed by second intention.

*Small Electric Eye Warmers with Delicate Electric Connections.*—Mr. E. E. Maddox.

These eye warmers were lighter in make than those shown before the Society last session, for the continuous application of dry heat in cases of ciliary neuralgia or cyclitis after extraction, and in addition were provided with delicate cord connections much on the same principle as the snap clasp of a necklace, which do away with the ordinary heavy and cumbersome connections previously used and thus enable the nurse or other attendant readily to attach or detach the warmer, and this without disturbing the dressings.

*Notes on the Blood-vessels of the Optic Disc in some of the Lower Animals.*—Mr. E. Nettleship.

The paper consisted for the most part of a description of the blood-vessels of the optic disc and distal part of the optic nerve in a few mammalian animals and one or two marsupials, and was intended to supplement, so far as it goes, the well-known descriptions given by Mr. Lindsay Johnson of the ophthalmoscopic appearances of the fundus in mammals. Axial or nearly axial sections of the disc and a varying portion of the nerve of one eye were shown, and transverse sections of the disc extending to a little beyond the posterior surface of the sclerotic were made of the other eye. Comparing the results obtained microscopically with the appearances described by Mr. Lindsay Johnson ophthalmoscopically, the writer found them to agree so closely

that "indeed in certain cases one might suppose that his ophthalmoscopic and my microscopic examination of a given species were made on the very same individual, highly improbable as this would be."

Twenty-one species were examined ranging from the lemurs downwards, excepting the rodents. The true monkeys were found to have retinal blood systems similar to that of man.

The general conclusions were—(*a*) in those of the lower mammals whose retina was well supplied with blood, the cilio-retinal vessels took a much greater share in the supply than in man, in many species these vessels alone furnished all the blood circulating in the retina.

(*b*) The course taken by the cilio-retinal vessels accounted for the ophthalmoscopic appearances suggestive of glaucomatous cupping observed in certain species.

(*c*) Nothing, however, really resembling glaucomatous cupping was present in any of the species examined. Various forms and degrees of physiological cupping were found, but the disc as a whole was found to be either flat, or more frequently raised a little above the level of the retina as in man. The disc never lay below the level of the retina.

(*d*) In cases where the retina was well vascularized, and this entirely by large and numerous cilio-retinal vessels, a rudimentary arteria centralis could always be found in the optic nerve near the eye lying in a central fibrous tract. In many specimens this central tract entered the nerve so close to the eye as to suggest that the central artery it contained was merely an aberrant cilio-retinal vessel from the sclera or choroid. (Lemur, camel, and otter.)

(*e*) Large vessels seen ophthalmoscopically emerging from the centre of the disc were not always found microscopically behind the lamina cribrosa. In these cases apparently, a small axial vessel becomes enlarged by tributary branches at the lamina cribrosa.

(*f*) In those cases in which the retinal vessels are quite small (as in the zebra, bear, and sloth) they appear to be derived much more from the vessels of the choroid or sclerotic than from the rudimentary central system of the nerve.

(*g*) In the zebra and hog-deer, large spaces, apparently venous but possibly lymphatic, were found in parts of the periphery of the optic nerve. In the canal the central vein of the optic nerve was found to be disproportionately larger than its companion artery, and in this case the larger retinal vessels actually projected into the vitreous in the form of flattened tubes.

(*h*) A point of interest in *post-mortem* specimens was the flattening and apparent narrowing of the cilio-retinal vessels where they curved round the edge of the disc, but it was considered doubtful whether this

flattening indicated any diminution in the quantity of blood passing during life with normal vascular pressure.

(*i*) The colour of the disc ophthalmoscopically was found by Mr. Lindsay Johnson to vary greatly in the different species. Some of the differences were thought to be due to contrast with the tapetum, which varied in colour and brilliancy. But variations in the quantity and distribution of the pigment in the lamina cribrosa and the choroidal sclera immediately round the disc must also influence the colour of it. In the genet, civet cat, and Syrian bear, the pigmentation of the lamina cribrosa—when it contained pigment—was most intense at the point where the central canal joined. When much pigment was present in the lamina cribrosa it frequently passed along the sheaths of the retinal arteries on to the disc but not beyond it to the retina. No pigmented veins were found. A minute microscopical description of the various species examined constituted the bulk of the paper, accompanied in many cases with coloured drawings and an outline drawing of the respective discs ophthalmoscopically taken from Mr. Lindsay Johnson's monograph.

*On the Bacteriology of the Conjunctiva.*—Mr. W. B. Inglis Pollock.

This paper described the result of the bacteriological researches carried out on a large number of cases of conjunctivitis attending the Glasgow Eye Infirmary. Most of the cases examined were in the acute or subacute stages. For statistical purposes the cases were divided into Acute Muco-purulent Conjunctivitis (including the acute contagious conjunctivitis of Weeks); Subacute Conjunctivitis of Morax; Purulent Conjunctivitis; Ophthalmia Neonatorum; and Membranous (or pseudo-membranous) Conjunctivitis. Several cover-glass preparations of each case were examined and in three-quarters of the cases culture tubes were inoculated.

*The Bacillus of Weeks* was the organism most frequently met with in cases of muco-purulent conjunctivitis, being present in 108 out of 145 cases under this heading (75 per cent.).

*The Diplo-bacillus of Morax* was found in 62 per cent. of cases occurring in adults, and in 38 per cent. of cases in children.

*The Bacillus of Petit* had not been observed.

The *Pneumococcus* was only found in five cases of Conjunctivitis. It was most usually found in cases of ulcer with hypopyon, and in dacryo-cystitis.

The *Gonococcus*. Neisser's diplococcus was found in 15 cases, but eight of these were cases of Ophthalmia neonatorum.

*Ophthalmia Neonatorum.* In ten cases of this affection gonococci were

found eight times, or 80 per cent. One case was complicated with streptococci and one showed pneumococci in the film preparation and in culture.

*Staphylococcus pyogenes aureus* or *albus* was found in the culture tubes of all cases. These are held to have but slight effect in actually causing conjunctivitis.

*Membranous Conjunctivitis.* Only one case of this had been seen, but in a number of Ophthalmia Neonatorum cases and also in acute conjunctivitis cases, small shreds of membrane had been seen, all non-adherent.

*Phlyctenular Ophthalmia.* In eleven cases of the above, colonies of staphylococcus pyogenes aureus, citreus or albus, and the Xerosis bacillus, had been found.

Streptococcus pyogenes was found in three cases, in one case together with Neisser's diplococcus, complicated by the presence of a shallow ulcer of the cornea.

*Xerosis bacillus* had been found in culture tubes from almost all the cases.

The conclusions drawn from these researches were that the bacillus of Weeks, the diplo-bacillus, and the gonococcus never having been found in the normal conjunctiva, were an actual exciting cause of conjunctivitis, whereas the pneumococcus and Klebs-Löffler bacillus, having been found occasionally in the normal conjunctiva, were not always the exciting cause. The streptococcus and staphylococcus, being found as a rule in the normal conjunctival secretion, could not be said to act as an exciting cause alone.

A considerable bibliography was also appended to the paper.

REGINALD E. BICKERTON.

---

## Bibliography.


### Anatomy and Physiology.

Becker. Colour vision in artificial light. *Graife's Archiv*, 59-3.
Cooke. Subjective measurement of pupil. *Amer. Ann. of Oph.*, October.
Harman. Lymph follicles in normal conjunctiva. *Brit. Med. Jl.*, November 12.
Howe. Measurement of rapidity of lateral movements of the eye. *Brit. Med. Jl.*, November 12.
Levinsohn. Lid reflex and pupil reflex. *Graife's Archiv*, 59-3.
Rivers. Acuteness of vision of savage and of civilized peoples. *Brit. Med. Jl.*, November 12.

### Congenital Abnormalities.

Cosmettatos. Atypical coloboma of iris. *Arch. d'Oph.*, November.
Walter. Partial coloboma of choroid in one eye and microphthalmos of the other. *Die Oph. Klinik.*, November 5.
Young. Microcornea without microphthalmos. *Amer. Ann. of Oph.*, October.

### Hygiene.

### Pathology and Bacteriology.

Léri. The optic nerve in tabetic amaurosis. *Nouvelle iconog. de la Salpêtrière* October.

## Instruments and Apparatus.

Griffin. Modified Bowman's syringe. *Brit. Med. Jl.*, November 12.
Hummelsheim. A new form of sterilised drop-bottle. *Klin. Mon. f. Augen.* November.
Joseph. Sharp hook for division of optic nerve. *Archiv. d'Oph.*, November.
Kirkendall. A new lachrymal syringe. *Oph. Rec.*, October.
Weill. Haab's magnet: the best instrument for removal of steel from the eye. *Amer. Ann. of Oph.*, October.

## Therapeutics.

Burnham. Combined treatment in eye diseases. *Brit. Med. Jl.*, November 12.
Cohn. Eusemin. *Wchnschft. f. Ther. und Hyg. des Auges.*, viii., 8.
Darier. Injections of salicylate of soda. *La Clin. Oph.*, November 10.
Koller. Modified method of using cocain. *Brit. Med. Jl.*, November 12.
Peschel. Styptcin in haemorrhagic choroiditis. *Deutsch. Med. Woch.*, 44.

## Operations.

Faith. Excision of Tarsus in Ectropion. *Oph. Rec.*, October.
Hirschberg. Magnet operations. *Brit. Med. Jl.*, November 12.
Lacanssade. Asepsis and antisepsis in ophthalmic surgery. *L'Oph. provin.*, November.
Sattler. Iridodesis. *Klin. Mon. f. Augen.*, November.
Valk. "Tucking" operation on muscles. *Oph. Rec.*, October.

## Traumatisms.

Kramsztyk. Burns of the eye with sulphuric acid. *Arch. d'Oph.*, November.

## Tumours.

Ahlstrom. Subconjunctival lipomatous tumours. *Beiträge z. Augen.*, 61.
Ball. Pseudo-neuro-epithelioma of retina. *Amer. Ann. of Oph.*, October.

## Sympathetic Ophthalmia.

## Glaucoma.

Beltman. Congenital teleangiectasis as a cause of glaucoma. *Graefe's Archiv.*, 59-3.
Berry. Diagnosis and treatment of glaucoma. *Brit. Med. Jl.*, November 12.
Demaret. Osmotic pressure of intraocular fluids in glaucoma. *Arch d'Oph.*, November.
Galezowski. Glaucoma. *La Clin. Ocul.*, October.
White. Glaucoma and primary atrophy. *Oph. Rec.*, October.

## Amblyopia and Visual Defects.

Buller and Wood. Poisoning by wood alcohol. *Jl. Amer. Med. Assoc.*, October 22.
Hinshelwood. Congenital word blindness. *Brit. Med. Jl.*, November 12.
Lange. Traumatic bi-temporal hemianopsia. *Amer. Ann. of Oph.*, October.

## Refraction and Optical Questions.

Clarke. Treatment of myopia. *Brit. Med. Jl.*, November 12.
De Beck. Cycloplegia and patent hypermetropia. *Amer. Ann. of Oph.*, October.
Frost. Operative treatment of high myopia. *Brit. Med. Jl.*, November 12.
Goldberg. Myopia in marksmen. *Amer. Ann. of Oph.*, October.
Grossmann. Astigmatism with varying axes. *Brit. Med. Jl.*, November 12.
Halben. Corrigible doubled monocular refraction. *Klin. Mon. f. Augen.*, November.
Poullain. Direct vision. *Rev. d'Oph.*, October.
Weinhold. Binocular fusion of images, and parallax of fused images. *Graefe's Archiv.*, 59-3

## Regional Affections.

## Eyelids.

Gallenga. Phlegmonous abscess of lids in summer. *La Clin. Ocul.*, October.

## Lachrymal Apparatus.

Speciale-Cirincione. Excision of sac. *La Clin. Ocul.*, October.

## Conjunctiva.

Moissonnier. Conjunctival development of erythema. *La Clin. Oph.*, November 10.
Schleck. Spring catarrh and similar affections. *Graefe's Archiv.*, 59-3.

## Cornea and Sclerotic.

Dentschmann. Localised degenerations of cornea. *Beitr. z. Augen.*, 61.
McGillivray. Corneal temperature and nictitation in corneal therapeutics. *Brit. Med. Jl.*, November 12.
Spicer. Keratitis profunda. *Brit. Med. Jl.*, November 12.
Stanculeano. An unusual condition in interstitial keratitis. *Klin. Mon. f. Augen.*, November.

## Iris and Ciliary Body.

Fejer. Absorption of torn iris tissue. *Centlbltt. f. Augen.*, October.
Moissonnier. Tubercular irido-cyclitis. *L'Oph. provin.*, November.
Braun. Rent of posterior pigment layer of the iris. *Centlbltt. f. Augen.*, October.
Roemheld. Tonic reaction of the "immobile" pupil. *Munch. Med. Woch.*, 46.
Rollet. Gummatous iritis with false hypopyon. *Rec. Gen. d'Oph.*, October.
Sisson. Iridodialysis and reattachment. *Amer. Ann. of Oph.*, October.
Vollert. Mydriasis and paresis of accommodation from datura. *Klin. Mon. f. Augen.*, November

## Lens.

Demaria. Cataract produced by massage of lens. *Graefe's Archiv.*, 59-3.
Dransart. Cataract and blindness in Northern France. *L'Oph. provin.*, November.
Grilli. Cataract in lead poisoning. *Rec. d'Oph.*, October.
McHardy. Artificial maturation of cataract. *Brit. Med. Jl.*, November 12.
Salffner. Naphthalin cataract. *Graefe's Archiv.*, 59-3.

## Choroid and Vitreous.

Pes. Some forms of degeneration of choroid *Graefe's Archiv.*, 59-3.
Peschel. Stypticin in hæmorrhagic choroiditis. *Deutsch. Med. Woch.*, 44.

## Retina.

Ball. Pseudoneuro-epitheliona of retina. *Amer. Ann. of Oph.*, October.
Carpenter. Albuminuric retinitis. *Brit. Med. Jl.*, November 12.
Jennings. Pigment streaks at Macula. *Amer. Ann. of Oph.*, October.
Moon. Unilateral retinitis pigmentosa. *Amer. Ann. of Oph.*, October.
Nagel. Retinal hæmorrhage a sign of diabetes. *Oph. Rec.*, October.

## Optic Nerve.

Franke and Delbanco. Tumours of optic nerve and sheath. *Graefe's Archiv.*, 59-3.
Gunn. Retro-ocular neuritis. *Brit. Med. Jl.*, November 12.
Mann Electro-therapeutic researches in diseases of the optic nerve. *Ztschft. f. Diatet. u. physik. Therapie.*, November.

## Muscles (and Strabismus).

Duane. Primary and secondary deviations in paralysis. *Amer. Ann. of Oph.*, October.
Fernandez. Hysterical nystagmus. *La Clin. Oph.*, November 10.
Hamill and Posey. Associated movements of head and eyes in children. *Amer. Jl. Med. Sci.*, November.
Vollert. Paralysis of superior oblique with cerebral complications. *Munch. Med. Woch.*, 45.

## Orbit and Globe.

Borland. Exophthalmos in new-born child. *Lancet*, November 12.
Bronner. Thrombos of cavernous sinus due to empyema of sphenoidal sinus. *Brit. Med. Jl.*, November 12.
MacCallum and Cornell. Mechanism of exophthalmos. *N. Y. Med. News.*, October 15.
Morrow. Foreign body in orbit: perforation into cranial cavity. *Oph. Rec.*, October.
Wernicke. Tuberculosis of the eye. *St. Petersburger Med. Woch.*, October 22.

## Relations with Medicine.

Franke and Delbanco. Leprosy of the eye. *Graefe's Archiv.*, 59-3.
Ischreyt. Ocular changes in Xeroderma pigmentosum. *St. Petersb. Med. Woch.*, Nov. 5.
Jackson. Relation of ophthalmology to other departments. *Amer. Med.*, November 12.
Jocqs. Cerebral and ocular embolus. *La Clin. Oph.*, November 10.
Leri. Optic nerve in tabetic amaurosis. *Nouvelle iconog. de la Saltpêtrière*, October.
Mayo. Thyroidectomy for exophthalmic goitre. *N. Y. Med. Rec.*, November 5.
Nagel. Retinal hæmorrhage a sign of diabetes. *Oph. Rec.*, October.
Stern. Unilateral exophthalmic goitre. *Wchnschft. f. Ther. und Hyg. des Auges.*, viii., 7.

## Miscellaneous.

Campbell. Blind in Chicago schools. *Oph. Rec.*, October.
de Roux. Ocular troubles of electric origin. *Arch d'Oph.*, November.
Gould. Reception of medical discoveries. *Amer. Ann. of Oph.*, October.
—— Taine's ill-health. *American Medicine*, November 5.
Griffith. Intra-ocular hæmorrhage and systemic diseases. *Brit. Med. Jl.*, November 12.
Grilli. Cataract in lead poisoning. *Rec. d'Oph.*, October.
Hirschberg. Anatomical delineation of the eye by the Arabs. *Centlbltt. f. Augen.*, October.
Moon. Education of blind by Moon's alphabet. *Amer. Ann. of Oph.*, October.
Poulton. Vision of birds. *Brit. Med. Jl.*, November 12.

BINDING LIST MAR 1 1914

RE
1
043
v.23

The Ophthalmic review

Biological
& Medical
Serials

PLEASE DO NOT REMOVE
CARDS OR SLIPS FROM THIS POCKET

UNIVERSITY OF TORONTO LIBRARY